



## Serum and tissue squamous cell carcinoma antigen (SCCA) levels: Laboratory markers of Sino nasal inverted papilloma (IP)

Hany Samir Mostafa<sup>1</sup>, Mohamed Qotb<sup>1</sup>, Olfat Gamil<sup>2</sup>, John Wahba<sup>1</sup>

<sup>1</sup> Department of Otolaryngology, Faculty of Medicine, Fayoum University, Egypt.

<sup>2</sup> Department of Clinical pathology, Faculty of Medicine, Cairo University, Egypt.

Email: [hanyam2002@yahoo.com](mailto:hanyam2002@yahoo.com)

**Abstract: Background:** Inverted papilloma (IP) is rare Sino nasal neoplasm although having low averaged incidence 0.5% to 4% of all primary nasal tumors yet it shows high tendency of recurrence 9–17% and high incidence of malignant transformation as high as 15%. **Objective:** Evaluation of the effectiveness of Serum and tissue squamous cell carcinoma antigen (SCCA) levels as laboratory markers of Sino nasal inverted papilloma. **Methodology:** Blood samples were collected from 30 inverted papilloma patients (Group A) and from 10 patients complaining of bilateral nasal obstruction as a symptom of bilateral inferior turbinate hypertrophy who served as control group (Group B) for the analysis of serum SCCA (1) day before and (3) months after surgery. Tissue samples were collected from both groups during surgery for the analysis of the tissue SCCA, the serum and tissue levels of SCCA in both groups were compared and statically analyzed. **Results:** The mean serum level of SCCA in the control cases (Group B) was (2.2 ng/ml) and was designated as the normal level of serum SCCA of this study. In patients of inverted papillomas (IP) (Group A), the mean serum level of this antigen was (6.23ng/ml) before surgery which was significantly high above normal value but decreased markedly 3 months after surgery to (2.96ng/ml). The tissue level of SCCA in IP patients (Group A) showed a statistically significant high mean value (170.5 ng/mg) compared to its level in normal nasal epithelium of the control subjects (Group B) = (8.9 ng/mg). **Conclusions:** SCCA can be considered a promising laboratory marker for estimation of the prognosis and prediction of recurrence of inverted papilloma (IP). The rise of postoperative serum levels of the antigen should be considered a sign of recurrence and indicates careful endoscopic and radiological monitoring of cases.

[Hany Samir Mostafa, Mohamed Qotb, Olfat Gamil, John Wahba. **Serum and tissue squamous cell carcinoma antigen(SCCA) levels: Laboratory markers of Sino nasal inverted papilloma(IP)**. *J Am Sci* 2021;17(12):11-15].  
ISSN 1545-1003 (print); ISSN 2375-7264 (online). <http://www.jofamericanscience.org>. 2.  
doi: [10.7537/marsjas171221.02](https://doi.org/10.7537/marsjas171221.02).

**Key words:** Inverted papillomas, squamous cell carcinoma antigen

### 1. Introduction

Sino nasal inverted papilloma (IP) is a benign tumor usually arising from the lateral nasal wall (Krouse, 2001) which can be locally aggressive causing resorption of the bony boundaries of the nasal cavity and the sinuses extending into the neighboring facial skeleton, orbit and the anterior cranial fossa (Goyal, 2010). Although considered to be rare with incidence 0.5% to 4% of all primary nasal tumors (Myers et al, 1990). yet the marked unfortunate criteria of inverted papilloma is high recurrence rate ranging from 9–17%, usually within the first two or three postoperative years, but delayed recurrences as late as 30-56 months might be seen Kelly et al., 2010). (Anari and Carrie, 2010) (Xiao-Ting et al., 2013). As well as 15 % incidence of malignant transformation (McCollister et al., 2015). The definite diagnosis of IP can only be made by histopathology. Clinical picture is vague and

nonspecific. Radiodiagnosis, though extremely helpful, is also not conclusive (Eggers et al., 2007, Ondzotto et al., 2005). Although many publications suggested factors such as human papilloma virus infection, smoking, tumor site, stage, extent of surgery and number of previous operations are predictors of recurrence (Kim et al., 2012, Sciarretta et al., 2014, Jardine et al., 2000, Lawson et al, 1983), yet the ongoing clinical and therapeutic difficulties with management of inverted papilloma reflects the absence of widely accepted staging system or investigation that could help prediction of recurrence and since the question whether endoscopic treatment is as curative as open surgery is still prominent long term endoscopic monitoring and frequent follow up dates are crucial, regardless of the surgical technique used to inspect for recurrence or multifocal disease (Adriaensen et al., 2016, Eggers et al., 2007, Kelly et al., 2010, Kamel, 1995).

Many researchers had great efforts to find useful laboratory tools that may serve as tumor markers to help diagnosis and early detection of recurrence of inverted papilloma. Squamous cell carcinoma antigen (SCCA) is cytoplasmic protein found in normal squamous epithelia, and in elevated levels in the serum of patients with squamous cell carcinomas which showed a high mean preoperative serum level in patients having inverted papilloma which decreased significantly after radical surgery suggesting that SCCA can be a useful tumor marker of Sino nasal IP (**Matoušek et al., 2014, Yasumatsu et al., 2005**).

In this study, we evaluate the usefulness of serum and tissue SCCA levels as laboratory markers of Sino nasal IP and the ability to use these markers as predictors of recurrence of these tumors.

## 2. Materials and methods

This study was carried out after approval from the institute ethics and research committee in the Department of Otorhinolaryngology, Fayoum University Hospital over a period of three years. The aim of the procedure was clearly explained, and all patients gave their informed consents.

This study included 40 cases arranged in two groups. Group A included 30 patients (case group) presented to otolaryngology outpatient clinic in Fayoum university hospital with unilateral nasal obstruction secondary to a unilateral nasal mass. They were exposed to full ENT examination with a preoperative diagnostic nasal endoscopy and CT scan of the nose and paranasal sinuses. Tissue biopsies were taken under local anesthesia to confirm diagnosis of sino nasal inverted papilloma and detect the histological subtype of each case. The data collected from endoscopic examination and CT scan was used for the detection of the site of origin and for staging of the tumor according to krouse staging system (**Krouse, 2000**). All cases were managed by endoscopic surgical excision of the mass with a wide safety margin depending on the site of the tumor and its stage. 28 out of the 30 cases were arising from the lateral nasal wall and were managed by endoscopic medial maxillectomy which was extended to involve resection of the frontal or sphenoid sinus in extensive cases (Krouse Stage III). The other 2 cases were arising from the nasal septum and managed by endoscopic excision with a wide safety margin (about 0.5cm all around). Tissue samples were collected for the evaluation of the tissue levels of SCCA in inverted papilloma specimens. Blood samples were collected from the patients of this group for the analysis of serum SCCA (1) day before and (3) months after surgery during the routine follow up. Blood samples were also taken from two cases who showed recurrent

masses during follow up to analyze changes in serum SCCA level at time of detection of recurrence.

The mean follows up period was 19 months based on the date of surgery and the compliance of patients. Every case was scheduled for a routine endoscopic follow up every 3 months after surgery to detect any recurrences.

Group B included 10 patients (control group) complaining of bilateral nasal obstruction as a symptom of bilateral inferior turbinate hypertrophy and they were all managed by bilateral partial inferior turbinectomy. Tissue samples were also collected during turbinectomy operation to compare the levels of SCCA in normal nasal mucosa with its level in inverted papilloma specimens of Group A patients. Blood samples were collected from the patients of this group for the detection of the normal serum values of SCCA. All the cases of Group A and B did not show any symptoms or signs that may be associated with head and neck carcinomas or any other tumors in different body organs that might be associated with elevated serum or tissue levels of SCCA.

Both blood samples and tissue biopsies were used for quantitation of squamous cell carcinoma antigen (SCCA) using ELISA kit provided by Bioassay Technology Laboratory; Shanghai, China (Cat.No : E2108Hu).The kit uses a double-antibody sandwich enzyme-linked immunosorbent assay (ELISA) to detect the level SCCA in samples. Each tissue biopsy was weighted and homogenized in PBS (400ul), the homogenate was centrifuged at 10,000 xg for 10 min and the supernatant was separated to be used for determination of squamous cell carcinoma antigen by ELISA.

The data was collected, coded, and data analysis was performed using Statistical Package of Social Science (SPSS) software version 18 in windows 7. Mean, standard deviation, median, lowest and highest values were used in the descriptive statics of the data. The distribution of the variables was controlled with Kolmogorov Smirnov test. The Mann-Whitney U test was used for quantitative analysis. The P-value  $\leq 0.05$  was considered the cut-off value for significance.

## 3. Results

The mean serum level of SCCA in Group B was (2.2 ng/ml) as it ranged between (1.86 and 2.43 ng/ml) which was considered the normal value of serum SCCA in this study. While the mean serum level of SCCA in Group A was (6.23 ng/ml) before surgery as it ranged between (3.21 and 9.45 ng/ml) which was significantly high above normal value but decreased markedly 3 months after surgery to (2.96 ng/ml) as it ranged between (2.16 and 4.22 ng/ml). The mean percent of change in Group A was (49.8  $\pm$  11.4) % ranging between (62.7 and 27.1 %) being

reduced by about 50% after surgery. There was a statistically significant high mean tissue level of SCCA in Group A (mean value 170.5ng/mg) when compared to its level in Group B (mean value 8ng/mg) with p- value <0.05 among cases. Two cases (6.7%) showed recurrent masses during follow up which were biopsied and proved to be recurrent inverted papilloma. One case was diagnosed 9 months (case 1) and the other 15 months (case 2) after surgery. Both were arising from the lateral nasal wall, belonging to the inverted type and showed Type 3

Krouse staging at surgery they showed a marked rise of serum SCCA levels in the samples obtained at the time of recurrence (8.95 & 8.24 ng/ml) when compared to those obtained after 3 months from surgery (4.22 & 3.14 ng/ml). It was also noticed that the values of preoperative serum SCCA in these 2 cases (9.45& 8.4 ng/ml) were above the levels of the mean value (6.23 ng/ml) of all cases of Group A. The tissue level of SCCA was 192.38 ng/mg in case 1 and 182.09 ng/mg in case 2 which was above the mean value in all cases of Group A (170.5 ng/mg).

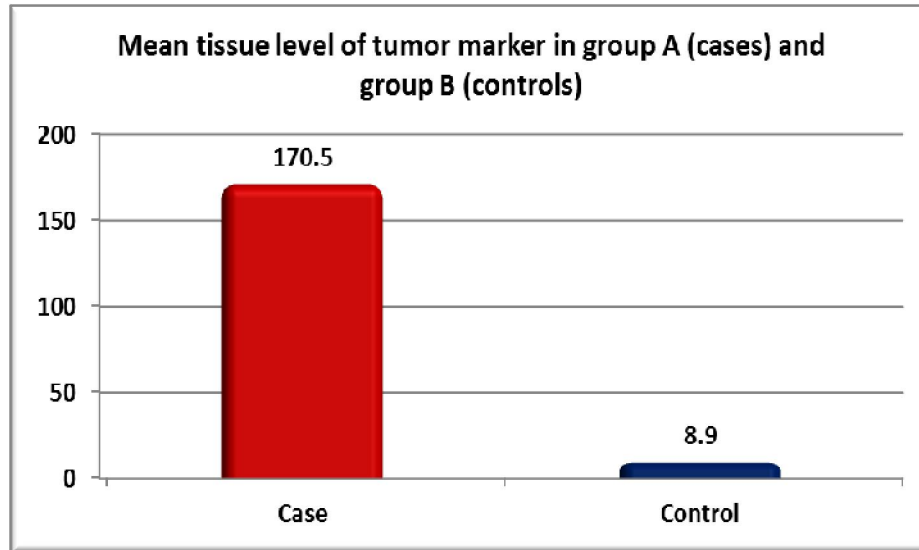


Figure 1: Mean tissue level of SCCA in group A(cases) and group B (controls)

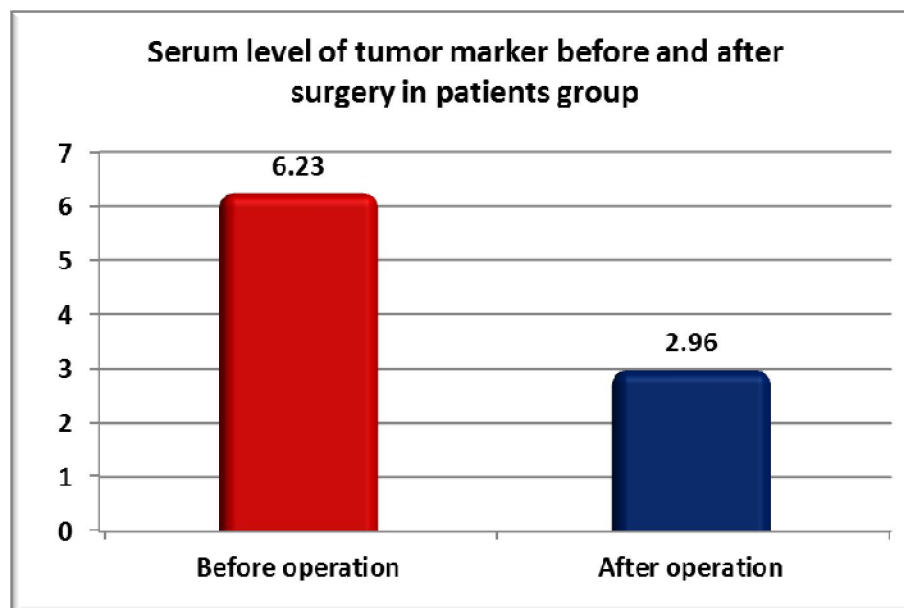


Figure 2: Serum level of SCCA before and after surgery in group A(cases)

Table 1: Percent change in serum level of SCCA before and after surgery in group A(cases).

Serum level (ng/ml)	Mean	SD	Range
Before surgery	6.23	1.9	3.21 - 9.45
After surgery	2.96	0.66	2.16 - 4.22
Percent change	49.8%	11.4%	62.7 - 27.1

Table 2: Descriptive data of the 2 recurrent cases

Variables (n=2)	Case 1	Case 2
Age	53	59
Site of origin	Lateral nasal wall	Lateral nasal wall
Histological subtypes	Inverted type	Inverted type
Krouse staging	Stage 3	Stage 3
Time of recurrence	9 months	15 months

#### 4. Discussion

Although inverted papilloma is a benign condition, it tends to recur usually within the first two or three postoperative years specially for cases exposed to endoscopic removal of the tumor where the risk of recurrence usually depend on the extent of surgery (Anari and Carrie, 2010, Xiao-Ting et al., 2013). Limited studies are available reporting predictor factors of recurrence of such cases (Kim et al., 2012, Sciarretta et al., 2014, Jardine et al., 2000). In a study conducted in 2005 Yasumatsu and associates reported that 25 (89%) out of 28 inverted papilloma patients had elevated serum SCCA levels preoperatively (mean value 3.6 ng/mL) which decreased significantly after surgical resection of the tumor. (Yasumatsu et al., 2005).

Immunofluorescence assay was used to determine serum SCCA levels in 20 sinonasal IP patients before surgery, the day after surgery and every 6 months during 3 years mean follow-up period by Matoušek and associates all their cases showed a high mean preoperative serum level of the antigen (3.885 ug/l) which decreased significantly after radical surgery (0.885 ug/l) compared to a mean of (0–1.5 ug/l) as the normal value of serum SCCA. They suggested that SCCA can be a useful tumor marker of sinonasal IP (Matoušek et al., 2014).

In this study the normal level of serum SCCA was (2.2ng/ml). In patients of inverted papilloma (Group A), the mean serum level of SCCA was (6.23 ng/ml) before surgery which was significantly high above normal value but decreased markedly 3 months after surgery to (2.96 ng/ml). There was a statistically significant high mean value of the preoperative serum levels of SCCA among cases showing advanced krouse staging (type 3) and both were associated with recurrence, the two cases who showed recurrence 9 and 15 months after surgery both were of type 3 Krouse staging and the preoperative serum levels SCCA of these 2 cases were above the mean value of

the 30 inverted papilloma cases (6.23 ng/ml). This might suggest that high preoperative serum SCCA and advanced krouse can be considered as risk factors of recurrence coinciding with the data reported by Yasumatsu and associates and kim and associates in two separate published articles (Yasumatsu et al., 2005, Kim et al, 2012).

There was a marked elevation of the serum SCCA levels of the two recurrent inverted papilloma cases at the time of recurrence (8.95&8.24 ng/mL) coinciding with Van Zijl and associates report of a strong association of high postoperative SCCA serum levels with the risk of recurrence of the inverted papilloma. (van Zijl et al., 2017).

Regarding the tissue level of SCCA, the results showed that there is a statistically significant high mean value of tissue level of the antigen in IP patients (Group A = 170.5 ng/mg) when compared to its level in normal nasal epithelium of the control subjects (Group B = 8.9 ng/mg). Similar findings were reported by Yasumatsu et al as they studied the expression of SCCA in three sinonasal IP cases, three sinonasal SCC cases and cases of normal nasal epithelium using the Western blot analysis and Immunohistochemistry (Yasumatsu et al., 2002).

#### Conclusion

SCCA can be considered a promising laboratory marker for estimation of the prognosis and prediction of recurrence of inverted papilloma (IP). The rise of postoperative serum levels of the antigen should be considered a sign of recurrence and indicates careful endoscopic and radiological monitoring of cases.

#### References

- 1- Krouse J.H. (2001): Endoscopic treatment of inverted papilloma: safety and efficacy. Am. J. Otolaryngol; 22: 87–99.

- 2- Vrabc D.P. (1975): The inverted Schneiderian papilloma: a clinical and pathological study. *Laryngoscope*; 85: 186–220.
- 3- Anari S., Carrie S. (2010): Sinonasal inverted papilloma: narrative review. *J. Laryngol. Otol.*; 124, 705–715.
- 4- Goyal p. (2010): advances in endoscopic resection of sinonasal neoplasms. *Indian journal of otolaryngology and head& neck surgery*; 62: 277-284.
- 5- Batsakis J.G. (1979): Squamous cell "papillomas" of the oral cavity, sinonasal tract and larynx. *Tumors of the Head and Neck*. 2nd ed. Baltimore, Md: Lippincott Williams & Wilkins; 13-43.
- 6- Matoušek P., Zeleník K., Safářčík K., Cábálová L., Komínek P. (2014): Squamous cell carcinoma antigen as a marker of sinonasal inverted. *Eur Arch Otorhinolaryngol*; 271: 535–538.
- 7- Suminami Y., Nawata S., Kato H. (1998): Biological role of SCC antigen. *Tumor Biol* 19:488–493.
- 8- Krouse J.H. (2000): Development of a staging system for inverted papilloma. *Larvngoscope*; 110: 965-968 & 113:1541-1547.
- 9- Lombardi D., Tomenzoli D., Butta L., bizzoni A., Farina D., Sberze F., Karligkiotis A., Castelnuovo P., Nicolai P. (2011): Limitations and complications of endoscopic surgery for treatment for sinonasal inverted papilloma: a reassessment after 212 cases. *Head Neck*; 33: 1154–1161.
- 10- Xiao-Ting W., Peng L., Xiu-Qing W., Hai-Bo W., Wen-Hui P., Bing L., Er-Peng Z., Guang-Gang S. (2013): Factors affecting recurrence of sinonasal inverted papilloma. *Eur. Arch. Otorhinolaryngol*; 270: 1349–1353.
- 11- Mirza S., Bradley P.J., Acharya A., Stacey M., Jones N.S. (2007): Sinonasal inverted papillomas: recurrence, and synchronous and metachronous malignancy. *J. Laryngol. Otol*; 121: 857–864.
- 12- Kim D.Y., Hong S.L., Lee C.H., Jin H.R., Kang J.M. and Lee B.J. (2012): Inverted papilloma of the nasal cavity and paranasal sinuses: a Korean multicenter study. *Laryngoscop*; 122: 487–494.
- 13- Sciarretta V., Fernandez I.J., Farneti P. (2014): Endoscopic and combined external-transnasal endoscopic approach for the treatment of inverted papilloma: analysis of 110 cases. *Eur. Arch. Otorhinolaryngol.* ; 271: 1953–1959.
- 14- Jardine A.H., Davies G.R., Birchall M.A. (2000): Recurrence and malignant degeneration of 89 cases of inverted papilloma diagnosed in a non-tertiary referral population between 1975 and 1995: clinical predictors and p53 studies. *Clin. Otolaryngol*; 25: 363–369.
- 15- Yasumatsu R., Nakashima T., Kuratomi Y., Hirakawa N., Azuma K., Tomita K., Cataltepe S., Silverman G.A., Clayman G.L., Komiyama S. (2002): Serum squamous cell carcinoma antigen is a useful biologic marker in patients with inverted papillomas of the sinonasal tract. *Cancer*; 94: 152-158.
- 16- Yasumatsu R., Nakashima T., Masuda M. Kuratomi Y., Shiratsuchi H., Hirakawa N., Tomita K., Yamamoto T., Komune S. (2005): Clinical value of serum squamous cell carcinoma antigen in the management of sinonasal inverted papilloma. *Head Neck*; 1: 44–48.
- 17- Van Zijl F., Monserez D.A., Korevaar T.I.M., Bugter O., Wieringa M.H., Baatenburg de Jong R.J., Hardillo J.A.U. (2017): Postoperative value of serum squamous cell carcinoma antigen as a predictor of recurrence in sinonasal inverted papilloma. *Clin. Otolaryngol*; 42: 528–535.

11/2/2021