



Prevalence of rumen and reticulum foreign bodies and its associated risk factors in cattle slaughtered at Assosa municipal abattoir western Ethiopia

Yohannes Hailemichael^{1*}, Mulusew Kefiyalew^{1*}, Ahemed Muhamed², Senayt Zewedu²

^{1*} Assosa University, College of Agriculture and Natural Resource, Department of Veterinary Science, Western Ethiopia, P.O.BOX 18, Email Address: hmichaelyohannes123@gmail.com

² Assosa University, College of Agriculture and Natural Resource, Department of Veterinary Science, Western Ethiopia

Abstract: A cross sectional study was conducted on cattle slaughtered at Assosa municipal abattoir from November 2018 to June 2019 to determine the prevalence of foreign bodies in rumen and reticulum of cattle and to assess the association of risk factors with the occurrence of foreign bodies. Postmortem examination was conducted for the recovery of foreign body from rumen and reticulum. A total of 367 cattle were selected using purposive sampling method and of which 147 (40%) of them were found positive for indigestible foreign bodies in their rumen and/or reticulum. Risk factors such as age, body condition score and origin were taken into consideration. There was statistical significance difference between prevalence recorded in adult (22%) and old (17%, $p=0.02$). Statistical significant difference were recorded in medium (25%) and fat (14%, $p=0.00$). However, no statistical significance difference ($P > 0.05$) was observed in origin recorded for urban (27%) and rural (12%, $p=0.79$). The prevalence of plastics foreign body (14.7%) is higher followed by indigestible food materials (10.8%) and rope (3.5%). The prevalence of foreign body ingestion found in cattle by this study shows that the grazing areas were contaminated with clothes, plastic material, ropes, and other indigestible materials could pose serious health problem for free grazing animals. Awareness should be created on careless disposal of indigestible materials and the periodical cleaning of these wastes in the grazing area should be established in the study area.

[Yohannes Hailemichael, Mulusew Kefiyalew, Ahemed Muhamed Senayt Zewedu. **Prevalence of rumen and reticulum foreign bodies and its associated risk factors in cattle slaughtered at Assosa municipal abattoir western Ethiopia.** *J Am Sci* 2020;16(10):83-89]. ISSN 1545-1003 (print); ISSN 2375-7264 (online). <http://www.jofamericanscience.org>. 9. doi:[10.7537/marsjas161020.09](https://doi.org/10.7537/marsjas161020.09).

Keywords: Abattoir, Assosa, Cattle, Foreign body, Reticulum -rumen, Prevalence

1. Introduction

Ethiopia is a home for many livestock species and suitable for livestock production have the largest livestock population in Africa (Solomon *et al.*, 2003); (CSA, 2013). An estimate indicates that the country is a home for about 54 million cattle, 25.5 million sheep and 24.06 million goats. From the total cattle population 98.9 remaining are hybrid and exotic breeds (Behnke, 2010).

However, Ingestion of foreign body in cattle results a condition of great economic importance and causes severe loss of production and high mortality rate (Rodestis *et al.*, 2007). The ingestion of foreign body is mainly related with nutritional deficiencies and feeding management and cause various problem in different organ of the animal mainly in rumen and reticulum. The problem that are caused vary with the duration that the foreign body has been present, the location of the foreign body, the degree of obstruction that is caused as well as problem associated with the

material of the foreign body. Ruminants are notorious for ingestion of foreign bodies (Calfee *et al.*, 2002).

Rumen tympani is an impaction of rumen from the accumulation of foreign bodies, such as plastic bags causes interference with the flow of ingesta leading to distension of rumen and absence of defecation are among the most common cause of gastrointestinal disorders in ruminants. TRP is also a sporadic disease in ruminants caused by perforation of the reticulum due to ingestion of foreign materials, which is a common cause of abdominal surgery in cattle (Ghanem, 2010).

The problems that are caused vary with the duration that the foreign body has been present, the location of the foreign body and the degree of obstruction that is caused as well as problems associated with the material of the foreign body (Mc.Curin and Basser, 2006). Sharp foreign body may penetrate any part of the digestive tract. These may be lodged in the mouth, the esophagus, the stomach, the

intestine, the diaphragm or the pericardium (Shuttleworth *et al.*, 2000).

The ingestion of indigestible foreign bodies may occur during period of feed scarcity (Igbokwe *et al.*, 2003). Reports from cattle and sheep reared within urban and sub-urban environments indicates that impaction of the rumen resulted from the accumulation of foreign bodies such as plastic bags interfered with flow of ingesta leading to the distension of rumen (Remi-Adewunmi *et al.*, 2004). The presence of foreign bodies in the rumen and reticulum also hampers the absorption of volatile fatty acids and consequently reduction in the rate of animal fattening (Igbokwe *et al.*, 2003).

The presence of foreign bodies in the rumen and reticulum also hampers the absorption of volatile fatty acids and consequently reduction in the rate of animal fattening. Cattle are more susceptible to foreign body syndrome than small ruminants because they do not use their lips for prehension and are more likely to eat chopped feed; lack of oral discrimination in cattle may lead to ingestion of foreign bodies would be rejected by other species (Desiye and Mersha, 2012). Non-metallic foreign bodies in the reticulo-rumen cause recurrent rumen tympani in adult dairy cattle, over a period of time, these materials, form large tight balls inside the rumen leading to anorexia decreased production and progressive loss of body condition (Jafarazadeh *et al.*, 2004)

In Ethiopia, information regarding the magnitude and occurrence of fore-stomach foreign bodies is very limited and there is no information about the prevalence of foreign body in cattle in present study area. The fact that rumen impaction by these foreign bodies is mainly asymptomatic in nature and only diagnosed in live animals if the material is accumulated in large amount and thus, it can be adequately studied in abattoirs (Igbokwe *et al.*, 2003). In present study we determine the prevalence of indigestible rumen-reticulum foreign bodies in cattle slaughtered at Assosa municipal abattoir.

2. Materials and Methods

This study was conducted at Assosa which is located in the west and North West part of Ethiopia, between latitude 9° and 11° North and longitude 34° and 35° East. Assosa is the capital city of Benshangul Gumuz regional state and it is about 675km from Addis Ababa. It has common boundaries with Amhara and Oromia in the north, Sudan in the west and Gambela in the south. According to the Assosa district Agricultural and Rural Development Office, the district is divided into 78 peasant associations (PA) with total populations of 92,144. The district is located in 580- 1500 meter above sea level, wet temperature of 19°C-34°C. The average rain fall is 900-1200mm

annually and the total area of the district is about 2317km². The total livestock of the region is estimated as: 309,629 cattle, 58767 sheep, 200 470 goat 559 horses, 30 952 donkeys, 1394 mules, 15 camels and 981,196 poultry (WZAO, 2011).

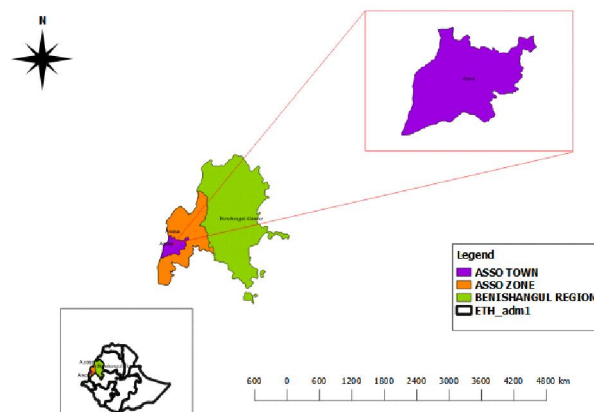


Figure: Map of study area

A cross-sectional study was conducted from November 2018 to June 2019 for the prevalence of indigestible foreign bodies in cattle slaughtered at Assosa municipal abattoir and to highlight associated risk factors.

The study animals was cattle slaughtered at Assosa municipal abattoir that varies with origin, age, sex, body condition and breed

Cattle presented for slaughter were purposively selected depending on origin (urban or rural), sex (male and female), age (young and old) and body condition score prior to slaughter. Age will be determined based on dental eruption. Body condition was evaluated based on scores ranging from Score 1 (physically thin), 2 (medium) and 3 (fat). After slaughter the rumen and reticulum was removed carefully from the abdominal cavity and opened, and any foreign body obtained was washed, dried, identified and weighed accordingly.

The sample size was calculated according to Thrusfield (1995) expected prevalence of 50% and 95% confidence level with a 5% desired absolute precision. Thus:

$$n = 1.96^2 \times P_{exp} (1 - P_{exp}) / d^2$$

Where, n= required sample size; p_{ex} = expected prevalence, and d = desired absolute precision.

Based on calculation the calculated sample size was 384. However due to shortage of time, a total of 367 head of cattle was sampled to determine the prevalence of indigestible foreign body and associated risk factors in the present study area.

Data was collected and stored in Microsoft (MS) Excel Spread Sheet program and Categorical variables were summarized as frequency and percentages.

Descriptive statistical analysis of various risk factors and dependent variables were done using (STATA software version 13). The chi-square test was used to test prevalence of indigestible foreign body with association categorical risk factors. Descriptive statistical analysis such as table was used to summarize and present the data collected. The total prevalence of indigestible foreign bodies was

calculated as percentage, by dividing total number of positive cattle for foreign bodies to the total number of cattle examined from Assosa municipal abattoir. Univariate logistic regression was used to test the significance of the effect of different risk factors on prevalence of foreign body.

3. Result

Table 1: The binary logistic regression analysis result of the effect of risk factors on prevalence of indigestible foreign body

| Risk factors | No. Tested | No. positive | Prevalence% | 95% CI | P-value |
|-----------------------|------------|--------------|-------------|------------|---------|
| Origin | | | | | |
| Urban | 232 | 100 | 27% | | |
| rural | 135 | 47 | 12% | 0.61, 1.45 | 0.79 |
| Body condition | | | | | |
| Fat | 238 | 52 | 14% | | |
| Medium | 129 | 95 | 25% | 0.03, 0.10 | 0.00 |
| Age | | | | | |
| adult | 233 | 82 | 22% | | |
| Old | 134 | 65 | 17% | 1.1, 2.26 | 0.02 |
| Total | 367 | 147 | 40% | | |

Table 2: Prevalence of foreign body based on type foreign body identified

| Type of foreign body identified | No of animal with foreign body | Prevalence % |
|---------------------------------|--------------------------------|--------------|
| Plastic | 54 | 14.71 |
| Indigestible food materials | 40 | 10.89 |
| Rope | 13 | 3.54 |
| Cloth | 9 | 2.45 |
| Leather | 11 | 2.99 |
| Thread | 6 | 1.63 |
| Wire | 11 | 2.99 |
| Wood | 3 | 0.81 |
| Total | 147 | 40% |

The result of examined slaughtered cattle for the presences of any foreign bodies in their rumen and reticulum were discussed detail with its associated risk factors such as age, body condition, and origin in (table 2). The types of foreign bodies detected in this study were plastic, cloth, indigestible food materials, rope, wood, leather, thread and wire, In the present study the prevalence of plastics foreign body (14.7%) is higher followed by indigestible food materials (10.8%) and rope (3.5%). Out of the total 367 heads of cattle slaughtered at Assosa municipal abattoir examined for the Presences of any foreign bodies in their rumen and reticulum, 147 (40%) were positive (Table 1). The study animals were grouped into the age group of adult (4-7 years) and old (7+ years). In this Study 233 adults and 134 old animals were examined for foreign body in their fore stomach. Among these examined animals 82(22%) adult and 65

(17%) old were positive for foreign body ingestion shown in table1. There was significant difference ($p=0.02$) between adult and old animals in the Occurrence of foreign body in their fore-stomachs of rumen and reticulum. Type of foreign bodies encountered in the fore-stomach of animals between adult and old aged animals were more similar. Most of the animals brought to abattoir to be slaughtered were comprised fat and medium body condition score. 238 fat and 129 slaughtered cattle were examined for the presences of any foreign bodies in their rumen and reticulum. From these examined animal 52 (22%) fat and 95(17%) were positive for foreign body, in their rumen and reticulum respectively. There was significant difference ($p=0.00$) between different body condition scores and foreign body prevalence in rumen and reticulum. Cloth, plastic, thread, rope and leather were more frequently encountered in medium body

condition cattle, while in fat body condition of the cattle were found to have indigestible feed seeds (i.e. mango seed and dokma seed) nail and plastics. The study animals were grouped into the origin of urban and rural. In this Study 232(27%) urban and 135(12%) rural animals were examined for foreign body in their fore stomach. From these examined animal 100 (27%) urban 47(12%) rural were positive for foreign body, in their rumen and reticulum. There was no significant difference ($p=0.79$) between adult and old animals in the Occurrence of foreign body in their fore-stomachs of rumen and reticulum.

4. Discussion

Prevalence of foreign body ingestion such as cloth, plastic, rope, leather, wire, nail and other indigestible materials found in ruminants could poses serious health problem among free grazing animals (Abebe and Nuru, 2011). This study revealed an overall prevalence of indigestible rumen and reticulum foreign bodies prevalence of 147 in cattle slaughtered at Assosa municipal abattoir.

The present prevalence rate of foreign bodies is higher than the finding of Dawit (2012)23.9% the report of Rahel (2011) 17.07% and Desiye and Mersha (2012) 13.22% of prevalence of fore stomach foreign bodies in Hawasa and Jimma municipal abattoir, Ethiopia respectively. The difference in the prevalence rate may be due to the feeding system in which the animals were kept. Feed shortage usually occurs at specific time of the year in most part of Ethiopia.

It has been reported that ingestion of foreign bodies is associated with shortage of forage and increased pollution of grazing land with indigestible foreign bodies (Hailat *et al.*, 1996), Moreover; most owners do not provide supplementary feed to animals. These in turn may predispose the animals to negative energy balance and force them to feed on unusual materials including plastics, clothes, ropes and even metallic substances (Hailat *et al.*, 1996). Wide spread use and improper disposal of plastics that are used for packing of goods could also contribute for the occurrence of foreign bodies in the rumen and reticulum (Tsfaye *et al.*, 2012).

Lack of awareness among livestock owners on the risk of ingestion of these foreign materials by animals may also contributed for the occurrence of foreign bodies in the rumen and reticulum (Remi *et al.*, 2004). Higher prevalence was reported by Ismael *et al.* (2007) 77.41% of adult dairy cattle in Jordan and Anwar *et al.* (2013) 59.14% in achai cattle at different regions of Khyber Pakhtunkhwa. The Variation in the prevalence rate may be due to differences in the origin of animals presented for Slaughter, waste management system of the countries and the drought condition in the study year. The types of foreign bodies detected in

this study were wire, nail, plastic, leather, cloth and bone wood and indigestible feed seeds. Hailat *et al.* (1997) also found plastic bags, nails, hair balls, ropes and leather occurring as indigestible foreign bodies. In the present study the prevalence of plastics foreign body (14.7%) is higher followed by indigestible food materials (10.8%) and rope (3.5%) among the rest examined foreign body (Table 2). This study was disagreement with the finding of Ducharme and Fubini (2004). According to Ducharme and Fubini (2004) they have reported that wires account for approximately 70% of ingested foreign bodies and nails and other objects make up the other 30%. The difference in the prevalence rate might be due to differences in the origin of animals presented for slaughter and type of waste management system between the countries (Hewot, 2008) In this study there was no significant ($P=0.79$) difference between origin of animals. Animals that originate from urban have great percentage (27%) of foreign body in their rumen and reticulum; however, animals originate from rural area covers low percentage (12%) of foreign body in the rumen and reticulum. Most indigestible foreign bodies found in cattle originated from urban are plastics and from rural indigestible seeds.

In these study there was a significant difference ($p=0.02$) between age of cattle. Cattle that are aged between 3-4 years (young) have great percentage of foreign body than that of aged greater than 7 years. The highest prevalence of rumen and reticulum foreign bodies were detected in adult cattle between 4-7 years old 22% as compare to above7 year's old 12% slaughter in Assosa municipal abattoir. This result was not agree with results of Desiye and Mersha (2012) 10.53%, 12.81%, and 80% within the aged group of <5, 5-10 and >10 years in cattle slaughtered at Jimma municipal abattoir. These variation in the prevalence rate may be due to differences in the origin of animals presented for slaughter (at Assosa municipal abattoir greater number of cattle presented for slaughter are adult due to this great percentage of cattle contained foreign body are adults) and by chance. In the present study there was significant ($P=0.00$) difference between body condition. Prevalence of foreign body is higher in medium (25%) body condition score as compare to fat (14%) body condition score. This result is in agreement with the findings of Roman and Hiwet (2010). Remi *et al.* (2004), Ismael *et al.* (2007), Rahel (2011) and (Anwar *et al.* (2013)) reported a higher prevalence in animal having poor body condition. Poor body condition by itself might be due to the contribution of the foreign body that is the animal loss weight after it has been exposed to indigestible materials (Remi *et al.*, 2004; Roman and Hiwet 2010).

Foreign body syndrome is becoming a problem to livestock owners and farmers of our country greatly

attributed to heavy industrialization and human habitation which has increase the chance of livestock to ingest such objects. Ingestion of indigestible materials may occur during period of food scarcity. Rumen and reticulum foreign bodies can significantly affect the digestion process by occupying space and blocking ingesta movement which ultimately impair the health and Productivity of animals, indigestible foreign bodies' materials could pose serious health problem for free grazing ruminants unless appropriate measure is taken. Cross breed cattle are the most affected groups compared to that of local breed cattle. Hence, sex, breed, age and body condition score of animals are the considered risk factors for the occurrence of foreign bodies. Based on the above conclusions the following points are recommended. Public awareness should be created on careless disposal of plastic bags, rope and leather and as well as the periodical cleaning of these wastes in the grazing area.

Acknowledgements

We are grateful to Assosa University College of agriculture and natural resource for their help throughout these works,

Corresponding Author:

Dr. Yohannes Hailemichael
Department of Veterinary Science
Assosa, Ethiopia
Telephone: +251-911-93-04-27
E-mail: hmichaelyohannes123@gmail.com
Mulusew Kefiyalew
Ahemed Muhamed
Seneyit Zewude

References

1. Athar, H., Mohindra, J., Slingh. K and Singh, T., 2010: Harmful effect of plastic in animals.
2. Behnke, R. (2010): The contribution of livestock to the economics of IGAD member states application of the methodology in Ethiopia and recommendations for further work. Odessa centre, IGAD livestock policy initiative, Great wolford, UK.
3. Boodur, P., Sivaprakash, B.V., Kasaralivar, V. and Rand-Dilip, D., 2010: Harmful effect of plastic in animals, department of animal husbandry and dairying. Indian Poly vet, 11, p. 184-.
4. Calfee, T., and Manning, T., (2002): Non-relating subcutaneous wounds in cat and proposed in the surgical management techniques. Clinical Techniques Small Animal Practice, 17(4), 162-167.
5. CSA. (2013): Central Statistics Agency of FDRE. Agricultural Sample Survey and Report on Livestock and Livestock characteristics, Addis Ababa, Ethiopia, Part 2, p. 8-50.
6. Desiye, T., and Mersha, C. (2012): Study on Rumen and Reticulum Foreign Bodies in Cattle Slaughtered at Jimma Municipal Abattoir, South West Ethiopia. *Amer. Eur. Jour. Sci. Reser.* 7(4): 160-167.
7. Ducharme, N. G. and S. L. Fubini., 2004: Farm Animal Surgery. Elsevier Health Sciences, St. Louis, Mo, ISBN.p: 624.
8. Ghanem, M. (2010): A comparative study on traumatic reticulo peritonitis and traumatic pericarditis in Egyptian cattle; *Turk J Vet AnimSci*, 34, p. 143-153.
9. Ghurashi, M., Seri, H. I., Bakheit, A. H. and Ashwag, E., 2009: Effect of surgical removal of foreign body from goat's rumen with special reference to the prevalence of foreign body in goats in Southern Darfur. *Australian. J. Basic. Appl. Sci*, 3(2), P. 664-668.
10. Gokce, H. I., Gerra, T. and Cihan, M., 2007: Alterations in coagulations profiles and biochemical and hematological parameters in cattle with traumatic reticuloperitonitis. *Vet Res Commu*, 31, P. 529-536.
11. Hailat, N., South, S., Al-Darraj, A. and Al-Majali, A., 1996: Prevalence and pathology of foreign bodies in Awassi sheep. *Jordan small ruminant research*, p. 43-48.
12. Hewot, Y., 2008: Occurrence of rumen foreign bodies in sheep and goats slaughtered at Addis Ababa municipal abattoir. DVM thesis, Faculty of Veterinary Medicine, Addis Ababa University, Debrezeit, Ethiopia.
13. Igbokwe, I., Kolo, M., and Egwu, G, (2003): Rumen impaction in sheep with indigestible foreign body in the semi-arid region of Nigeria. *Small Ruminant Res*, 3, p. 141-147.
14. Jafarazadeh, S., Nowrouzian, Z., and AdibHashemi, F. (2004): The sensitivities and specificities of total plasma protein and plasma fibrinogen for the diagnosis of traumatic reticuloperitonitis in cattle. *Preventive Veterinary Medicine*, Pp 1-7.
15. Kahn, M. C., 2005: The Merck Veterinary Manual, 8th ed, Merck and Co., INC. White house station, USA, p. 98, 185-192.
16. Karademir, B. and Çitil, M., 2001: Statistical evaluation of cattle with TRP submitted to the clinics.
17. McCurin, D., and Basser, J. (2006): Clinical text book for veterinary technicians. 6th ed. Elsevier Saunders, Pp: 224-244.

18. Radostits, O., Gay, C., Hinchcliff, K., and Constable, P., (2007): *Veterinary Medicine; a text book of the diseases of Cattle, Horses, Sheep, Pigs and Goats*; 10th ed, Elsevier Limited, p. 337-352.
19. Radostits, O.M., Gay, C.C., Hinchcliff, K.W. and Constable, P.O., 2007: *Veterinary Medicine, a text book of the diseases of Cattle, Horses, Sheep, Pigs and Goats*. 10th ed, Elsevier Limited, p. 337-352.
20. Ravindra, R. Y., Asha, L. P and Sandeep, R. S., 2014: Review on metallic and non-metallic foreign bodies a threat to livestock and environment. *International Journal of Food, Agriculture*.
21. Remi, D., Gyang, E. O. and Osinowo., 2004: Abattoir survey of foreign body rumen impaction .
22. Remi-Adewunmi, B., Gyang, E., and Osinowo, A. (2004): Abattoir Survey of Foreign Body Rumen Impaction in Small Ruminants. *Niger. Vet. Jour*, 25, 32-38.
23. Roman, T. and Hiwot, Y., 2010: Occurrence of rumen fibrinogen for the diagnosis of traumatic.
24. Ruminants Slaughtered at Jimma Municipal Abattoir, Southwestern Ethiopia Hawassa University, and School of Veterinary Medicine, Ethiopia. *J Vet Adv*, 2(8), p. 434-439.
25. Schipper, I. A., 2000: *Lecture outline of Preventive Veterinary Medicine*. 6th ed., Surgeet.
26. Sharma, M. S and Pankaj, K., 2006: *Avian Journal of Animal and Veterinary Advances* 1 (1), p. 89-98.
27. Shuttleworth, A., and Smyth, R. (2000): *Clinical veterinary surgery: Volume; 2*, Green World Publishers, p. 179-203.
28. Singh, B. Colony, R. and Bijnor, D., 2005: Harmful effect of plastic in animals, department of small ruminants. *Nigerian Vet. J*, 25, p. 32-38.
29. Solomon, A., Workalemahu, A., Jabbar, M., Ahmed, M., and Hurissa, B. (2003): *Socio-economic and Research Working Paper 52*, ILRI, Nairobi.
30. Tesfaye D., Yismaw S. and Demissie T., 2012: Rumenal and Reticular Foreign Bodies in Small.
31. Turkar, S., Sharma, A. k, Dhaliwal, P. S. and Gopinathan, A., 2010: Traumatic reticulopericarditis *Intas Poly vet* 11, p. 191-193.
32. Vijaya, B. M. and Sasikala, P., 2012: A Review on Foreign Bodies with Special reference to plastic pollution threat to live stock and environment in Tirupati rural areas. *International Journal of Scientific and Research Publisher, Wolaita Zone Agricultural Office* (2011): *Livestock statistical data of Wolaita zone, Wolaita zone agricultural office livestock and natural resource development team*.

Annex

1. Age determination in cattle based on teeth eruption.

| No | Teeth | Ages |
|----|--|---------------------------|
| 1 | I ₁ erupts | 1 _{1/2} -2 years |
| 2 | I ₂ erupts | 2-2 _{1/2} years |
| 3 | I ₃ erupts | 3 years |
| 4 | C erupts | 3 _{1/2} -4 years |
| 5 | All incisors are wear | 5 years |
| 6 | I ₁ is level and the neck has emerged from the gum | 6 years |
| 7 | I ₂ is level and the neck is visible | 7 years |
| 8 | I ₃ is level the neck is visible | 8 years |
| 9 | C is level and the neck is visible | 9 years |
| 10 | The teeth that have not fallen out are reduced to small round pegs | 15 years |

2. Sample of foreign bodies that are present in animal body



10/27/2020