



## Evaluation of Bone Density after Bone Condensation around Immediate Loaded Dental Implants using Different Techniques

Amira Ahmed Mohamed Mohamed Attia<sup>1\*</sup>, Wael Mohamed Said Ahmed<sup>2</sup>, Mai Ahmed Haggag<sup>3</sup>, Mohamed Abdel-Moniem Tawfik<sup>4</sup>

<sup>1</sup>Teaching assistant at oral and maxillofacial surgery, Faculty of dentistry -Mansoura University, Mansoura Egypt

<sup>2</sup>Assistant professor of Oral and Maxillofacial Surgery, Faculty of Dentistry - Mansoura University, Mansoura Egypt

<sup>3</sup>Lecturer of Oral and Maxillofacial Surgery Faculty of Dentistry - Mansoura University, Mansoura Egypt

<sup>4</sup>Professor & Head of Oral and Maxillofacial Surgery, Faculty of Dentistry - Mansoura University, Mansoura Egypt  
Emails: [sweety\\_amira6@hotmail.com](mailto:sweety_amira6@hotmail.com), [drwaelmohamed2020@gmail.com](mailto:drwaelmohamed2020@gmail.com), [drmaihaggag5@gmail.com](mailto:drmaihaggag5@gmail.com),  
[memotaw2002@gmail.com](mailto:memotaw2002@gmail.com)

**Abstract:** Objectives: The purpose of this study was to assess the bone density changes around immediate loaded dental implants after bone condensation with different techniques. Materials and Methods: Twenty-one implants were inserted in 14 female patients with missing maxillary posterior teeth. Patients were randomly divided according to the method of osseodensification into three equal groups. **Group I:** The osseodensification technique was performed by densah burs, which followed by immediate implantation. **Group II:** Bone expander technique was used and followed by immediate placement of implant with progressive threads design. **Group III:** Conventional surgical drilling technique was used and followed by immediate placement of implant with progressive threads design. Implant stability was clinically assessed at three and six months post-operatively. Moreover, Peri-implant Probing Depth (PPD) and Modified Sulcus Bleeding Index (mSBI) were evaluated at three and six months post-operatively. For radiographic assessment of bone density, CBCT was obtained preoperatively, and immediately postoperative. All clinical and radiographic data were subjected to statistical analysis. Results: Regarding implant stability, PPD and mSBI, no statistically significant difference was found between the three groups. The immediate postoperative bone density showed significant increase in the three groups when compared with the preoperative bone density. Conclusion: Bone density measurements increased postoperatively as a result of bone compression around the placed implants, which is important especially in areas of poor bone quality as the posterior maxilla for enhancing the initial implant stability.

[Amira Ahmed Mohamed Mohamed Attia, Wael Mohamed Said Ahmed, Mai Ahmed Haggag, Mohamed Abdel-Moniem Tawfik. **Evaluation of Bone Density after Bone Condensation around Immediate Loaded Dental Implants using Different Techniques.** *J Am Sci* 2020;16(7):33-42]. ISSN 1545-1003 (print); ISSN 2375-7264 (online). <http://www.jofamericanscience.org>. 6. doi:[10.7537/marsjas160720.06](https://doi.org/10.7537/marsjas160720.06).

**Keywords:** bone condensation; densah burs; bone expanders; implant with progressive threading.

### 1. Introduction:

Implant treatment in maxillary ridge offers greater challenges and successful implant therapy depends on adequate bone quality and quantity. Clinical studies have shown lower survival rates of implants placed in maxilla<sup>(1,2)</sup> which can be attributed to poor bone quality or availability of less dense bone.<sup>(3)</sup>

Bone quality is the poorest in edentulous posterior maxilla compared with any other intraoral region.<sup>(4)</sup> Concerning *Lekholm and Zarb* classification, the posterior maxilla usually composed of type IV bone quality with thin cortical plate and fine loose trabecular cancellous bony core.<sup>(5)</sup>

Such a problem could negatively influence the histomorphometric parameters (such as bone to implant contact percentage and bone volume percentage) and, consequently, both primary and secondary implant stabilities.<sup>(6)</sup> This problem can be managed by condensation of the bone which significantly increases bone density in peri-implant area in relation to standard surgical technique.<sup>(7)</sup>

Threaded bone expanders are hand (finger pressure or a ratchet) or motor-driven tools used to create bone expansion by screwing into bone instead of tapping with a mallet. They are a series of implant-shaped instruments with increasing diameters used to prepare the implant site by compressing the bone

apico-laterally, thereby increasing the bone density locally.<sup>(8)</sup>

For the placement of endosteal fixtures, a drilling technique called osseodensification was implemented. Osseodensification is done in an attempt to develop a simplified autografting around the implant, making it useful in areas of poor bone quality.<sup>(9)(10)</sup> Unlike traditional drilling protocols (which we refer to as subtractive drilling), osseodensification increases primary stability with non-subtractive drilling due to densification of the drilled osteotomy site walls centrifugally.<sup>(9)</sup>

A series of new thread designs of the dental implants have been proposed to better stabilize the implant in the bone. Implant macro- and microtopographies have been introduced on the market<sup>(11, 12)</sup>, for reducing bone healing times, accelerating, and enhancing the osseointegration.<sup>(13)</sup>

Implants with knife-edge threads appear to be the best option for clinically challenging situations (such as areas of low bone quality or immediate loading protocols).<sup>(14)</sup>

Based on the aforementioned data, it is believed to be of interest to evaluate the bone density around immediate loaded dental implants after bone condensation with different techniques using; bone expanders, densah burs and implant with progressive threads design when inserting dental implants in the maxillary posterior region.

## 2. Patients and methods:

### 1. Patients selection

- Twenty-one implants were inserted in patients selected from the Outpatient Clinic of the Oral and Maxillofacial Surgery Department, Faculty of Dentistry, Mansoura University who needed for replacement of missing maxillary posterior teeth with dental implant.

- The inclusion criteria were: adult patients (age between 18 to 45 years), who needed one or more dental implants in the posterior maxilla, adequate occlusion and patient cooperation.

- The exclusion criteria were patients with systemic or local diseases that contraindicate surgery or implant placement, pregnancy, any bone disease that interfere with bone healing, smokers and parafunctional habits such as bruxism and clenching.

- The patients were informed about the study, and written consent was obtained from each patient.

### 2. Preoperative Evaluation

Each patient was investigated clinically and radiographically. CBCT was used to accurately assess the bone volume (height/width) available for implant placement and to measure the bone density in the site of implant placement (to be compared with the immediate post-operative density).

### 3. Study design:

21 implants were randomly divided according to the method of osseodensification into three equal groups. **Group I:** performed by osseodensification technique using densah burs, followed by immediate implantation. **Group II:** performed by bone expander's technique, followed by immediate implantation. **Group III:** performed by conventional surgical drilling technique followed by placement of implant with progressive threads design.

### 4. Materials:

- Densah bur kit (Densah®, Versah, LLC, Jackson, Michigan,): consists of 12 burs to create the desired osteotomy diameter for all major dental implants on the market. These surgical autoclavable burs are designed to be used with standard surgical engines with drill speed 800-1500 rpm in a counter clockwise (reverse) direction (densifying mode).

Bone Expander kit (MCT Bone Expander (Mr. Currete Tech.), South Korea): The set consists of five incrementally enlarged expanders with a sharp terminal end. These are surgical autoclavable manual threaded bone expanders, which are tapered to insert wide range of implant systems.

- Dental Implants:

- **For group I and II:** conventional, two pieces, screw type titanium dental implants (Neo Biotech, Korea.) were used.

- **For group III:** two-pieces, titanium Jdental Care (Jdental Care, Moderna, Italy) dental implants were used.

### 5. Implant placement:

The study was conducted by the same surgeon, who performed all the surgeries. All surgical procedures were done under complete aseptic condition. Prophylactic antibiotic was prescribed (2 gm Amoxicillin (Emox, Egyptian Int. Pharmaceutical Industries Co., E.I.P.I.C.O., A.R.E.) one hour before the surgery). Chlorhexidine (Orovex, contain Chlorhexidine Manufactured by MARCO Group Pharmaceuticals, Egypt.) mouth wash was used for one minute just prior to surgery.

Local anesthesia was achieved using buccal infiltration injection (1.5 ml) together with palatal infiltration injection (0.3 ml). Paracrestal incision and elevation of the mucoperiosteal flap was done.

For **group I:** The initial osteotomy was done using the pilot drill to the desired depth. The implant bed was widened using densah burs in small increments allowing bone condensation (Counterclockwise drill speed 800-1500 rpm with copious irrigation).

For **group II:** The initial osteotomy was done using the pilot drill to the desired length then the smallest expander ( $\varnothing = 2.6$  mm) was inserted manually by Manual Knob and then being screwed in the

clockwise direction by Ratchet Wrench till the desired depth. Then the expander was turned into anti-clockwise direction and pulled out of the osteotomy site then followed by next successive larger expanders till reaching the desired length and width that were planned.

For **group III**: conventional bone drilling according to the recommended protocols of the manufacturer.

After preparation of implant beds for all groups, the implants were slightly positioned subcrestally (0.5 to 1 mm), according to the recommendation of the manufacturer. The flap was repositioned and sutured around the healing abutments. After that open tray impressions were taken.

#### 6. Postoperative phase:

Immediate post-operative CBCT was done to assess the relative bone density. Antibiotic (Emox, Egyptian Int. Pharmaceutical Industries Co., E.I.P.I.C.O., A.R.E.) was prescribed for 7 days. All patients were instructed to maintain optimal oral hygiene, avoid chewing solid textured food, apply ice packs over the area for the first day and then warm packs for the following two days. After 7 days, sutures were removed.

#### 7. Evaluation:

##### • Clinical evaluation:

Implant stability was done immediate, 3 months and 6 months postoperatively. Periodontal pocket depth (PDD) and modified Sulcus Bleeding Index (mSBI) were done at 3 months and 6 months postoperatively.

##### • Radiographic evaluation:

CBCT was used for the evaluation of relative bone density surrounding the dental implants before the operation and immediately postoperative. All patients' scans were taken by a Planmeca ProMax® 3D unit (Planmeca OY, Helsinki, Finland) using fixed imaging parameter at every scan. All DICOM data were then analyzed using On Demand3D software.

#### Bone Density Recording:

- For all edentulous area planned for an implant placement operation grayscale values were measured. Using the greyscale bone measuring tool, all the density records were collected from the bucco-palatal view of the cross-sectional plane.

- For every implant site, six different records were taken. For recording the exact position of the implant fixture and to maximize the accuracy of the measurements on the preoperative measurements; the records were collected on the postoperative CBCT firstly with the implant already positioned in its place.

- Measurements were taken in a parallel manner away from the implant fixture by 1 mm. Three readings in the buccal side (coronal, middle and apical

thirds) of the implant fixture and then three readings in the palatal side (in the same way).

- Using the measurement tool preoperative CBCT were then collected in the same way after calculating the location of the implant. By the same examiner, all preoperative and post-operative locations were re-measured and the average of the two measurements were considered. The mean grayscale values in the same section were analyzed and bone densities from both tomographs were compared.

#### Statistical Analysis

Data were tabulated, coded then analyzed using the computer program SPSS (Statistical package for social science) version 23.0.

#### 3. Results:

This study sample included 21 implants placed in 14 female patients. Five patients in group I, four patients in group II and seven patients in group III. The age of the patients, ranged between 21 and 36 years.

All implants exhibited successful signs of osseointegration except one implant in group II (Expanders) showed clinical mobility just one month postoperatively and this implant was replaced by another one in a new patient.

#### Clinical results:

- **Implant stability:** as shown in table (1) the assessment of implant stability immediately postoperative as well as along the evaluation intervals; there was no statistical significant difference between the three groups ( $p > 0.05$ ).

##### ✚ In group I

Implant stability of 3 months postoperative ( $74.00 \pm 4.58$ ) showed non significant difference ( $p = 0.69$ ) compared to immediate postoperative ( $75.14 \pm 5.49$ ), while implant stability values of 6 months postoperative ( $81.00 \pm 5.77$ ) showed significant increase when compared to immediate postoperative values ( $p = 0.04$ ), and to 3 months postoperative values ( $p = 0.005$ ).

##### ✚ In group II

Implant stability of 3 months postoperative ( $68.00 \pm 7.94$ ) showed significant decrease ( $p = 0.049$ ) compared to immediate postoperative values ( $74.86 \pm 3.80$ ), while 6 months postoperative values ( $78.71 \pm 3.77$ ) showed significant increase when compared to immediate postoperative ( $p = 0.041$ ), and to three months postoperative values ( $p = 0.001$ ).

##### ✚ In group III

Implant stability of 3 months postoperative ( $73.86 \pm 5.40$ ) showed significant decrease ( $p = 0.002$ ) compared to immediate postoperative values ( $75.43 \pm 5.83$ ), while 6 months postoperative values ( $79.00 \pm 6.68$ ) showed significant increase when compared to

immediate postoperative values ( $p=0.005$ ), and to 3 months postoperative values ( $p= 0.003$ ).

**Table (1):** Assessment of implant stability of the three groups immediate postoperative and along the evaluation intervals shows no significant difference between the studied groups at any time intervals ( $p>0.05$ )

Table 1	Group I		Group II		Group III		P <sup>g</sup>
	Mean	±SD	Mean	±SD	Mean	±SD	
<b>Immediate post operative (PO)</b>	75.14	5.49	74.86	3.80	75.43	5.83	0.97
<b>3M PO</b>	74.00	4.58	68.00	7.94	73.86	5.40	0.14
<b>6M PO</b>	81.00	5.77	78.71	3.77	79.00	6.68	0.7
<b>P<sup>t</sup></b>	0.018*		0.002*		0.013*		
<b>P<sub>i</sub></b>	0.69		0.049*		0.002*		
<b>P<sub>ii</sub></b>	0.04*		0.041*		0.005*		
<b>P<sub>iii</sub></b>	0.005*		0.001*		0.003*		

Data expressed as mean±SD

SD: standard deviation P: Probability \*: significance <0.05

Test used: One way ANOVA for P<sup>g</sup> & Student's t-test (Paired) for P<sup>t</sup>

P<sub>i</sub>: significance between immediate & 3 month PO.

P<sub>ii</sub>: significance between immediate & 6 month PO.

P<sub>iii</sub>: significance between 3 month PO & 6 month PO. P<sup>t</sup>: significance in the same group.

P<sup>g</sup>: significance between the three group.

PO: postoperative.

- **Peri-implant pocket depth (PPD):** As shown in **table 2** there was no significant difference between the studied groups regarding PPD either at 3 months or 6 months postoperative ( $p> 0.05$ ).

- **In the buccal aspect:**

Values of PPD at 6 months postoperative [1.0 (0.0-1.0)] showed no significant difference ( $p= 0.08$ ) when compared to 3 months [1.0 (0.0-1.0)] postoperative within group I, while in group II and III values at 6 months postoperative [2.0 (1.0-2.0) and 1.0 (0.0-2.0) respectively] showed significant increase ( $p=0.025$ ) when compared to 3 months postoperative values [1.0 (0.0-1.0) and 0.0 (0.0-1.0) respectively].

- **In the palatal aspect:**

In group I and III 6 months postoperative values [.0 (0.0-1.0) and 1.0 (0.0-1.0) respectively] showed no significant difference ( $p> 0.05$ ) when compared to 3 months postoperative values [.0 (0.0-1.0) and 0.0 (0.0-1.0) respectively]. While in group II 6 months postoperative values [1.0 (0.0-1.0)] showed significant

increase ( $p= 0.046$ ) when compared to 3 months [.0 (0.0-1.0)] postoperative values.

- **In the mesial aspect:**

In group I and III 6 months postoperative values [1.0 (1.0-2.0) and 1.0 (1.0-2.0) respectively] showed significant increase ( $p=0.025$ ) when compared to 3 months postoperative values [1.0 (0.0-1.0) and 0.0 (0.0-1.0) respectively]. While in group II 6 months postoperative values [1.0 (1.0-2.0)] showed no significant difference ( $p= 0.08$ ) when compared to 3 months [1.0 (1.0-1.0)] postoperative values.

- **In the distal aspect:**

In group II and III 6 months postoperative [1.0 (0.0-1.0) and 1.0 (0.0-2.0) respectively] showed no significant difference ( $p> 0.05$ ) when compared to 3 months postoperative [0.0 (0.0-1.0) and 0.0 (0.0-1.0) respectively]. While in group III there was significant increase at 6 months [1.0 (0.0-1.0)] when compared to 3 months [0.0 (0.0-1.0)] postoperative ( $p= 0.046$ ).

**Table (2):** Assessment of PPD of the studied groups at 3 months and 6 months postoperatively shows no significant difference between the three groups at any time intervals ( $p>0.05$ )

Table 2		Group I		Group II		Group III		P <sup>g</sup>
		Median	Range	Median	Range	Median	Range	
Buccal	3M PO	.0	.0-1.0	1.0	.0-1.0	.0	.0-1.0	0.18
	6M PO	1.0	.0-1.0	2.0	1.0-2.0	1.0	.0-2.0	0.07
	P <sup>t</sup>	0.08		0.025*		0.025*		
Palatal	3M PO	.0	.0-1.0	.0	.0-1.0	.0	.0-1.0	0.8
	6M PO	.0	.0-1.0	1.0	.0-1.0	1.0	.0-1.0	0.082
	P <sup>t</sup>	1.00		0.046*		0.15		
Distal	3M PO	.0	.0-1.0	.0	.0-1.0	.0	.0-1.0	0.4
	6M PO	1.0	.0-1.0	1.0	.0-2.0	1.0	.0-1.0	0.9
	P <sup>t</sup>	0.15		0.08		0.046*		
Mesial	3M PO	1.0	.0-1.0	1.0	1.0-1.0	.0	.0-1.0	0.07
	6M PO	1.0	1.0-2.0	1.0	1.0-2.0	1.0	1.0-2.0	0.4
	P <sup>t</sup>	0.025*		0.08		0.025*		

• **Modified Sulcus Bleeding Index (mSBI):**  
As shown in **table 3** there was no significant difference between different study groups regarding **mSBI** values either at 3 months or 6 months postoperatively ( $p > 0.05$ ).

• **In the buccal aspect**, values at 6 months postoperative showed no significance ( $p > 0.05$ ) when compared to values at 3 months postoperative within group I, II and III.

• Also similar results were shown in **mesial, distal and palatal aspect**.

**Table (3):** Assessment of mSBI of the studied groups at 3 months and 6 months postoperatively shows no significant difference between the three groups at any time intervals ( $p > 0.05$ )

Table 3		Group I		Group II		Group III		P <sup>g</sup>
		Median	Range	Median	Range	Median	Range	
Buccal	3M PO	.0	.0-1.0	.0	.0-1.0	.0	.0-1.0	0.5
	6M PO	.0	.0-1.0	.0	.0-1.0	1.0	.0-1.0	0.19
	P <sup>t</sup>	0.3		0.3		0.08		
Mesial	3M PO	.0	.0-1.0	1.0	.0-1.0	.0	.0-1.0	0.24
	6M PO	1.0	.0-1.0	.0	.0-2.0	.0	.0-1.0	0.3
	P <sup>t</sup>	0.15		0.7		1.00		
Distal	3M PO	.0	.0-1.0	.0	.0-.0	.0	.0-1.0	0.13
	6M PO	.0	.0-.0	.0	.0-1.0	.0	.0-1.0	0.6
	P <sup>t</sup>	0.08		0.3		0.3		
Palatal	3M PO	.0	.0-1.0	.0	.0-1.0	.0	.0-1.0	0.7
	6M PO	.0	.0-1.0	.0	.0-1.0	.0	.0-1.0	0.5
	P <sup>t</sup>	1.00		1.00		0.15		

#### Radiographic result:

1. From the palatal aspect: The relative preoperative bone density showed no significance difference between the three groups ( $p=0.21$ ). The relative postoperative bone density showed significant increase between the three groups ( $p=0.015$ ) as shown in table 4.

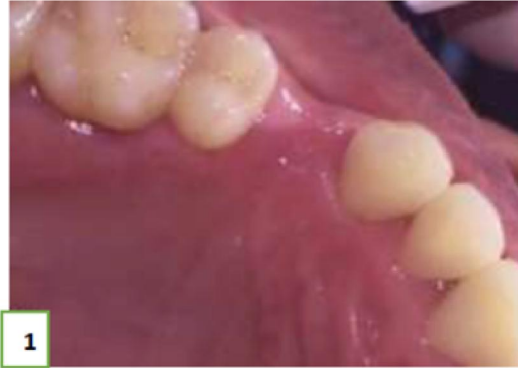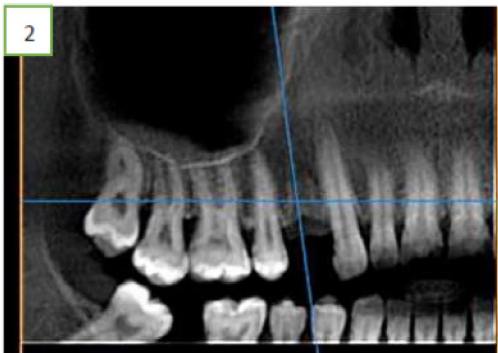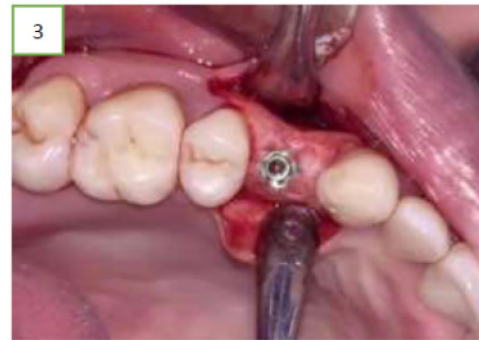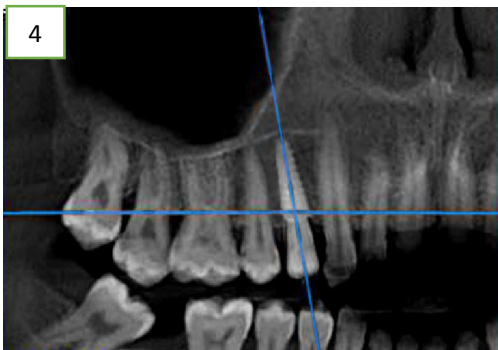
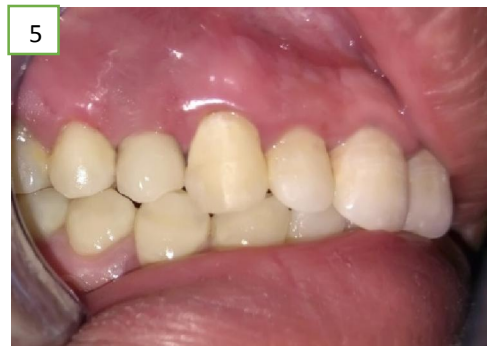2. From the buccal aspect: The relative preoperative bone density showed no significance difference between the three groups ( $p=0.23$ ). The relative postoperative bone density showed significant increase between the three groups ( $p<0.001$ ) as shown in table 5.

**Table (4):** Assessment of palatal bone density of the studied groups preoperative and immediately postoperative.

Palatal aspect		Group I		Group II		Group III		P <sup>g</sup>	P1	P2 P 2	P3
		Mean	±SD	Mean	±SD	Mean	±SD				
Average	Pre operative	312.57	51.28	336.48	85.15	393.76	109.69	0.21			
	Post operative	639.62	128.77	704.86	116.66	846.05	116.33	0.015*	0.58	0.01*	0.1
	P <sup>t</sup>	0.002*		<0.001*		<0.001*					

**Table (5):** Assessment of buccal bone density of the studied groups preoperative and immediately postoperative.

Buccal aspect		Group I		Group II		Group III		P <sup>g</sup>	P1	P2	P3
		Mean	±SD	Mean	±SD	Mean	±SD				
Average	Pre operative	338.00	93.12	324.95	72.76	404.62	100.13	0.23			
	Post operative	540.14	79.99	813.43	221.39	918.67	81.75	<0.001*	0.006*	<0.001*	0.37
	P <sup>t</sup>	0.002*		<0.001*		<0.001*					

**Case presentation of dental implant with progressive threading (group III)****Figure 1:** Occlusal views showing missing 1<sup>st</sup> premolar**Figure 2:** Preoperative CBCT (panoramic view)**Figure 3:** Implant after placement.**Figure 4:** Immediate postoperative CBCT.**Figure 5:** The final restoration.**4. Discussion:**

The clinical success of dental implants depends mainly on the implant becoming osseointegrated with the surrounding bone. Conventional clinical guidelines proposed by Branemark recommended implant placement in healed bony sites, followed by a stress free healing period of 3 to 6 months prior to functional loading.<sup>(15)</sup> However, other clinical protocols such as immediate and early loading protocols have been demonstrated later to decrease the overall treatment period for the benefit of the patients.<sup>(16, 17)</sup>

There is no definitive conclusions about the success rates of implants loaded conventionally compared to immediately or early loaded implants. However, in the English literature, almost no information obtained regarding specific indications as in high-risk conditions, such as the posterior maxilla.<sup>(16)</sup> Therefore, the current study was designed to examine the quality of immediately loaded dental implants in the posterior maxilla with a single tooth replacement.

In the current study, assessment of bone densities were accomplished by comparing the three groups of

patients with immediate loading protocol before the surgery and immediately postoperative. As well as comparing implant stability, PPD and mSBI. The purpose of this study was to allow patients to benefit as soon as possible after surgery also to achieve positive outcomes at the same time. The present study showed that there were no significant statistical differences between the three groups regarding implant stability, PPD and mSBI.

*Gjelvold et al.* have evaluated the clinical outcomes following immediate loading of single tooth implants in the maxillary posterior region and suggested that single implants in the maxilla can achieve satisfactory results which was in agreement with the current study.<sup>(18)</sup>

Immediately loaded implant studies are often founded on implant survival rates. In our study, only one implant failure after one month was recorded in group II (bone expander) and this was because the patient had recent bruxism after implant insertion. This is in agreement with *MA Abdelkarim et al*<sup>(19)</sup> who used bone expander technique but with delayed loading. Fracture of the implant or the superstructure and loss of osseointegration may result from overloading.<sup>(20)</sup>

Regarding implant stability, the present study reported that there was no significant difference between the three groups along the evaluation intervals. This showed that there was no significant change in ISQ over time between the three groups which was in agreement with several studies.<sup>(21, 22)</sup>

In the bone expanders group and the progressive threading implants group there were decrease in the implant stability in the three months follow up period compared to the immediate postoperative one and then increased in the six months follow up period. This may be attributed to the induced fractures of the trabeculae that caused in both bone expander and conventional drilling groups and that requiring remodeling time and delayed secondary implant stability.<sup>(23)</sup>

*Kim and colleagues*<sup>(24)</sup> noted that the values of the primary stabilities of the immediately loaded dental implants placed in the posterior maxilla with single unit restorations, were not predictable for the success of the dental implant. The authors reported that the ISQ values of the 3 immediately loaded implants had primary stability more than 60. Similarly *Atieh and colleagues*<sup>(25)</sup> concluded that the primary stability measurements at the time of implant placement were not accurate to determine the stability of the immediately loaded implant protocols.

To overcome the low prognostic accuracy of RFA at implant placement time, it has been recommended that not only RFA measurement should be considered before immediate implant loading but also it should be combined with other factors such as

clinical parameters, radiographic evaluation, and insertion torque analysis.<sup>(26)</sup>

In this study, for assurance of proper contacts in centric occlusion functional load was applied to the immediate - loaded implants. *Cesaretti and colleagues*<sup>(27)</sup> also used similar technique. They found similar outcomes in posterior maxillary implants when applied functional immediate loading protocol. Similar results were also reported in which a non - functional loading with no occlusal contacts were used.<sup>(28, 29)</sup>

In the current study, in attempt to minimizing the excessive forces, the crowns were delivered within 2 days with light centric occlusion. The values of implant stability of the immediately loaded implants increased during the follow - up visits and at six months postoperatively higher ISQ values were observed. This results in agreement with *Akoglan et al.*<sup>(30)</sup>

Regarding PPD, the results of this study showed that there was statistically significant increase in PPD from 3 months to 6 months postoperatively within each group. However, there was no significant difference between the three groups as regards to the PPD at different time intervals.

In this study, increased PPD values can be attributed to trauma from the surgery and reflecting full thickness mucoperiosteal flaps that leads to a more apically positioned junctional epithelium which is directly related to an increased probing depth around the implant.<sup>(31)</sup> Maximum record in the three groups was 2 mm and this is still in the normal range of periodontal pocket depth (2.5 mm to 4 mm) around the dental implants.<sup>(32)</sup>

In addition, our study reported that there was no significant difference between the three groups regard to the PPD at different time intervals. This is in accordance with *Tsoukaki et al.*<sup>(31)</sup>

Regarding mSBI as a clinical indicator for presence or absence of inflammation, the present study demonstrated that there was no significant difference between the mSBI values of different time intervals of follow up within each group and there were no signs of inflammation, bleeding... etc. detected during the follow up period. Moreover, there was no significant difference between the three groups regarding the mSBI values over the treatment time.

The CBCT has been reported to be a reliable tool of bone density measurement.<sup>(33-35)</sup> Dual energy X-ray absorptiometry (DXA) and quantitative computed tomography (QCT) are typical methods of measuring bone mineral density.<sup>(36)</sup> *Hsu and colleagues,*<sup>(37)</sup> compared the effectiveness of dual-energy x-ray absorptiometry (DXA) and CBCT for assessing cortical bone density and strength in an experimental animal study. They stated that CBCT is accurate for the estimation of cortical bone fracture loads.<sup>(37)</sup>

*Parsa et al.*, compared bone density value in CT and CBCT and demonstrated a high correlation between voxel value of CBCT and CT number in multi slice computed tomography (MSCT).<sup>(38)</sup>

In this study, CBCT was used to assess the change in the bone density from the preoperative CBCT to postoperative one, not the accurate value of bone density and this in agreement with *Elkhidir et al.*, who assured the feasibility of CBCT in evaluating bone density of dental implant placement sites.<sup>(39)</sup>

In this study there was increasing in the peri-implant bone density in the densah bur group along the evaluation intervals. This is in accordance with *Pai et al.*<sup>(23)</sup>

In the bone expanders group, there was increase in bone density from preoperative to postoperative. This was due to bone compaction in lateral and apical directions during preparation of the osteotomy site. This result was in agreement with *Reddy et al.*<sup>(40)</sup>

In this study, bone density assessments were measured in 3 regions (coronal, middle, and apical) in both buccal and palatal sides. By evaluating the average of the aforementioned regions, the effects of progressive threading dental implant and bone expanders technique on peri - implant bone densities were superior to densah bur technique.

The progressive threading design of dental implant increases the bone density as it applies apical and lateral compression to the surrounding bone, which produces a certain amount of osteocompression and also increases the primary stability.<sup>(37, 41, 42)</sup> Based on the results of current study, the bone density increased in the studied groups from the preoperative records to immediate postoperative records without any statistically significant difference between the three groups. This might be due to the bone condensation techniques that had been used. This result was in accordance with *MA Abdelkarim et al.*<sup>(19)</sup> who had only two groups; (conventional drilling group and bone expander group).

The postoperative peri-implant bone density measurements in this research of the crestal and middle regions were higher than that of apical region in the three groups. This might be due to the tapering of the inserted densah bur, bone expander and the progressive dental implants (having higher diameter in cervical and middle part than apical part).

### Conclusion

Bone density measurements increased postoperatively as a result of bone compression around the placed implants, which is important especially in areas of poor bone quality as the posterior maxilla for enhancing the initial implant stability.

The variations in bone density can be accurately detected using CBCT. Therefore, CBCT is reliable to

compare pre-operative and post-operative changes of bone quality during dental implant procedures.

Dental implants with progressive threading were superior in increasing bone density than using densah burs. While there was no difference between using bone expanders and implants with progressive threading regarding increasing bone density.

### References:

1. Friberg B, Jemt T, Lekholm U. Early failures in 4,641 consecutively placed Branemark dental implants: a study from stage 1 surgery to the connection of completed prostheses. *Int J Oral Maxillofac Implants.* 1991 Summer;6(2):142-6.
2. Jemt T, Lekholm U. Implant treatment in edentulous maxillae: a 5-year follow-up report on patients with different degrees of jaw resorption. *International Journal of Oral & Maxillofacial Implants.* 1995;10(3).
3. Norton MR, Gamble C. Bone classification: an objective scale of bone density using the computerized tomography scan. *Clinical oral implants research.* 2001;12(1):79-84.
4. Misch C. Bone character: second vital implant criterion. *Dent Today.* 1988;7(5):39-40.
5. Lekholm U. Patient selection and preparation. *Tissue-integrated prosthesis: osseointegration in clinical dentistry.* 1985:199-209.
6. Javed F, Ahmed HB, Crespi R, Romanos GE. Role of primary stability for successful osseointegration of dental implants: factors of influence and evaluation. *Interventional Medicine and Applied Science.* 2013;5(4):162-7.
7. Blanco J, Suárez J, Novio S, Villaverde G, Ramos I, Segade L, et al. Histomorphometric assessment in human cadavers of the peri - implant bone density in maxillary tuberosity following implant placement using osteotome and conventional techniques. *Clinical oral implants research.* 2008;19(5):505-10.
8. Anitua E. Ridge expansion with motorized expander drills. *Dental Dialogue.* 2004;2:3-14.
9. Huwais S, Meyer EG. A Novel Osseous Densification Approach in Implant Osteotomy Preparation to Increase Biomechanical Primary Stability, Bone Mineral Density, and Bone-to-Implant Contact. *Int J Oral Maxillofac Implants.* 2017 Jan/Feb;32(1):27-36.
10. Lahens BN, R., Tovar NA, A. M. Jimbo, R. Bonfante, E. A. Bowers, M. M. Cuppini, M. Freitas, H. Witek, L. Coelho, P. G. Biomechanical and histologic basis of osseodensification drilling for endosteal implant placement in low density bone. An experimental study in sheep. *J Mech Behav Biomed Mater.* 2016 Oct;63:56-65.



11. Mangano C, Raes F, Lenz C, Eccellente T, Ortolani M, Luongo G, et al. Immediate Loading of Single Implants: A 2-Year Prospective Multicenter Study. *Int J Periodontics Restorative Dent*. 2017 Jan/Feb;37(1):69-78.
12. Han CH, Mangano F, Mortellaro C, Park KB. Immediate Loading of Tapered Implants Placed in Postextraction Sockets and Healed Sites. *J Craniofac Surg*. 2016 Jul;27(5):1220-7.
13. Streckbein P., Kleis W., Buch R. S. R., Hansen T., G. W. Bone healing with or without platelet-rich plasma around four different dental implant surfaces in beagle dogs. *Clinical Implant Dentistry and Related Research*. 2014;16:479-86.
14. Mangano C SJ, Pires JT, Luongo G, Piattelli A, Iezzi G. Early Bone Formation around Immediately Loaded Transitional Implants Inserted in the Human Posterior Maxilla: The Effects of Fixture Design and Surface. *Biomed Res Int* 2017;2017: 4152506.
15. Branemark PI, Hansson BO, Adell R, Breine U, Lindstrom J, Hallen O, et al. Osseointegrated implants in the treatment of the edentulous jaw. Experience from a 10-year period. *Scandinavian journal of plastic and reconstructive surgery Supplementum*. 1977;16:1-132.
16. Esposito M, Grusovin MG, Maghairyeh H, Worthington HV. Interventions for replacing missing teeth: different times for loading dental implants. *Cochrane Database of Systematic Reviews*. 2013(3).
17. Cochran DL, Morton D, Weber HP. Consensus statements and recommended clinical procedures regarding loading protocols for endosseous dental implants. *International Journal of Oral and Maxillofacial Implants*. 2004;19(SUPPL.):109-13.
18. Gjølvdal B, Kisch J, Chrcanovic BR, Albrektsson T, Wennerberg A. Clinical and radiographic outcome following immediate loading and delayed loading of single-tooth implants: Randomized clinical trial. *Clinical implant dentistry and related research*. 2017;19(3):549-58.
19. Abdelkarim MA, Hamed MS, Elsholkamy MA, Abdelmabood AA. Assessment of bone healing around immediately loading dental implants in posterior maxilla with two different osteotomy techniques. *Indian Journal of Multidisciplinary Dentistry*. 2015;5(1):31.
20. Saba S. Occlusal stability in implant prosthodontics-clinical factors to consider before implant placement. *JOURNAL-CANADIAN DENTAL ASSOCIATION*. 2001;67(9):522-7.
21. Manresa C, Bosch M, Echeverria JJ. The comparison between implant stability quotient and bone - implant contact revisited: an experiment in B eagle dog. *Clinical oral implants research*. 2014;25(11):1213-21.
22. Turkyilmaz I, Aksoy U, McGlumphy EA. Two alternative surgical techniques for enhancing primary implant stability in the posterior maxilla: a clinical study including bone density, insertion torque, and resonance frequency analysis data. *Clin Implant Dent Relat Res*. 2008 Dec;10(4):231-7.
23. Pai UY, Rodrigues SJ, Talreja KS, Mundathaje M. Osseodensification—A novel approach in implant dentistry. *The Journal of Indian Prosthodontic Society*. 2018;18(3):196.
24. Kim SJ, Ribeiro AL, Atlas AM, Saleh N, Royal J, Radvar M, et al. Resonance frequency analysis as a predictor of early implant failure in the partially edentulous posterior maxilla following immediate nonfunctional loading or delayed loading with single unit restorations. *Clinical oral implants research*. 2015;26(2):183-90.
25. Atieh MA, Alsabeeha NHM, Payne AGT. Can resonance frequency analysis predict failure risk of immediately loaded implants?. *Int J Prosthodont*. 2012 Jul-Aug;25(4):326-39.
26. Sennerby L, Meredith N. Implant stability measurements using resonance frequency analysis: biological and biomechanical aspects and clinical implications. *Periodontology* 2000. 2008;47(1):51-66.
27. Cesaretti G, Botticelli D, Renzi A, Rossi M, Rossi R, Lang NP. Radiographic evaluation of immediately loaded implants supporting 2–3 units fixed bridges in the posterior maxilla: a 3 - year follow - up prospective randomized controlled multicenter clinical study. *Clinical oral implants research*. 2016;27(4):399-405.
28. Degidi M, Daprile G, Piattelli A. Influence of underpreparation on primary stability of implants inserted in poor quality bone sites: an in vitro study. *J Oral Maxillofac Surg* 2015 Jun;73(6):1084-8.
29. Grandi T, Garuti G, Guazzi P, Tarabini L, Forabosco A. Survival and success rates of immediately and early loaded implants: 12-month results from a multicentric randomized clinical study. *Journal of Oral Implantology*. 2012;38(3):239-49.
30. Akoğlan M, Tatli U, Kurtoğlu C, Salimov F, Kürkçü M. Effects of different loading protocols on the secondary stability and peri - implant bone density of the single implants in the posterior maxilla. *Clinical implant dentistry and related research*. 2017;19(4):624-31.
31. Tsoukaki M, Kalpidis CD, Sakellari D, Tsalikis L, Mikrogiorgis G, Konstantinidis A. Clinical,

- radiographic, microbiological, and immunological outcomes of flapped vs. flapless dental implants: a prospective randomized controlled clinical trial. *Clinical oral implants research*. 2013;24(9):969-76.
32. Coli P, Sennerby L. Is Peri-Implant Probing Causing Over-Diagnosis and Over-Treatment of Dental Implants? *Journal of clinical medicine*. 2019;8(8):1123.
  33. González - García R, Monje F. The reliability of cone - beam computed tomography to assess bone density at dental implant recipient sites: a histomorphometric analysis by micro - CT. *Clinical oral implants research*. 2013;24(8):871-9.
  34. Liu J, Chen H-Y, Do Do H, Yousef H, Firestone AR, Chaudhry J, et al. Efficacy of Cone-Beam Computed Tomography in Evaluating Bone Quality for Optimum Implant Treatment Planning. *Implant dentistry*. 2017;26(3):405-11.
  35. Hsu J-T, Wang S-P, Huang H-L, Chen Y-J, Wu J, Tsai M-T. The assessment of trabecular bone parameters and cortical bone strength: a comparison of micro-CT and dental cone-beam CT. *Journal of biomechanics*. 2013;46(15):2611-8.
  36. Karunanithi R, Ganesan S, Panicker T, Korath MP, Jagadeesan K. Assessment of bone mineral density by DXA and the trabecular microarchitecture of the calcaneum by texture analysis in pre-and postmenopausal women in the evaluation of osteoporosis. *Journal of Medical Physics/Association of Medical Physicists of India*. 2007;32(4):161.
  37. Lan T-H, Du J-K, Pan C-Y, Lee H-E, Chung W-H. Biomechanical analysis of alveolar bone stress around implants with different thread designs and pitches in the mandibular molar area. *Clinical oral investigations*. 2012;16(2):363-9.
  38. Parsa A, Ibrahim N, Hassan B, Motroni A, der Stelt Pv, Wismeijer D. Reliability of voxel gray values in cone beam computed tomography for preoperative implant planning assessment. *International Journal of Oral and Maxillofacial Implants*. 2012;27(6):1438.
  39. Elkhidir Y, Wei S, Suyang L, Xie M, Yang C. Feasibility of CBCT in Evaluating Bone Density of Dental Implant Placement Sites. *RRJDS*. 2017;5:87-91.
  40. Reddy GM, Krishna CV, Lakshmi S, Aditya V, Sekhar NC, Shastry YM. Evaluation of Bone Density Around the Implants Placed Using Drilling Technique and Bone Expansion Technique: An In vivo Study. *The Journal of Indian Prosthodontic Society*. 2014;14(2):172-8.
  41. Abuhussein H, Pagni GR, A. Wang, H. L. The effect of thread pattern upon implant osseointegration. *Clin Oral Implants Res* 2010 Feb;21(2):129-136.
  42. Park J-C, Lee J-W, Kim S-M, Lee J-H. Implant stability-measuring devices and randomized clinical trial for ISQ value change pattern measured from two different directions by magnetic RFA. *Implant Dentistry-A Rapidly Evolving Practice: In Tech Open*; 2011.

7/20/2020