



Hyaluronic Acid Level for assessment of Liver Fibrosis in β -Thalassemia Children Treated for Hepatitis C Virus by Direct Acting Antiviral Drugs

¹Mohamed Mahmoud Yousif Abu-Elazm, ²Eslam El-Sayed El-Hawary, ³Aml Saaid El-Bendary, ⁴Mohiee El-Deen AbdEl-Aziz Awad, and ²Mohamed Ramadan El-Shanshory.

¹Department of Pediatrics, Faculty of Medicine, Tanta University, Egypt.

²Department of Pediatric Hematology, Faculty of Medicine, Tanta University, Egypt.

³Department of Clinical Pathology, Faculty of Medicine, Tanta University, Egypt.

⁴Department of Pediatric Hepatology, Faculty of Medicine, Tanta University, Egypt.

eslam.elhawary@med.tanta.edu.eg

Abstract: Background: Direct acting antiviral drugs (DAAs) (Ledipasvir/Sofosbuvir) can contribute to improvement and prevent progression of liver fibrosis in children with β -thalassemia infected with hepatitis C virus (HCV). Objective: The aim of this study was to assess liver fibrosis by measuring serum hyaluronic acid (HA) in children with β -Thalassemia infected with HCV before and after treatment with DAAs (Ledipasvir / Sofosbuvir). Patients and Methods: 50 children with β -thalassemia, who had chronic HCV infection, aged 12 -18 years, were treated by DAAs for 12 weeks. They were evaluated before and 12 weeks after the end of treatment by PCR for HCV. Liver fibrosis was evaluated before and after treatment by serum HA and Aspartate aminotransferase to platelet ratio index (APRI). Results: Assessment of liver fibrosis with APRI before and after treatment with DAAs demonstrated a statistically significant reduction in the number of patients with severe fibrosis, and redistribution of cases into the less severe classes (P.Value 0.039). There was significant reduction in fibrosis-4 index and serum HA after treatment in comparison to their pretreatment values (P.Value <0.001). Conclusion: HA was reduced together with improved APRI after treatment of HCV infection in children with thalassemia using DAAs, which indicates improvement of liver fibrosis.

[Mohamed Mahmoud Yousif Abu-Elazm, Eslam El-Sayed El-Hawary, Aml Saaid El-Bendary, Mohiee El-Deen AbdEl-Aziz Awad, and Mohamed Ramadan El-Shanshory. **Hyaluronic Acid Level for assessment of Liver Fibrosis in β -Thalassemia Children Treated for Hepatitis C Virus by Direct Acting Antiviral Drugs.** *J Am Sci* 2020;16(6):40-44]. ISSN 1545-1003 (print); ISSN 2375-7264 (online). <http://www.jofamericanscience.org>. 5. doi:[10.7537/marsjas160620.05](https://doi.org/10.7537/marsjas160620.05).

Key words: Hyaluronic Acid, Liver Fibrosis, β -Thalassemia, Hepatitis C Virus, Direct Acting Antiviral Drugs

1. Introduction

Thalassemias is a heterogeneous group of hemoglobin (Hb) synthesis genetic disorders, Considered to be world's most common monogenic disorder (1). In Egypt; Thalassemia is a major health problem since its incidence is estimated as 1000 children/1.5 million live birth per year (2).

Patients with thalassemia may develop liver fibrosis due to iron liver overload and infection with the hepatitis C virus (HCV). Studies have shown that the development and severity of liver fibrosis is strongly associated not only with the extent of the liver iron overload, but also with the presence of chronic HCV infection (3).

In transfusion-dependent thalassemia patients, HCV infection is even considered to be the major risk factor for liver fibrosis, whereas excess liver iron is now clearly recognized as a cofactor for the development of advanced fibrosis in HCV patients (4).

Although hepatic fibrogenesis has long been assumed to be an irreversible process, it is now apparent that it is a dynamic process with considerable potential for reversal; unlike cirrhosis, which is irreversible.

Therefore, treatment of HCV infection and early identification of liver fibrosis would be of great significance (5).

Till 2016, the combination of pegylated interferon- α and ribavirin (PEG-IFN / ribavirin) remained the standard infection therapy for Chronic HCV infection. But due to its extensive list of potential side effects and the high probability of adverse symptoms (6-8), it was often held from use until adulthood.

The United States recently (on April 7, 2017), the first direct-acting antiviral agents (DAAs) for children were approved by the Food and Drug Administration (FDA), which included sofosbuvir

and sofosbuvir / edipasvir to treat HCV in children and adolescents aged 12 years and older (9).

Liver biopsy has long been seen as the gold standard for hepatic fibrosis assessment. However, it is an invasive procedure which can lead to serious complications in many patients, limiting their acceptance and repetition. Furthermore, liver biopsy accuracy may be questioned due to sampling errors and inter-observer variability, which can lead to fibrosis or cirrhosis under or over staging (10). This created a need for the development and validation of non-invasive tests that can accurately represent the full spectrum of hepatic fibrosis, cirrhosis and severity of liver disease (11).

Measuring hepatic fibrosis helps to stage the severity of the disease, and also allows the progression of the disease to be determined in sequence. Additionally, the rate of development of fibrosis is an important indicator of the time to develop cirrhosis. In addition, there is growing proof that fibrosis is reversible; methods would need to test both progression and regression accurately (12).

Hyaluronic acid (HA) is a high-molecular - weight glycosaminoglycan, an integral part of extracellular matrix in nearly every body tissue (13). In the liver, HA is mostly synthesized by hepatic stellate cells and removed the sinusoidal cell adhesion molecules (14). This mechanism is impaired in fibrosis, which results in an increase in serum HA levels. The serum HA is therefore considered to be a marker occurring early before pathological alterations arise (15). In the current study, we evaluated serum hyaluronic acid (HA) as a marker for hepatic fibrosis as it has been reported that there was significant association between serum HA level and degree of liver fibrosis, suggesting that higher HA levels were highly correlated with advanced liver fibrosis stages. The fact that HA has close ties with stellate cells and that stellate cell activation is crucial to the development of hepatic fibrosis has led to the hypothesis that serum HA levels could be associated significantly with fibrosis. Serum HA is regarded as a marker that appears early even before there are advanced pathological changes (16).

2. Patients and Methods

This study was carried out on β -thalassemic children with chronic HCV infection at the Hematology Unit, Pediatric Department, Tanta University Hospital, after approval by the ethical committee of Faculty of Medicine of the University of Tanta. HCV infection was initially diagnosed by serological detection of HCV-Ab then confirmed by polymerase chain reaction (PCR) for HCV RNA in the serum. We recorded 72 children with positive HCV, 18 of them were excluded as they were less

than 12 years old, which is the age of FDA approval for the use of DAAs in children, and two children were excluded due to HBV co-infection. The remaining 52 children were recruited in the study.

They received Ledipasvir (90 mg)/Sofosbuvir (400 mg) DAA therapy; as a single oral tablet for 12 weeks per day., then re-evaluated after another 12 weeks by PCR for HCV RNA to insure sustained viral remission (SVR).

Hyaluronic acid was used as a marker for assessment of hepatic fibrosis before and 12 weeks after the end of treatment using a double antibody enzyme-linked immunosorbent assay (ELISA) sandwich. Another serological marker, Aspartate aminotransferase to platelet ratio index (APRI) was calculated for all our patients before and after DAADs. It was calculated as:

$$\text{APRI} = [\text{AST level} / \text{Upper limit of normal (ULN)}] / \text{Platelet count} (10^9/l) \times 100.$$

An APRI of ≤ 0.5 indicated no significant fibrosis, an APRI of ≥ 1.5 indicated significant fibrosis, while figures in-between were considered inconclusive (17).

We also applied another non-invasive scoring system; Fibrosis-4 score (FIB-4). For advanced fibrosis, the use of a lower cutoff value of 1.45 and FIB-4 score < 1.45 had a negative predictive value of 90 %. By contrast, for advanced fibrosis (18), a FIB-4 score > 3.25 would have a specificity of 97 % and a positive predictive value of 65 %.

3. Results

Of the 52 patients who started the study, two children dropped out; one of them had negative PCR for HCV by the 8th week but did not complete treatment for the rest of the 12 weeks' protocol, and the other one stopped treatment on the second week of therapy and did not show for subsequent doses. The remaining 50 children, completed the study and received treatment for a duration of 12 weeks and were reassessed again 12 weeks after the end of treatment. The mean age of patients who completed this study was 13.38 years (range: 12-18 years), 29 males and 21 females.

A positive HCV PCR at baseline was a prerequisite in 100% of patients, and was repeated for reevaluation after 12 weeks at the end of treatment (EOT), as well as at 12 weeks later. HCV PCR became negative in 100% of patients with SVR.

In pretreatment assessment with APRI, 12 patients had a score < 0.5 (mild fibrosis), 32 patients had a score of 0.5 – 1.5 (moderate fibrosis) and 6 patients had a score > 1.5 (severe fibrosis), whereas after treatment 15 patients had a score < 0.5 (mild fibrosis), 35 patients had a score of 0.5 – 1.5 (moderate fibrosis) and none of them had a score $>$

1.5 (severe fibrosis). This demonstrates a statistically significant reduction in the number of patients with severe fibrosis, and redistribution of larger number of cases into the less severe classes of fibroses (mild and moderate classes) (P.Value 0.039) (**table 1**). The overall APRI values after treatment compared to those before treatment with DAAs, also demonstrated a statistically significant reduction (P.Value <0.001) (**table 2**). There was significant reduction in fibrosis-4 index after treatment in comparison to their

pretreatment values (P.Value <0.001) (**table 3**). Treatment with DAAs led also to significant reduction of serum hyaluronic acid in HCV infected patients in comparison with its pretreatment values for the same patients (P.Value <0.001) (**table 4**).

When we compared APRI values to serum hyaluronic, there was positive significant correlation as regard both pre-treatment and post-treatment value (P.Value <0.001) (**Figure 1 & 2 respectively**).

Table (1) Number of patients with different fibrosis grades by Aspartate transaminase platelet ratio index (APRI) before and after treatment with direct acting antiviral drugs.

APRI	Number of patients		Chi-Square	
	Pre-treatment	Post-treatment	X ²	P.Value
< 0.5 APRI	12 (24 %)	15 (30 %)	6.468	0.039*
0.5-1.5 APRI	32 (64 %)	35 (70 %)		
> 1.5 APRI	6 (12 %)	0		

Table (2) Comparison of aspartate transaminase platelets ratio index (APRI) values before and after treatment with direct acting antiviral drugs.

Time	APRI		Differences	Paired T-Test	
	Range	Mean ± SD	Mean ± SD	t.test	P.Value
Pre-treatment	0.220 - 1.988	0.909 ± 0.459	-0.256 ± 0.251	-7.199	<0.001*
Post-treatment	0.200 - 1.181	0.653 ± 0.264			

Table (3) Comparison of FIB-4 score before and after treatment with direct acting antiviral drugs.

Time	FIB-4 score		Differences		Paired T-Test	
	Range	Mean ± SD	Mean ± SD		t.test	P.Value
Pretreatment	0.12 - 0.98	0.502 ± 0.236	0.076	0.124	4.320	<0.001*
Post treatment	0.11 - 1	0.426 ± 0.194				

Table (4) Comparison of hyaluronic acid before and after treatment with direct acting antiviral Drugs.

Time	Hyaluronic acid (ng/ml)		Differences		Paired T-Test	
	Range	Mean ± SD	Mean ± SD		t.test	P.Value
Pretreatment	31.4 - 226.6	97.762 ± 41.792	-32.05	31.56	-7.181	<0.001*
Post treatment	20.6 - 148	65.71 ± 28.43				

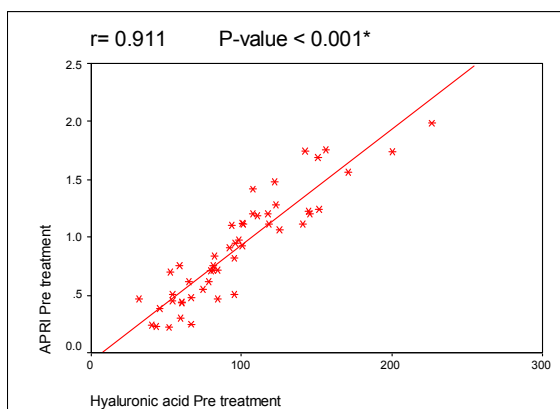


Figure (1) correlation between APRI values and serum hyaluronic acid in patients before treatment with direct acting antiviral drugs.

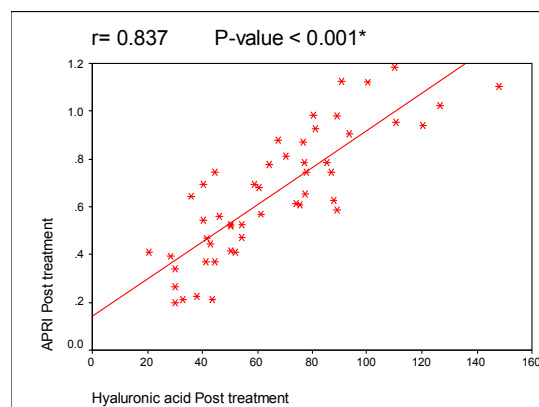


Figure (2) correlation between aspartate platelets ratio index value and serum hyaluronic acid in patients after treatment with direct acting antiviral drugs.

4. Discussion

The significant decrease in APRI values after treatment with DAAs was similar to the previous findings of Elsharkawy et al, who stated that there was significant difference in APRI values after treatment with DAAs when they performed retrospective study including 337 chronic HCV Egyptian patients with genotype 4 mainly who received Sofosbuvir-based treatment regimen (19).

In this study there was significant decrease in frequency of patients with severe degree of liver fibrosis after treatment with DAAs in comparison to pretreatment values. Also, there was significant increase in frequency of patients with mild and moderate degree of liver fibrosis after treatment with DAA in comparison to pretreatment values using APRI values. Similar results were obtained by Shousha et al. who performed a cohort study involving 155 Egyptian CHC patients (20). However, these values should be interpreted cautiously as these findings could be affected by the increased aminotransferase activity induced by exacerbation of inflammation and development of liver fibrosis as a result of HCV-infection in the patients and increased platelets count due to splenectomy and thalassemia itself.

Treatment with DAAs was associated with significant decrease in serum hyaluronic acid in thalassemia patients infected with HCV, this is in agreement with Miyaki et al, who performed a 24-week analysis of thirty patients treated with daclatasvir and asunaprevir and 26 patients obtained SVR, parameters of liver function, markers of serum alanine aminotransferase (ALT) and albumin and liver fibrosis, hyaluronic acid and collagen type IV before and after treatment was completed in SVR and non-SVR patients and showed significant decrease in hyaluronic acid after end of treatment in comparison to pretreatment levels (21).

It has been reported that the combination of HA and aspartate transaminase to platelets ratio index (APRI) in patients with chronic HCV infection allows for the non-invasive detection of patients with higher precision cirrhosis (22, 23). Thus, it was recommended that HA be used as a useful biomarker for monitoring the development of liver disease and the risk of complications in patients with chronic viral hepatitis (24), making it a reliable surrogate marker for the identification of clinically important fibrosis phases.

Conclusion

Since serum HA levels were positively correlated to APRI, which is a well-established indicator of liver fibrosis, HA can be considered to have a good diagnostic accuracy as a non-invasive

fibrosis assessment. Moreover, serum HA measurement in patients with β -thalassemia infected with hepatitis C virus is a non-invasive, accurate and cost-effective method for diagnosing liver fibrosis.

Disclosure

All patients were enrolled after obtaining an informed consent from one of their parents. The study was registered as a clinical trial on ClinicalTrials.gov. (ClinicalTrials.gov Identifier: NCT03961828) as this was the first study to treat chronic HCV infection in children with thalassemia using DAAs.

References

1. Lanzkowsky P. Classification and diagnosis of anemia in children. Lanzkowsky's manual of pediatric hematology and oncology: Elsevier; 2016. p. 32-41.
2. Youssef SM, El Alfy MS, Osman AA, Khattab DA, El Feky MA, and Hussein ME. Rapid Detection of Multiple B-Globin Gene Mutations by a Real-Time Polymerase Chain Reaction in B-Thalassemia Carriers. *The Egyptian Journal of Haematology*. 2012;37(3):147.
3. Di Marco V, Capra M, Gagliardotto F, Borsellino Z, Cabibi D, Barbaria F, et al. Liver Disease in Chelated Transfusion-Dependent Thalassemics: The Role of Iron Overload and Chronic Hepatitis C. *Haematologica*. 2008;93(8):1243-1246.
4. Elalfy MS, Esmat G, Matter RM, Aziz HEA, and Massoud WA. Liver Fibrosis in Young Egyptian Beta-Thalassemia Major Patients: Relation to Hepatitis C Virus and Compliance with Chelation. *Annals of hepatology*. 2013;12(1):54-61.
5. Manning DS, and Afdhal NH. Diagnosis and Quantitation of Fibrosis. *Gastroenterology*. 2008;134(6):1670-1681.
6. Aziz S. Treatment of Hepatitis C Virus Infection in Children Less Than 12 Years of Age in Developing Countries. *Journal of clinical and translational hepatology*. 2014;2(4):247.
7. Suzuki M, Tajiri H, Tanaka Y, Takano T, Miyoshi Y, Murakami J, Shimizu T, and Brooks S. Peginterferon Therapy in Children with Chronic Hepatitis C: A Nationwide, Multicenter Study in Japan, 2004–2013. *Journal of pediatric gastroenterology and nutrition*. 2016;63(1):88-93.
8. Yang CHT, Yoo ER, and Ahmed A. The Role of Direct-Acting Antivirals in the Treatment of Children with Chronic Hepatitis C. *Journal of clinical and translational hepatology*. 2017;5(1):59.

9. FDA. Fda Approves Two Hepatitis C Drugs for Pediatric Patients April 07, 2017. Available from: <https://www.fda.gov/news-events/press-announcements/fda-approves-two-hepatitis-c-drugs-pediatric-patients>.
10. Foucher J, Chanteloup E, Vergniol J, Castera L, Le Bail B, Adhoute X, Bertet J, Couzigou P, and de Lédinghen V. Diagnosis of Cirrhosis by Transient Elastography (Fibroscan): A Prospective Study. *Gut*. 2006;55(3):403-408.
11. Rockey DC, and Bissell DM. Noninvasive Measures of Liver Fibrosis. *Hepatology*. 2006;43(S1):S113-S120.
12. Al Mahtab M, and Akbar SMF. Non-Alcoholic Fatty Liver Disease: A Review. *Journal of Gastroenterology and Hepatology Research*. 2013;2(3):439-444.
13. Halfon P, Bourlière M, Pénaranda G, Deydier R, Renou C, Botta-Fridlund D, Tran A, Portal I, Allemand I, Rosenthal-Allieri A, and Ouzan D. Accuracy of Hyaluronic Acid Level for Predicting Liver Fibrosis Stages in Patients with Hepatitis C Virus. *Comparative hepatology*. 2005;4(1):6.
14. Zheng M, Cai W, Weng H, and Liu R. Determination of Serum Fibrosis Indexes in Patients with Chronic Hepatitis and Its Significance. *Chinese medical journal*. 2003;116(3):346-349.
15. Parise ER, Oliveira AC, Figueiredo - Mendes C, Lanzoni V, Martins J, Nader H, and Ferraz ML. Noninvasive Serum Markers in the Diagnosis of Structural Liver Damage in Chronic Hepatitis C Virus Infection. *Liver International*. 2006;26(9):1095-1099.
16. Orasan OH, Ciulei G, Cozma A, Sava M, and Dumitrascu DL. Hyaluronic acid as a biomarker of fibrosis in chronic liver diseases of different etiologies. *Clujul Medical*. 2016;89(1):24.
17. Boursier J, Vergniol J, Guillet A, Hiriart J-B, Lannes A, Le Bail B, Michalak S5, Chermak F2, Bertrais S, Foucher J, Oberti F, Charbonnier M, Fouchard-Hubert I, Rousselet MC, Calès P, and de Lédinghen V. Diagnostic Accuracy and Prognostic Significance of Blood Fibrosis Tests and Liver Stiffness Measurement by Fibroscan in Non-Alcoholic Fatty Liver Disease. *Journal of hepatology*. 2016;65(3):570-578.
18. Sterling RK, Lissen E, Clumeck N, et al. Development of a simple noninvasive index to predict significant fibrosis in patients with HIV/HCV coinfection. *Hepatology*, 2006; 43(6): 1317-1325.
19. Elsharkawy A, Alem SA, Fouad R, El Raziky M, El Akel W, Abdo M, Tantawi O, AbdAllah M, Bourliere M, and Esmat G. Changes in liver stiffness measurements and fibrosis scores following sofosbuvir based treatment regimens without interferon. *Journal of gastroenterology and hepatology*. 2017;32(9):1624-1630.
20. Shousha HI, Mehassab MK, Mehrez MI, Afifi SA, Elsharkawy M, Hamed M, and Abdelaziz RA. Non-invasive fibrosis scores and liver stiffness changes in chronic hepatitis C after Sofosbuvir-based treatment. *International Journal of Hepatology Gastroenterology*. 2017;3(4):85-90.
21. Miyaki E, Imamura M, Hiraga N, Murakami E, Kawaoka T, Tsuge M, Hiramatsu A, Kawakami Y, Aikata H, Hayes CN, and Chayama K. Daclatasvir and Asunaprevir treatment Improves liver function parameters and reduces liver fibrosis markers in chronic hepatitis C patients. *Hepatology Research*. 2016;46(8):758-764.
22. Neuman MG, Cohen LB, and Nanau RM. Hyaluronic acid as a non-invasive biomarker of liver fibrosis. *Clinical biochemistry*. 2016;49(3):302-315.
23. De Lucca Schiavon L, Narciso-Schiavon JL, and De Carvalho-Filho RJ. Non-invasive diagnosis of liver fibrosis in chronic hepatitis C. *World Journal of Gastroenterology: WJG*. 2014;20(11):2854.
24. Sebastiani G, and Alberti A. How far is noninvasive assessment of liver fibrosis from replacing liver biopsy in hepatitis C? *Journal of viral hepatitis*. 2012;19:18-32.
25. El-Shabrawi MH, El Abedin MYZ, Omar N, Kamal NM, Elmakarem SA, Khattab S, El-Sayed HM, El-Hennawy A, and Ali AS. Predictive accuracy of serum hyaluronic acid as a non-invasive marker of fibrosis in a cohort of multi-transfused egyptian children with B-thalassaemia major. *Arab Journal of Gastroenterology*. 2012;13(2):45-48.