



Over denture Treatment Of Angled Implant With Extended Range Locator Attachment: Clinical Report

Dr. Abdullah Nasser Al-Shehri

Specialist, of Prosthodontic Department, Al-Noor Hospital, K.S.A
ahmedatito69@yahoo.com

Abstract: Proper attachment selection is important considering the patient-related circumstances. This article presents a case where a change in prosthetic attachments was required because implant inclination diminished over denture retention and stability. The treatment involved an alternative implant and soft-tissue impression technique. [Abdullah Nasser Al-Shehri. **Overdenture Treatment Of Angled Implant With Extended Range Locator Attachment: Clinical Report.** *J Am Sci* 2020;16(2):9-15]. ISSN 1545-1003 (print); ISSN 2375-7264 (online). <http://www.jofamericanscience.org>. 2. doi:[10.7537/marsjas160220.02](https://doi.org/10.7537/marsjas160220.02).

Key word: over; denture, locator

Clinical implication

Implant parallelism is rarely achieved, particularly when anatomic limitations are present. The problem of nonparallel implants has been addressed by using bar to compensate for the implant angulation. However, bar attachment as disadvantages in terms of cost, laboratory process, and the maintenance of oral hygiene. In this clinical report, a solution for the management of an inclined implant is presented by using extended range Locator.

Introduction

Overdenture is a dental prosthesis that covers and is partially supported by natural teeth, natural tooth roots, or dental implants. [1] Tooth-supported overdentures have various advantages over conventional complete dentures such as alveolar bone maintenance, preservation of periodontal proprioception, improved retention, stability and support, enhanced psychological comfort, and increased masticatory efficiency. [2] Chen *et al.* observed that the patients treated with tooth-supported overdentures had significantly more comparative masticatory efficiency than those with conventional complete dentures, while there was an insignificant difference in comparative masticatory efficiency between tooth-supported overdentures and implant-supported overdentures. [3,4]

Complete dentures supported by two implants to treat mandibular edentation offers more economic and acceptable results for the patient by enhancing patient comfort, providing adequate support, contributing to retention, and decreasing the number of implants required to fix the prosthesis. [5], [6] Based on previous studies, when two planned implants are placed parallel to each other, the retention is at the

optimal level regardless of the attachment type used. [5], [6], [7] However, in some surgical and anatomical situations, the implants may have to be angled against each other during implant placement. [6], [7] In such cases, many clinicians tend to use angled abutments, flexible attachments, or bar/clips to ensure adequate retention, which further complicates the treatment. [5], [6], [7]

Literature divides connecting systems in rigid or resilient. The rigid ones allow limited torque and improve the angled insertion, while the resilient devices permit various rotation and angulation [4]. Where there are slightly non-parallel implants, a resilient device will decrease the friction, wear and fracture.

When choosing the type of denture attachment, one must take into account the following criteria: the degree of retention available (solidity of implants), adequate restorative space, oral hygiene status, profile height of the device, possibility of reinforcement of the structure, easy application and maintenance and costs. [8]

In cases of major complications with overdentures, including the failure of the prosthesis, it is necessary to adjust or replace the connecting device [9, 10]. This situation can be significantly minimized by appropriate selection of the device in question.

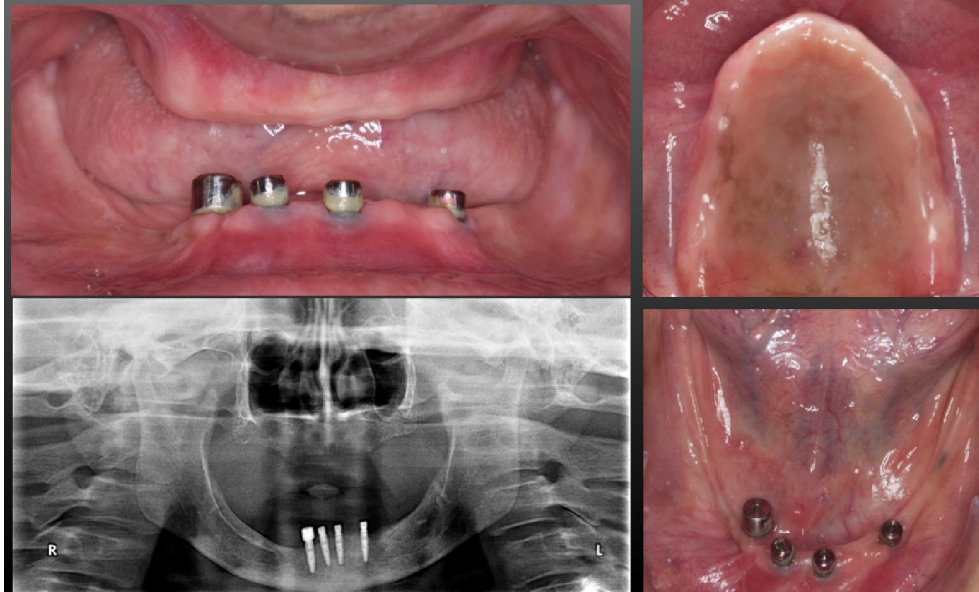
A resilient connection between the prosthesis and implant can reduce the load as far as the degree of movement is achieved at the expense of resilience of the mucosa only. In this way, the greatest part of the occlusal force is thus absorbed directly by the alveolar ridge [11].

Adequate restorative space is another important aspect in the success of overdentures therapy [14].

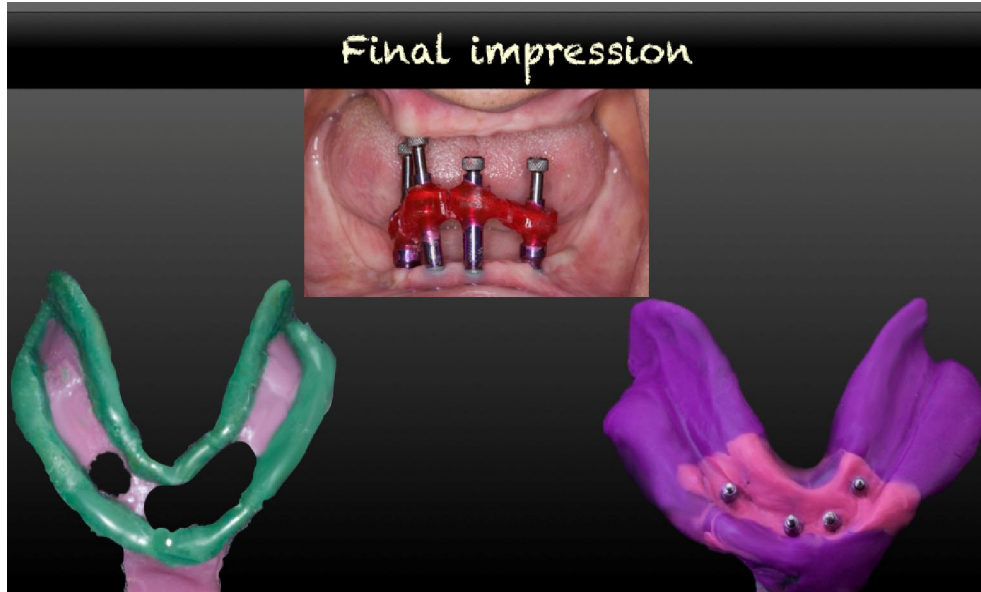Case Report

A 71-year-old woman suffering from unretentive maxillary denture was referred to King Abdulaziz University Hospital Department of Prosthodontics by her private dentist. Intraoral and radiologic

examinations revealed four implant Nobel Biocare system in mandibular arch. (material used in this case type of locator, Nobel Biocare Locator RTX and type of implant Nobel Biocare).



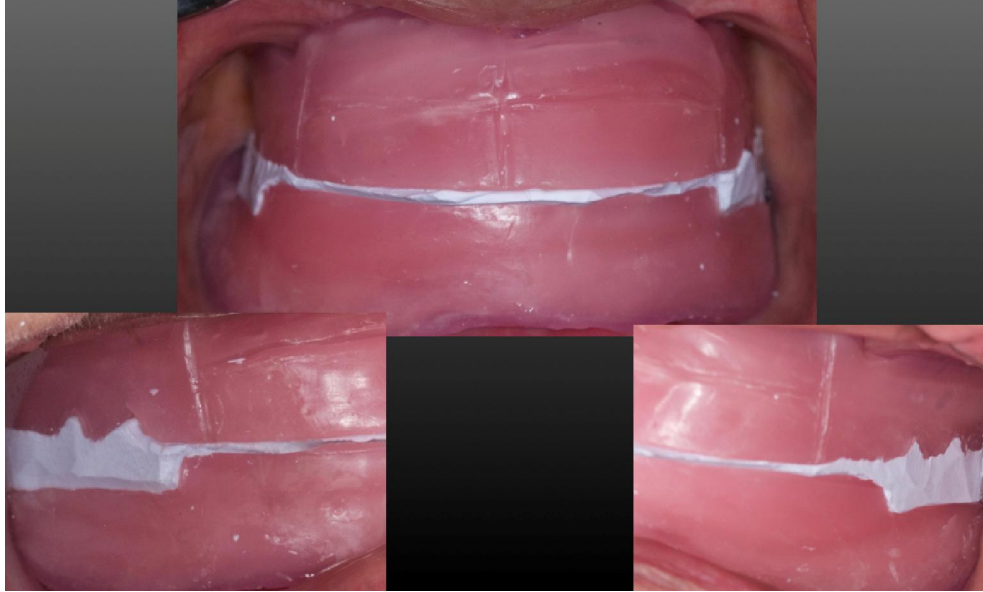A preliminary maxillary impression was made with irreversible hydrocolloid.

**(Mandibular master impression)**

The healing abutments were removed and transfer coping were placed into the implants.

Mandibular impression was also made using elastomeric impression material and a border-molded custom tray.

The impressions then were boxed and poured using Type IV dental stone. Record bases were fabricated with auto polymerizing acrylic resin. Base plate wax was then added to construct occlusion rims.



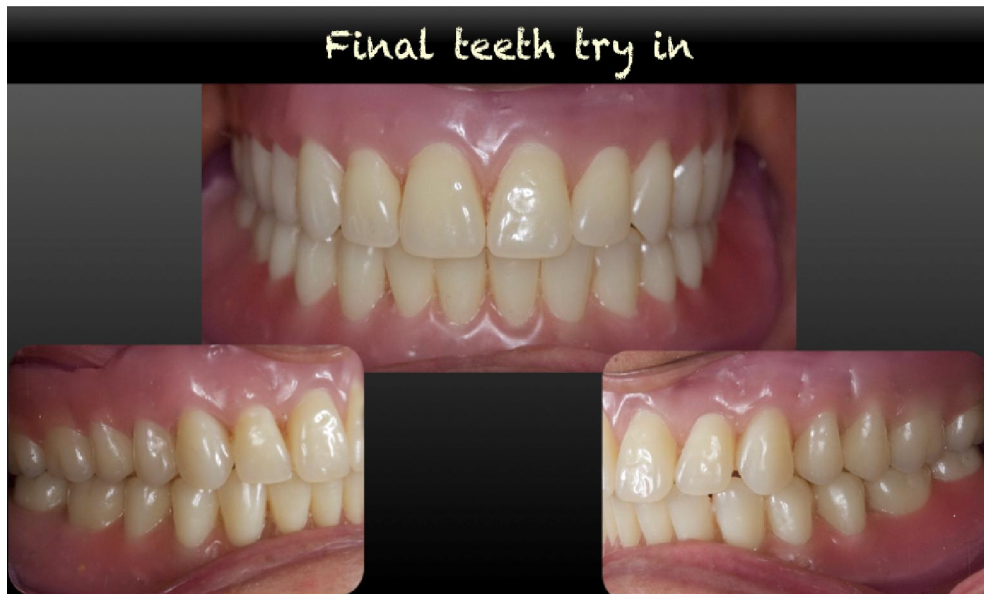(Maxillomandibular relationship– frontal)

The maxillary occlusal rim was tried in the mouth and adjusted for adequate occlusal plane based on patient's phonetics, esthetics, facial tissue support, anatomical landmarks. The mandibular occlusal rim was then aligned with the maxillary rim at appropriate occlusal vertical dimension. The occlusal vertical dimension was determined by using phonetics and

facial measurements taken at the patient's physiologic rest position.

V-shaped indices were cut into the maxillary occlusal rim, and a segment of wax was removed bilaterally from the posterior regions of the mandibular occlusal rim.

A face bow and centric relation use Dowson technique (bimanual manipulation)

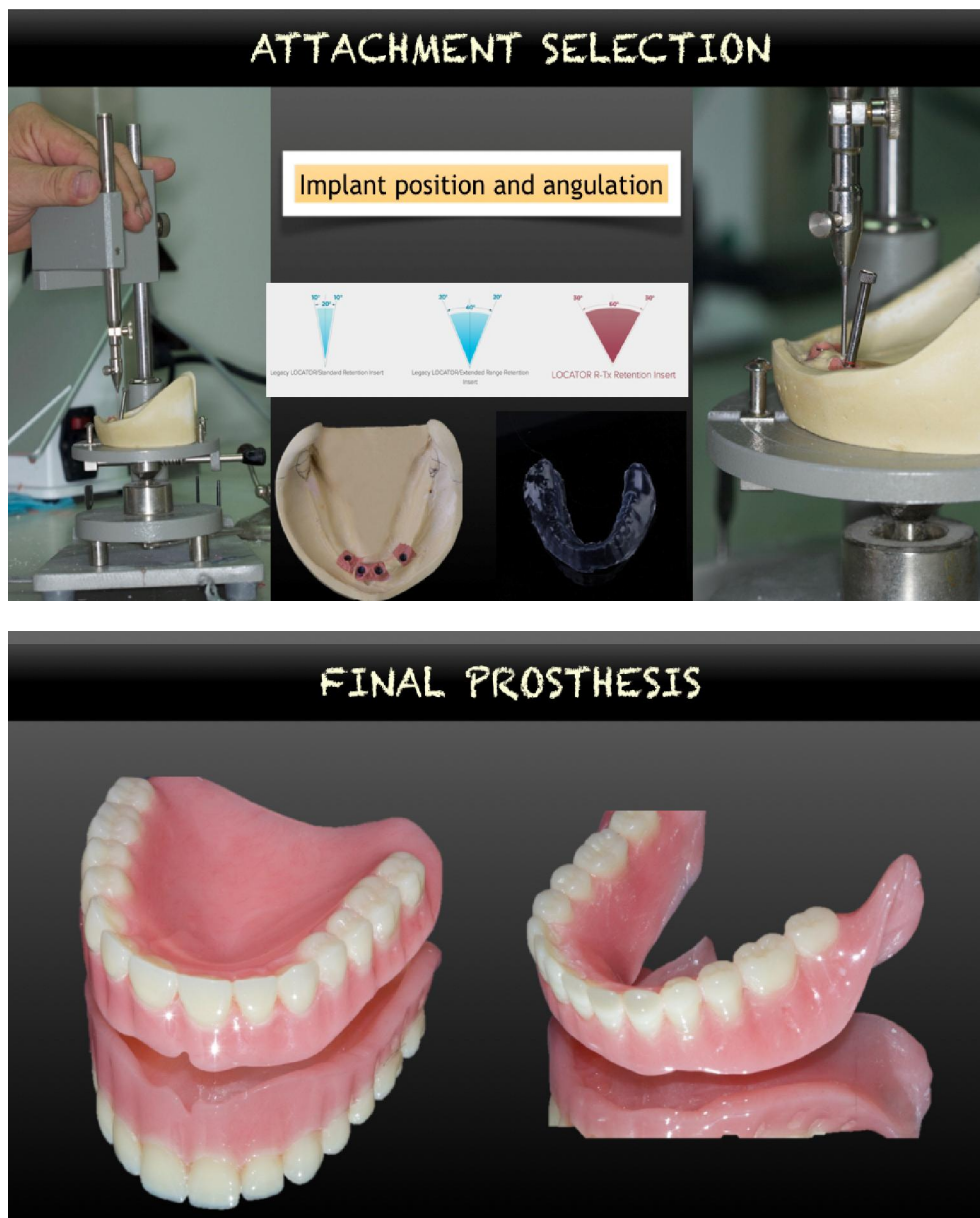

(Wax trial dentures – right lateral)

After completing tooth setup, base plate wax was applied around the denture teeth to provide for a natural mucogingival contour.

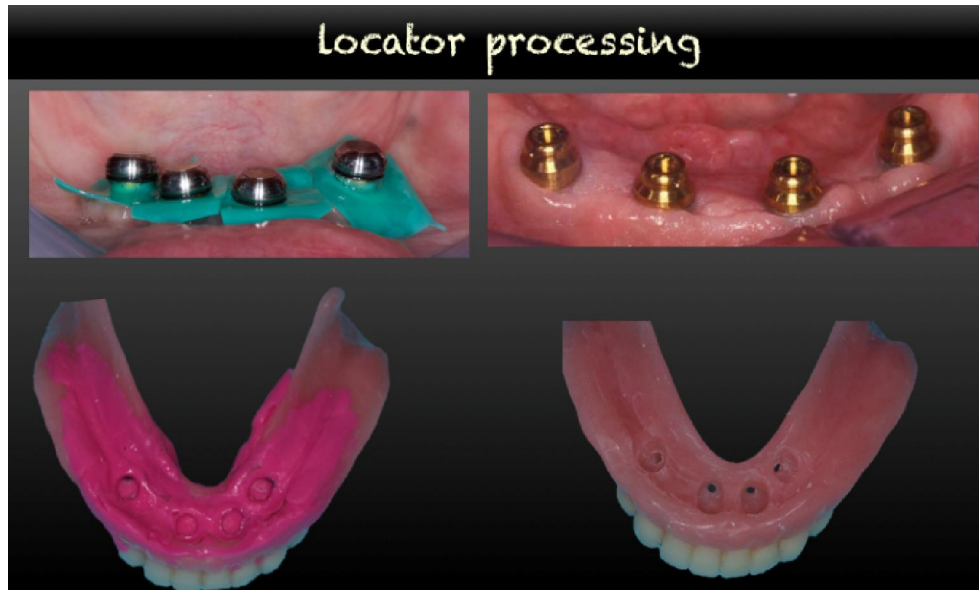
(Wax trial dentures – left lateral)

The wax was smoothed and polished to minimize the need for polishing after processing.

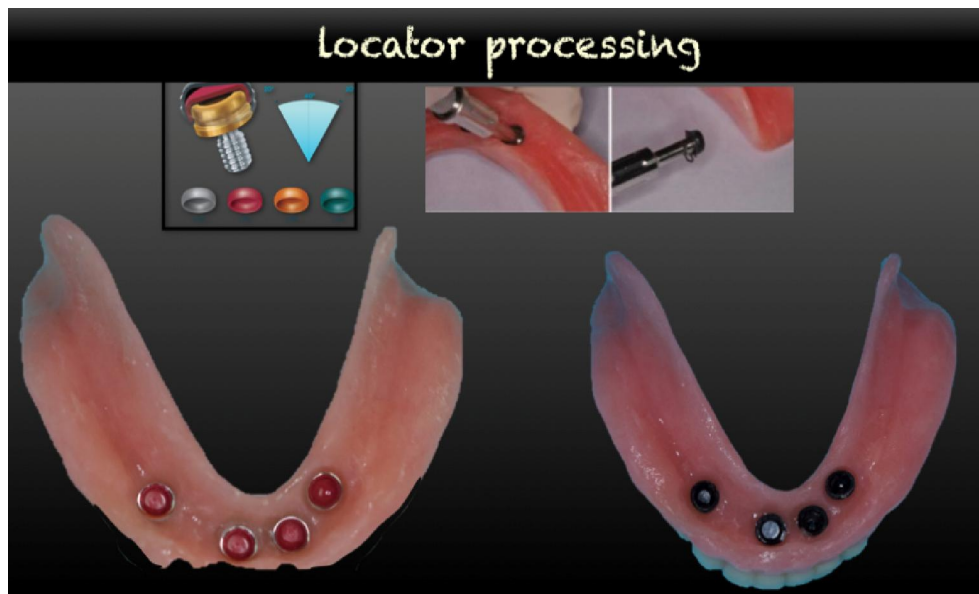


The completed trial dentures were flaked and boiled. After wax elimination, the flasks were packed with heat-activated methyl methacrylate resin, pressed and then processed at 165° F for 9 hours. After

cooling down, the processed dentures were deflashed and remounted on the articulator. Occlusal adjustment was performed on the remounted casts to correct processing errors.



Use an appropriate method to mark the locations of the Locator Abutments on the existing denture
Hollow out the existing denture base in the marked areas for the locator attachments.



Insert the denture into position in the oral cavity. Guide the patient into occlusion, maintaining a proper relationship with the opposing arch. Maintain the denture in a passive condition, without compression of the soft tissue, while the acrylic sets. Excessive occlusal pressure during the setting time may cause tissue recoil against the denture base and could contribute to dislodging and wear of the nylon males.

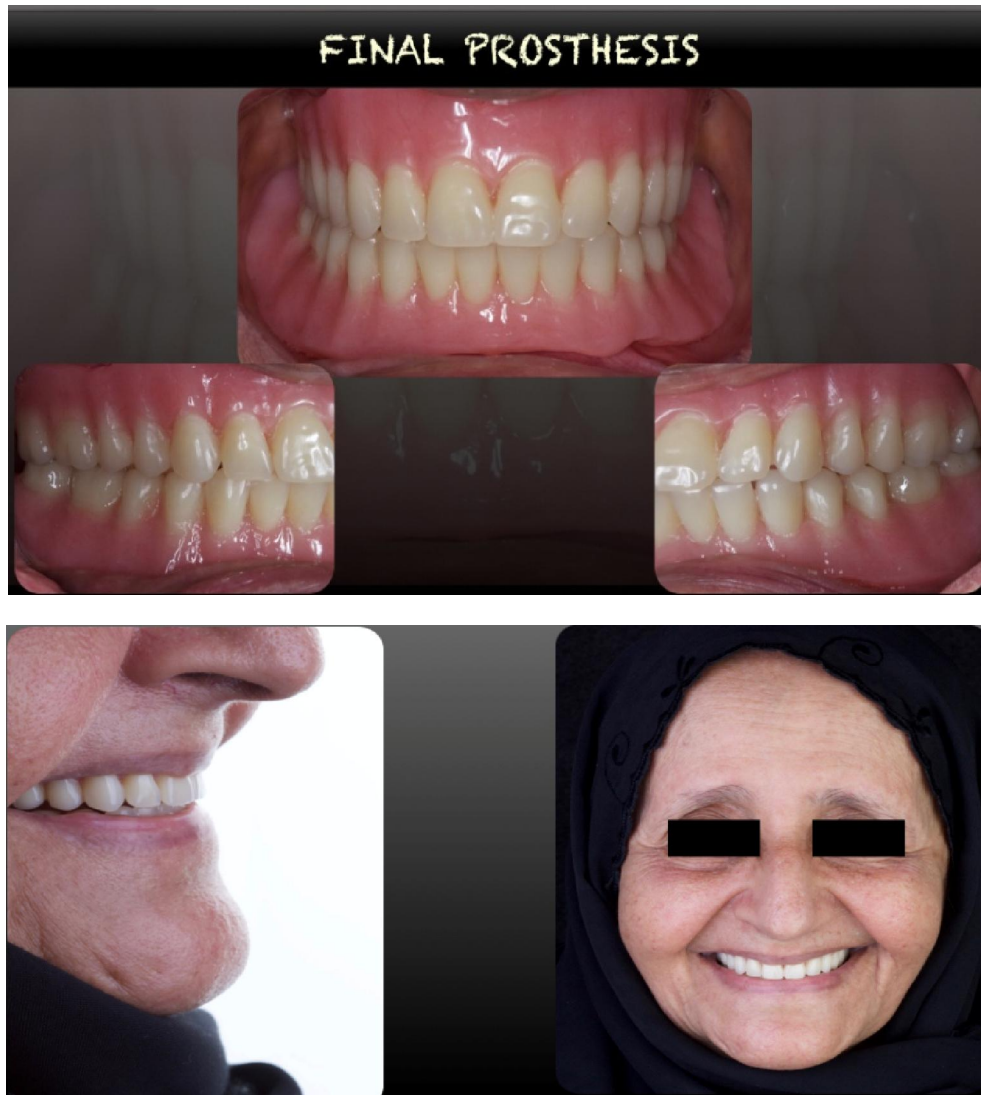
- After the acrylic resin has cured, remove the denture and discard the White Block-Out Spacer.

- Use a bur to remove excess acrylic, and polish the denture base before changing to the final male.

- Select replacement males by considering preferred retention and angle of implant divergence.

- Remove the black processing males from the metal housing using the male removal tool or sickle.

- 6 lbs. of retention per arch total is recommended (two 3.0 lb males, four 1.5 lb males, etc). But always best to start at the lowest level of retention.



Discussion

One of the treatment options to correct severe implant misalignment is to splint the implant abutments for a bar-supported implant overdenture [9]. However, in the patient described in this case study, bar attachment was omitted from the options because of its unfavorable effect on the patient's facial contour.

Compared with the bar/clip attachment overdenture, stud attachments may be less costly, less technique-sensitive, less dependent on implant position, easier to clean and replace, and easier to adjust and control the amount of retention; they may also require less inter arch space and are better able to distribute functional forces [11,12,13].

Restorative space: according to Philips

Minimum space is 8.5 mm for locator.

The locator is required only 10 to 11 mm.

The bar is required 13 to 14 mm.

In this case I use locator instead of bar for tow causes restorative space and cost.

Also I use extended range locator for accommodate the angulation between implant.

Extend range locator can accommodate up to 40 of divergence between implants. The reduced height of the attachment component also provided easy accommodation for misaligned implants. Therefore, this attachment was suitable for the patient. However, long-term prospective studies are required to evaluate the clinical performance of the attachment. [15,16]

Summary

Lack of implant parallelism can challenge a dentist when selecting the proper overdenture attachment system. This article describes the change of the prosthetic attachments because of inclination of

implants, which has caused loss of retention and stability of the denture.

References

1. Allen PF, McKenna G, Creugers N. Prosthodontic care for elderly patients. *Dent Update* 2011;38:460-2, 465-6, 469-70.
2. Chen L, Xie Q, Feng H, Lin Y, Li J. The masticatory efficiency of mandibular implant-supported overdentures as compared with tooth-supported overdentures and complete dentures. *J Oral Implantol* 2002;28:238-43.
3. The glossary of prosthodontic terms: Ninth edition. *J Prosthet Dent* 2017;117:e1-105.
4. Fenton AH. The decade of overdentures: 1970-1980. *J Prosthet Dent* 1998;79:31-6.
5. Gulizio MP, Agar JR, Kelly JR, Taylor TD. Effect of implant angulation upon retention of overdenture attachments. *J Prosthodont* 2005;14:3-11.
6. Feine JS, Carlsson GE, Awad MA, Chehade A, Duncan WJ, Gizani S, et al. The McGill consensus statement on overdentures. Mandibular two-implant overdentures as first choice standard of care for edentulous patients. *Gerodontology* 2002;19:3.
7. Ortegon SM, Thompson GA, Agar JR, Taylor TD, Perdakis D. Retention forces of spherical attachments as a function of implant and matrix angulation in mandibular overdentures: An *in vitro* study. *J Prosthet Dent* 2009;101:2 Shafie HR. *Clinical and Laboratory Manual of Implant Overdenture*.
8. Watson GK, Payne AG, Purton DG, Thomson WM. Mandibular overdentures: comparative evaluation of prosthodontic maintenance of three different implant systems during the first year of service. *Int J Prosthodont*, 2002, 15(3):259–266.
9. Ochiai KT, Williams BH, Hojo S, Nishimura R, Caputo AA. Photoelastic analysis of the effect of palatal support on various implant-supported designs. *J Prosthet Dent*, 2004, 91(5):421–427.
10. Besimo C. *Removable partial dentures on osseointegrated implants: principles of treatment planning and prosthetic rehabilitation in edentulous mandible*, Quintessence Publishing Co., Chicago, IL, 1998.
11. Chaimattayompol N, Arbree NS. Assessing the space limitation inside a complete denture for implant attachments. *J Prosthet Dent*, 2003, 89(1):82–85.
12. Schneider AL, Kurtzman GM. Restoration of divergent free-standing implants in the maxilla. *J Oral Implantol*. 2002;28:113–116.
13. Pasciuta M, Grossmann Y, Finger IM. A prosthetic solution to restoring the edentulous mandible with limited interarch space using an implant-tissue-supported overdenture: a clinical report. *J Prosthet Dent*. 2005;93:116–120.
14. Sadowsky SJ. The implant-supported prosthesis for the edentulous arch: design considerations. *J Prosthet Dent*. 1997;78: 28–33.
15. Menicucci G, Lorenzetti M, Pera P, Preti G. Mandibular implant-retained overdenture: a clinical trial of two anchorage systems. *Int J Oral Maxillofac Implants*. 1998;13:851–856.
16. Wismeijer D, Van Waas MA, Vermeeren JJ, Mulder J, Kalk W. Patient satisfaction with implant-supported mandibular overdentures. A comparison of three treatment strategies with ITI-dental implants. *Int J Oral Maxillofac Surg*. 1997;26:263–267.

2/24/2020