



A rare case of pharyngo-cutaneous fistula after peritonsillar abscess

Ahmed Afifi, MD¹, Hesham Saad, MD², Ahmed M Eldesouky³

¹Ent consultant - KFS GH - faculty of medicine - Cairo University - Egypt

²GIT consultant - KFS Liver institute - Egypt

³Assistant lecturer of Cardio- Thoracic surgery - Alazhar university- Egypt

Abstract: Tonsillitis is a common disease affecting all age groups and has a serious list of complications such as peritonsillar, para and retropharyngeal abscesses but we will discuss a very rare case of pharyngocutaneous fistula as an un common and dangerous complication of peritonsillar abscess and how to deal with it.

[Ahmed Afifi, Hesham Saad, Ahmed M Eldesouky. **A rare case of pharyngo-cutaneous fistula after peritonsillar abscess.** *J Am Sci* 2020;16(2):71-73]. ISSN 1545-1003 (print); ISSN 2375-7264 (online). <http://www.jofamericanscience.org>. 9. doi:[10.7537/marsjas160220.09](https://doi.org/10.7537/marsjas160220.09).

Keywords: rare; case; pharyngo-cutaneous; fistula; peritonsillar; abscess

1. Introduction

Peritonsillar abscess (quinsy) is due to collection of pus in peritonsillar space between the tonsillar capsule and superior constrictor muscle. Peritonsillar abscess usually occurs following acute tonsillitis. Infectious mononucleosis also may lead to quinsy. Rarely, it may occur without any previous history of a sore throat. Other rare causes such as smoking and chronic periodontal disease could also cause quinsy (1), (2).

The certain pathophysiology of peritonsillar abscess still unknown to date. The most accepted theory is that an infection develops in crypta magna spreads beyond the tonsillar capsule, initially causing cellulitis and then developing into abscess formation (1).

Formation of peritonsillar abscesses may be due to infection of the weber glands which is minor salivary glands located in the space just superior to the tonsil in the soft palate and is connected by a duct to the surface of the tonsil (3).

2. Case report:

Male patient aged 50y. presented to the outpatient clinic with high grade fever and sever sore throat. Patient was heavy smoker and has no medical problems. Examination revealed bilateral follicular tonsillitis with mild left peritonsillar abscess. We gave the patient good analgesia and parenteral antibiotic in the form of ampicillin-sulbatam and metronidazole.

After 2 days, fever is resolved, and sore throat improved gradually, and patient gave us a history of coughing purulent sputum. Examination revealed improvement of tonsillitis and indirect 70-degree endoscopic assessment of the larynx revealed frothy

sputum and purulent discharge at left pyriform fossa as in Fig. (1).

We decided to continue medical treatment orally, but after two days patient started to complain of dyspnea and neck swelling increased with swallowing. Examination revealed left neck swelling and surgical emphysema at the left supraclavicular area and left upper chest.

We admit the patient and requested for CT neck which revealed air at the left parapharyngeal space Fig. (2). We suspected presence of pharyngeal fistula and we did GIT endoscopist consultation to rule out fistula. We find the fistula at the left side of parapharyngeal space as shown in Fig. (3) purulent discharge was coming from the fistula so we decided not to close the fistula until improving the patient condition and give aggressive triple parenteral antibiotic till resolving of this sever infection.

We insert a nasogastric tube for feeding but patient still complaining of sever dyspnea. CT chest was done revealing collection and empyema of the left lung Fig. (4). Cardiothoracic consultation done to insert chest tube and about 2 liters of purulent fluid collected in the bottle. Cyto-pathological report for the pleural effusion revealed acute suppurative inflammation with no growth organisms and no malignant cells.

Other investigations done to rule out any systemic disease affecting immunity as diabetes, sputum analysis to rule out TB and other immunological tests and virology but all investigations were negative.

Neck ultrasound, doppler and duplex done revealing collection of fluid at the supraclavicular area

with no thrombosis of the jugular vein or the carotid artery.

After one week, chest tube was removed and left neck swelling and emphysema decreased gradually. X-ray chest was done, and effusion was completely disappeared.

After one week more, we remove the nasogastric tube to assess the fistula and we find spontaneous healing of the fistula as in Fig. (5). Patient started oral feeding as fluid and soft diet for 3 days.

This is a very rare complication of follicular tonsillitis complicated with peritonsillar abscess then parapharyngeal space infection complicated with pharyngo-cutaneous fistula and pleural effusion and emphysema of the left lung.

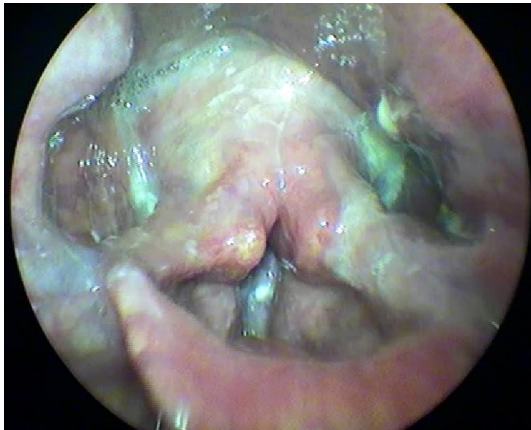


Fig (1): Indirect 70-degree endoscopic assessment of the larynx revealed frothy sputum and purulent discharge at the left pyriform fossa.

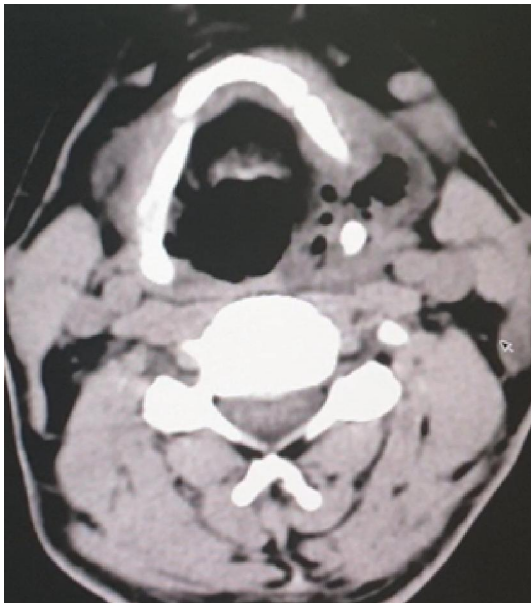

Fig (2): CT neck revealed air at the left parapharyngeal.

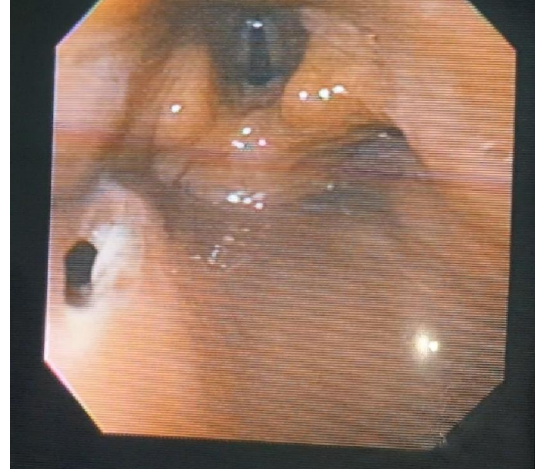


Fig (3): Upper GIT endoscopy revealed fistula at the left side of the hypo-pharynx (parapharyngeal space)

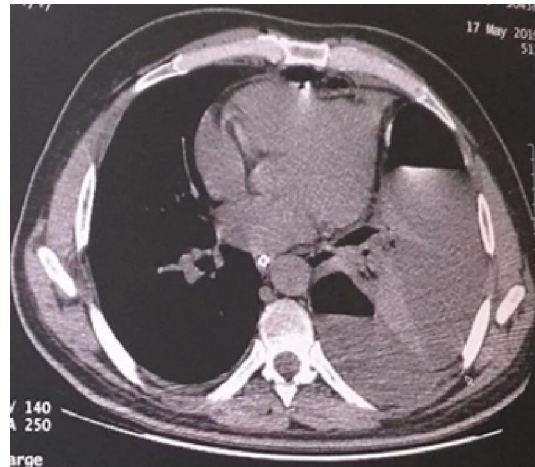


Fig (4): CT chest was done revealing collection and emphysema of the left lung

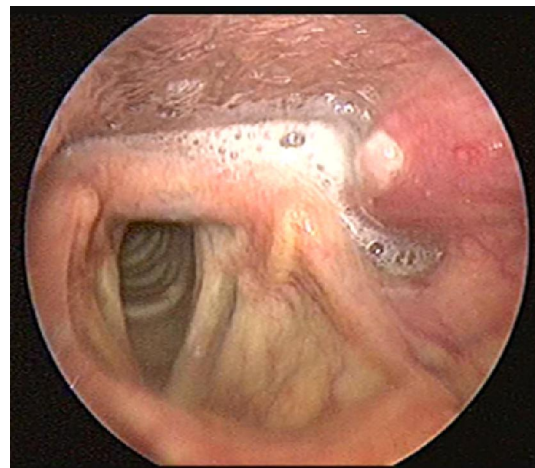


Fig (5): Healing of the fistula with granulation tissue with mild bulge of the left parapharyngeal space.

3. Discussion

Infections of the deep neck spaces present a challenging problem for several reasons. The anatomy of the deep neck spaces is highly complex and can make precise localization of infections in this region difficult. Diagnosis of deep neck infections are difficult because they often are covered by a substantial amount of unaffected superficial soft tissue. Deep neck infections many times are difficult to palpate and to visualize externally (4).

The relevant anatomic structures enclosed in this area (i.e., the carotid sheath, digestive tract, and airway) and continuity of neck spaces within the mediastinum makes this area a “danger zone”. Since this is so, accurate knowledge of the anatomy is essential for the physician to be aware of the possible course that progression of the infection may follow, as well as to plan surgical treatment when necessary (5).

Parapharyngeal space infection which is one complication of peritonsillar abscess is a life-threatening infection can occur. If it is inadequately treated due to upper airway obstruction, abscess rupture with aspiration of pus, or further extension of the infection into the deep tissues of the neck, putting neurologic and vascular structure at risk (6).

Our case is a complicated peritonsillar abscess with parapharyngeal space infection and pharyngo-cutaneous fistula, this rapid progression happened in 50 y. old male which is heavy smoker, diagnosis is revealed after nasopharyngoscopy and CT neck and chest. Decision for conservative treatment first with nasogastric tube, parenteral antibiotic and chest tube were done till healing of the fistula. Improvement of general condition of the patient happened gradually without surgical intervention.

In literature, we found only one paper published in 2014 with pharyngo-cutaneous fistula after tonsillitis but without empyema as our case. In this case the author did a transcervical drainage of the abscess and did gastrostomy (7).

Pharyngo-cutaneous fistula is a common complication after total laryngectomy (8) and neck trauma but is a very rare complication after parapharyngeal space infection and peritonsillar abscess.

Tonsillitis may lead to a life-threatening complication such as pharyngo-cutaneous fistula; this case report informs us about this rare complication and how to deal with it.

References

1. Geißler K, Markwart R, Requardt RP, Weigel C, Schubert K, Scherag A, Rubio I, Guntinas-Lichius O. Functional characterization of T-cells from palatine tonsils in patients with chronic tonsillitis. *PLoS ONE*. 2017;12(9): e0183214.
2. Wikstén J, Kaltiainen E, Pitkäranta A, Blomgren K. Renewal of peritonsillar abscess: Impact of the bacterial species of the infection and clinical features of the patient-A prospective comparative aetiological study. *ClinOtolaryngol*. 2017 Dec;42(6):1358-1362.
3. Powell EL, Powell J, Samuel JR, Wilson JA. A review of the pathogenesis of adult peritonsillar abscess: time for a re-evaluation. *J Antimicrob Chemother*. 2013;68(9):1941-1950.
4. Brito-Mutunayagam S, Chew YK, Sivakumar K, Prepageran N. Parapharyngeal and Retropharyngeal Abscess: Anatomical Complexity and Etiology. *Med J Malaysia Vol 62 No 5 December 2007*.
5. Herzon FS, Martin AD. Medical and surgical treatment of peritonsillar, retropharyngeal, and parapharyngeal abscesses. *Curr Infect Dis Resp*. 2006;8:196-202.
6. Powell J, Wilson JA. An evidence-based review of peritonsillar abscess. *ClinOtolaryngol*. 2012;37(2):136-145.
7. Seneviratne RW, Wickramasinghe A. Pharyngo-cutaneous fistula following drainage of a parapharyngeal abscess; a rare and challenging complication of tonsillitis. *Galle Medical Journal*, Vol 19: No. 2, September 2014;28-29.
8. Busoni M, Deganello A, Gallo O. Pharyngocutaneous fistula following total laryngectomy: analysis of risk factors, prognosis and treatment modalities. *ACTA otorhinolaryngologicaitalica* 2015; 35:400-405.

2/12/2020