



## Regression of Barrett's Esophagus after Nissen fundoplication

Reda Saad; Abd-Allah Hamed; Mohamed Abouzeid and Wadie Boshra

Department of General Surgery, Faculty of Medicine, Ain-Shams University, Cairo, Egypt.  
E-mail: [abouzeid2000@hotmail.com](mailto:abouzeid2000@hotmail.com)

**Abstract:** The frequency of Barrett's esophagus (BE) is elevating, and the treatment is challenging. Antireflux surgery has the prospective to prevent reflux and persuade quiescent mucosa on long term-outcome. This study was conducted on 22 patients having GERD with Barrette's esophagus without dysplasia, who underwent anti-reflux surgery by laparoscope (laparoscopic Nissen fundoplication) at Ain-Shams university hospitals General Surgery Departments (El-DEmerdash and Ain-Shams specialized hospitals) from January 2016 to August 2019, two patients were omitted from the study because they did not adhere to follow up, so the final number was 20 patients, there were 12(60%) males and 8(40%) females with mean age 44 years ( range 28-63 years). Patients were classified according to the level of biopsies into two groups: Group (I) patients with short segment BE, and Group (II) patients with long segment BE. The goal of the work was to assess the impact of Nissen fundoplication on Barrett's esophagus (BE) without dysplasia for patients having long standing Gastro-Esophageal Reflux Disease (GERD) Our results showed that post-operative endoscopy and biopsies in which group I short segment patients showed 70% complete regression, 23% partial regression and 7% with no regression while group II long segment patients showed 28.6% complete regression, 14.3% partial regression and 57.1% with no regression. **Conclusion and recommendation:** Nissen fundoplication causes regression of Barrett's esophagus with better results in short segment disease than those with long segment disease. For patients having long segment Barrett's esophagus (LSBE), we advise to destroy this abnormal segment of Barrett's esophagus using endoscopic mucosal resection (EMR) or endoscopic sub-mucosal resection (ESD) or radiofrequency (RF) to be followed by surgery as these patient may require longer period for their Barrett's esophagus to regress.

[Reda Saad; Abd-Allah Hamed; Mohamed Abouzeid and Wadie Boshra. **Regression of Barrett's Esophagus after Nissen fundoplication.** *J Am Sci* 2019;15(12):109-115]. ISSN 1545-1003 (print); ISSN 2375-7264 (online). <http://www.jofamericanscience.org>. 12. doi: [10.7537/marsjas151219.12](https://doi.org/10.7537/marsjas151219.12).

**Keywords:** Barrett's esophagus, Nissen fundoplication, regression.

### 1. Introduction:

Barrett's esophagus (BE) is considered a metaplastic condition, where normal squamous epithelium lining the lower esophagus is replaced with metaplastic columnar epithelium containing goblet cells (intestinal metaplasia). It results from long standing gastro-esophageal reflux disease (GERD). The length of the columnar epithelium at endoscopy is described using the Prague C (circumferential length) and M (maximal length) criteria. The definition of Barrett's oesophagus is when the maximal segment length is  $\geq 3$  cm called long segment, and when maximal length is  $< 3$  cm is called short segment.<sup>[1]</sup>

Barrett's oesophagus clinical importance is derived from its potential to turn malignant, i.e. esophageal adenocarcinoma (EAC). Surveys suggest 2% prevalence among population mostly in those complaining from GERD.<sup>[2]</sup>

Clinical presentation of Barrett's oesophagus is asymptomatic because the lining of the esophagus adapted to columnar epithelium (metaplasia) to

withstand the reflux and so needs endoscopic examination and histo-pathological confirmation to establish the diagnosis.<sup>[3]</sup>

Most cases of oesophageal adenocarcinoma arise from underlying.

Barrett's metaplasia in which there is a histological progression over time from low grade dysplasia (LGD) to high grade dysplasia (HGD) and subsequent intramucosal and invasive carcinoma (metaplasia edysplasiae carcinoma sequence).<sup>[4]</sup>

Risk factors of GERD include: age, male sex, gastro-oesophageal acid reflux, central obesity and smoking, while risk factors for BE.

(Barrett's Esophagus) include: long duration of GERD, long lasting reflux attack, severity of GERD, hiatus hernia, incompetent cardia, alkaline reflux, male sex, and Caucasian race.<sup>[5]</sup>

As a rule, the principle cause in the pathogenesis of BE is acid reflux<sup>[6]</sup>. On the other hand, formation of metaplastic epithelium, depending on supporting evidences, can be induced by many influencing factors such as the chronic, the distal esophagus

cytokine mediated inflammation and exposure to chemical injuries from acid reflux.<sup>[7]</sup>

Duodenogastro-oesophageal reflux together with high acidity (low pH) and bile acids are responsible for raising the risk of epithelial corrosion and are the cause of BE development as an independent risk factors.<sup>[8]</sup>

Increased exposure to a mixture of bile and acid in patients suffering from GERD was obviously accompanied with advanced GERD illness and appearance of premature EAC.<sup>[9]</sup>

Gastro-esophageal reflux are increased due to failure of the lower esophageal sphincter, which consequently augments a neurohumoral-orchestration induced inflammatory stimulation in the esophagus, concerning nerve cells, fibroblasts and immune cells.<sup>[10]</sup> The neurohumoral response stimulates cellular, functional and genetic alterations resulting in the development of columnar epithelium lined the oesophagus and BE. The dysfunction of the sphincter in the lower part of an esophagus, beside the loosening of its attachments and fixation inside the diaphragm (i.e., hiatal geometry) are to be considered as the etiology of the illness.<sup>[11]</sup>

Accordingly it reasonably to put in our consideration, that efficient anti-reflux surgery in addition to restore the hiatus hernia (hiatal closure) may donate to avoid the progression of BE to tumor, normalize reflux, and even regression of BE to normal epithelium.<sup>[11]</sup>

Anti-reflux operation are required for repairing the failure of the sphincter of the lower esophageal canal and return the normality in the geometry of the diaphragmatic hernia.<sup>[12]</sup> Also, efficient anti-reflux operation guarantee, that patients post-operation not in need to take inhibitor pH drugs such as proton pump, for diminishing the pH of the stomach and of the reflux, to be less in acidity (more alkaline)<sup>[12]</sup>.

#### **Aim:**

To evaluate the effect of Nissen fundoplication on Barrett's esophagus (BE) without dysplasia for patients having long standing Gastro-Esophageal Reflux Disease (GERD)

## **2. Patients and methods:**

This study was conducted on 22 patients having GERD with Barrett's esophagus without dysplasia, who underwent anti-reflux surgery by laparoscope (laparoscopic Nissen fundoplication) at Ain-Shams university hospitals General Surgery Departments (El-Demerdash and Ain-Shams specialized hospitals) from January 2016 to August 2019, two patients were omitted from the study because they did not adhere to follow up, so the final number was 20 patients, there were 12(60%) males and 8(40%) females with mean age 44 years ( range 28-63 years). Follow up was

completed post-operative; a standard questionnaire was used to gather information from patients and record files.

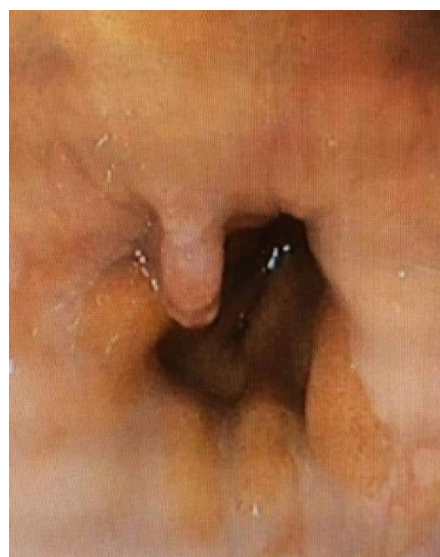Ethical permission for study was obtained from the patients which were fully informed about all the study procedures and their consent approval of local ethical committee of faculty of medicine Ain-Shams University Hospital.

#### **Subject:**

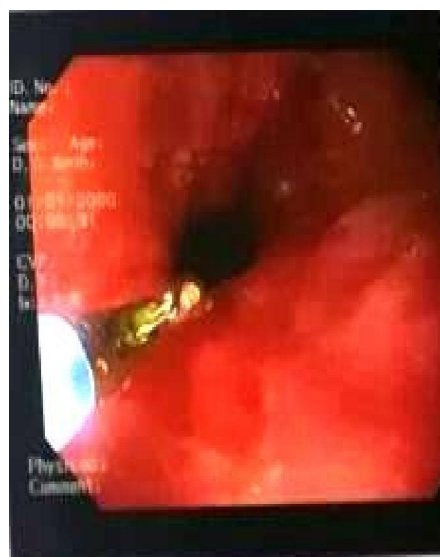Barrette's esophagus patients were classified according to the level of biopsies into two groups:

Group (I): including 13(65%) patients with short segment ranged from 1.8 – 2.7 cm.

Group (II): including 7 (35%) patients with long segment ranged from 3.3 – 5.5 cm.



**Figure (1):** Short segment of Barrett's esophagus



**Figure (2):** Long segment of Barrett's esophagus with biopsy taken

**Inclusion criteria:**

All patients diagnosed with BE by high resolution white light endoscope followed by biopsies **and with no evidence of dysplasia.**

**Exclusion criteria:**

Patients with stricture ulcers, dysplasia and esophageal adenocarcinoma (EAC).

**All patients were subjected to the following:**

1- Detailed present and past history: to determine the signs and symptoms of esophageal reflux (Heart burns- Regurgitation- Dysphagia)

2- Physical examinations

3- Pre-operative upper endoscopy with biopsy according to Seattle protocol (quadrantic biopsies every 2 cm for any mucosal irregularity, except in case of known or suspected dysplasia, every 1 cm quadrantic biopsies should be taken) for histopathological study to diagnose BE.

4- Lab. Investigations: a- CBC b- Renal Function test c- Random blood sugar d- Liver Function test e- Coagulation profile f- Viral marker of HPV and HIV.

5- All patients underwent laparoscopic Nissenfundoplication by standardized procedure as mentioned below.

6- All patients were scheduled for post-operative follow up as follows:

a- After 10 days for stitch removal.

b- Every month in the first 6 months (to assess for symptomatic improvement and post procedural complications as dysphagia and gas bloat syndrome).

7-Standardized questionnaire was taken from all patients by telephone:

a. The severity of typical symptoms of gastroesophageal reflux (Heart burns- Regurgitation- Dysphagia), and its improvement.

b. Post procedural complications (dysphagia, gas bloat syndrome,...etc)

8-Post-operative endoscopy and biopsies were done to assess regression of BE to normal mucosa every 6 months in those patients with long and short segments disease. The endoscopy and biopsies were considered to have complete regression when 2 successive tests were free of BE, otherwise the patients continued to have endoscopy till the end of the study period (3 years and 8 months), and the last result was considered.

**Procedure:**

A standardized technique was used in laparoscopic Nissen fundoplication for all patients as follows:

The patient is sited in a modified lithotomy situation with the head of the table elevated up 25 degrees, and the surgeon is in French position, camera-man on the left side of the patient, while the first assistant is on the right side of the patient.

After preparation and towelings, we use five trocars to enter the abdomen (two 10mm trocars and three 5 mm trocars), one 10 mm trocar is placed in the umbilicus, the second 10 mm trocar is placed in the anterior clavicular line, while the first 5 mm trocars placed right MCL, the second 5mm trocar in the ant axillary line while the last 5mm trocar is placed in the ACL. The procedure begins with the exposure of the esophageal hiatus and dissection of the abdominal segment of the esophagus, then dissection and liberation of the fundus of the stomach via ligation and division of the upper 3-4 short gastric vessels using the Ligasure. Dissection of the right crus of the diaphragm, and identification of hiatus hernia (HH) if present, and repair is done using Ethibond 2-0 (1-3 stitches). After insertion of a 50Fr Maloney bougie, Nissen fundoplication is completed by wrapping the lower esophagus using the dissected free fundus (2-3cm), the wrap should be floppy (not tight).

Finally, the abdomen is explored, hemostasis is assured, and the ports are removed under direct vision.

**3. Results:**

The results of present study were analyzed and summarized as follows:

Table (1) show most of our patients were old with mean age 44.5 years.

**Table (1) Age of studied group:**

	Mean	Range
Age	44.5 years	28-63 years

Table (2) show BE is more common in males (12) than females (8) and two groups in our study Group I Short segment BE with mean 2.27 with range 1.8-2.7cm while Group II Long segment BE with mean 4.3 with range 3.3-5.5cm.

**Table (2) Gender and classification of patients of studied groups:**

Measures	N	%	Mean	Range
Group I Short segment (<3cm)	13	65%	2.27	1.8 – 2.7cm
Group II Long Segment (>3cm)	7	35%	4.32	3.3 – 5.5cm
Male	12	60%		
Female	8	40%		

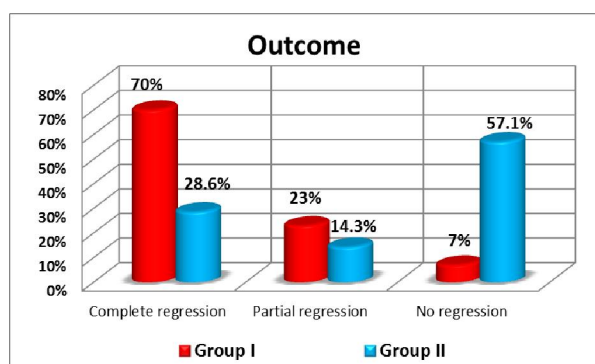
Table (3) show follow-up post-operative endoscopy and biopsies in which group I short segment patients were 70% complete regression, 23% partial regression and 7% with no regression while

group II long segment patients were 28.6% complete regression, 14.3% partial regression and 57.1% with no regression.

**Table (3): Follow up assessment of post-operative outcome.**

Variables	Group I (short) (N = 13)	Group II (long) (N = 7)	Chi-square P-value
Outcome	Complete regression	2 28.6%	$X^2 = 5.99$ P = 0.049
	Partial regression	1 14.3%	
	No regression	4 57.1%	

This table shows statistical significant difference (**p-value < 0.05**) between group I and group II as regard outcome.



**Figure (1): Follow up assessment of post-operative outcome.**

#### 4. Discussion:

Dramatic increase in the frequencies of adenocarcinoma of the esophagus over the past decades was observed. Therefore, there are an urgent need for putting a preventive strategies. [13][14]

Generally, gastroesophageal reflux disease (GERD) is supposed to be accountable for higher than 60% of adenocarcinomas of the esophagus, while patients suffering from week symptoms of reflux are identified to have a 7-fold amplified risk for formation adenocarcinoma. [15] Approximately 12% of patients complaining from chronic GERD grow mucosal metaplasia hence it called Barrett's esophagus (BE) which is, via low- and high-grade dysplasia, associated with an up to 125-fold increased risk for esophageal adenocarcinoma. [16,17] BE, is the only known precursor for esophageal adenocarcinoma. [18,19]. Anti-reflux surgery can be expected to disrupt the pathway of BE and with this the development of esophageal adenocarcinoma. (Sebastian et al. [20])

DeMeester [21] proposed the following goals of surgical therapy for Barrett's esophagus (BE): (1) prevent duodenal reflux and acid to reach the

esophagus; (2) Symptomatic treatment of gastroesophageal reflux disease (GERD); (3) avoid the advancement of reflux complications; (4) discontinue an enlargement in the length of intestinal metaplasia; (5) persuade relapse of intestinal metaplasia to cardiac mucosa; and (6) stop advancement to dysplasia [1]. Briefly, surgical approach should perfectly be capable to discontinue GERD (and manage the symptoms), stop BE and so cease the progression to esophageal cancer.

This study was conducted on 20 patients having GERD with Barrette's esophagus who underwent anti-reflux surgery by laparoscopic trans abdominal Nissen fundoplication at Ain-Shams university hospitals General Surgery Departments (El-DEmerdash and Ain-Shams specialized hospitals) from January 2016 to August 2019, were (12) males and (8) females with mean age 44 years ( range 28-63 years). Follow up was completed post-operative; a standard questionnaire was used to gather information from patients and record files.

The aim of our study to evaluate the effect of Nissan fundoplication on patient having GERD with Barrette's esophagus (both short and long segments) without dysplasia.

The Age of our patients ranged from 28 – 63 years with mean 44 years with 12 males (60%) and 8 females (40%) and this agreed with David 2016 who found that BE is twice as common in men as in women, and prevalence rises with age, [1]it would seem that men with Barrette's esophagus progress to cancer at about twice the rate of women. [22][23]

This agree with Wayne et al [24]. There were 66 male patients and 19 female patients with a median age of 46 years (range 15–76).

Endoscopic pre-operative and biopsies classify our patient into 65% short segment and 35% long segment, endoscopic post-operative follow up occur within 3 years through regular visit to general

surgical department and questioner this in accordance with Australian guide lines.<sup>[25]</sup>

Our results show that “no regression” occurred in long segment more than short segment, 4 cases (57.1%) and 1 case (7%) respectively and this agrees with **Pohl et al.**<sup>[26]</sup> who found that Clinical features accompanied with high rates of advancement comprise elongation in the length of segment, and the presence of nodules, ulceration and strictures on endoscopy.<sup>[22,27,28]</sup>

Current meta-analysis established that prolonged gastro-oesophageal reflux symptoms increased more than five folds the risks of long segment Barrett’s oesophagus.<sup>[29]</sup>

Our results revealed that 93% with regression (70% complete +23% partial) for short segment patients and 42.9% with regression (28.6% complete +14.3% partial) for long segment patients, revealing statistically significant difference between the two groups in regression outcome.

In this study endoscopic post-operative result for complete regression showed no columnar-lined esophagus was found at endoscopy but no intestinal metaplasia or dysplasia is seen histologically, while partial regression showed small islands of intestinal metaplasia in between normal mucosa.

**Sebastian et al.**<sup>[20]</sup> findings agreed with us showing that there exists a rapidly growing evidence that, in addition to the elimination GERD symptoms, anti-reflux surgery contributes to prevent the progression of BE to cancer.

This agree with **Wayne et al**<sup>[24]</sup> median follow-up of 5 years who showed that anti-reflux surgery prevent progression to more advanced mucosal injury or dysplastic changes; and induce regression of dysplastic to nondysplastic Barrett’s or of intestinalized to non-intestinalized columnar epithelium.

Some authors<sup>[30]</sup> found symptomatic outcome in 50 patients with long- and short-segment Barrett’s esophagus. Mean scores for heartburn, regurgitation, and dysphagia all improved dramatically after the Nissen fundoplication in patients with Barrett’s esophagus at 1 to 3 years after surgery.

Protective impact of antireflux operation against advance of tumor and the rate of regression of BE post operation is significantly increased than with medical treatment continuation<sup>[31]</sup>. In addition, many surgeons postulated that antireflux surgery is accompanied with deterioration of Barrett esophagus and/or dysplasia.<sup>[32]</sup>

Many studies including large number of population have recorded significantly lower progression rates for subjects with uncomplicated Barrett’s oesophagus, congregating at about 1-3 per

1000 patients/year (an order of magnitude lower than former results).<sup>[33,34]</sup>

Our result are in agreement with many other studies<sup>[35,36, 37]</sup> in which we analyzing the impact of anti-reflux operation in BE patients, the findings of a meta-analysis in addition to subgroup analysis of a newly published cohort study from UK comprising more than 28,000 BE patients, after anti-reflux surgery show reduced risk of EAC for patients.

Furthermore, when medical therapy has failed the patients are directed to perform anti-reflux surgical operation. Usually, the patients admitted for surgery are at progressive stage of the illness, i.e., severe inflammation in the esophagus, wide hiatal hernia, long duration of GERD symptoms, dysfunction of the sphincter and esophageal transport function, long segments of columnar lined esophagus ( $\pm$  BE), and abnormal reflux monitoring. It is of important to communicate and alternate the knowledge between the gastroenterologist and the surgeon for explanation and identification of those patients who assistance from early intervention before development to tumor, therefore early intervention in the course of the illness in order to reduce the risk for tumor development.<sup>[20]</sup>

## 5. Conclusion and recommendation:

In fact Nissen fundoplication causes regression of Barrett’s esophagus in considerable number of BE patients, with better results in short segment disease than those with long segment disease. For patients having long segment Barrett’s esophagus (LSBE), we advise to destroy this abnormal segment of Barrett’s esophagus using endoscopic mucosal resection (EMR) or endoscopic sub-mucosal resection (ESD) or radiofrequency (RF) to be followed by surgery as these patient may require longer period for their Barrett’s esophagus to regress.

## References:

1. David C Whiteman, Bradley J Kendall Barrett’s oesophagus: epidemiology, diagnosis and clinical management MJA 205 (7) j 3 October 2016.
2. Chen Z, Thompson SK, Jamieson GG, et al. Effect of sexon symptoms associated with gastroesophageal reflux. Arch Surg 2011; 146: 1164-1169.
3. Kendall BJ, Whiteman DC. Temporal changes in the endoscopic frequency of new cases of Barrett’s esophagus in an Australian health region. Am J Gastroenterol 2006; 101: 1178-1182.
4. Corley DA, Kubo A, Levin TR, et al. Race, ethnicity, sex and temporal differences in Barrett’s oesophagus diagnosis: a large

- community-based study, 1994e2006. *Gut* 2009; 58: 182-188.
5. Gordon LG, Eckermann S, Hirst NG, et al. Healthcare resource use and medical costs for the management of oesophageal cancer. *Br J Surg* 2011; 98: 1589-1598.
  6. Inadomi J, Alastal H, Bonavina L, et al. Recent advances in Barrett's esophagus. *Ann N Y AcadSci* 2018. [Epub ahead of print].
  7. Dunbar KB, Agoston AT, Odze RD, et al. Association of Acute Gastroesophageal Reflux Disease With Esophageal Histologic Changes. *JAMA* 2016;315:2104-12.
  8. Farré R, Fornari F, Blondeau K, et al. Acid and weakly acidic solutions impair mucosal integrity of distal exposed and proximal non-exposed human oesophagus. *Gut* 2010;59:164-9.
  9. Stein HJ, Feith M, Feussner H. The relationship between gastroesophageal reflux, intestinal metaplasia and adenocarcinoma of the esophagus. *Langenbecks Arch Surg* 2000;385:309-16.
  10. Rieder E, Riegler M, Simic AP, et al. Alternative therapies for GERD: a way to personalized antireflux surgery. *Ann N Y AcadSci* 2018. [Epub ahead of print].
  11. Schwameis K, Nikolic M, Castellano DGM, et al. Crural Closure improves Outcomes of Magnetic Sphincter Augmentation in GERD patients with Hiatal Hernia. *Sci Rep* 2018;8:7319.
  12. McDonald SA, Lavery D, Wright NA, et al. Barrett oesophagus: lessons on its origins from the lesion itself. *Nat Rev Gastroenterol Hepatol* 2015;12:50-60.
  13. Davies AR, Gossage JA, Zylstra J, et al. Tumor stage after neoadjuvant chemotherapy determines survival after surgery for adenocarcinoma of the esophagus and esophagogastric junction. *J ClinOncol* 2014;32:2983-90.
  14. Gupta V, Coburn N, Kidane B, et al. Survival prediction tools for esophageal and gastroesophageal junction cancer: A systematic review. *J Thorac Cardiovasc Surg* 2018;156:847-56.
  15. Pandeya N, Webb PM, Sadeghi S, et al. Gastro-oesophageal reflux symptoms and the risks of oesophageal cancer: are the effects modified by smoking, NSAIDs or acid suppressants? *Gut* 2010;59:31-8.
  16. Peng S, Huo X, Rezaei D, et al. In Barrett's esophagus patients and Barrett's cell lines, ursodeoxycholic acid increases antioxidant expression and prevents DNA damage by bile acids. *Am J Physiol Gastrointest Liver Physiol* 2014;307:G129-39.
  17. Sharma P. Clinical practice. Barrett's esophagus. *N Engl J Med* 2009;361:2548-56.
  18. Kristo I, Asari R, Rieder E, et al. Treatment of Barrett's esophagus: update on new endoscopic surgical modalities. *Minerva Chir* 2015;70:107-18.
  19. Spechler SJ, Souza RF. Barrett's esophagus. *N Engl J Med* 2014;371:836-45.
  20. Schoppmann SF, Kristo I, Riegler M. Does anti-reflux surgery disrupt the pathway of Barrett's esophagus progression to cancer? *Transl Gastroenterol Hepatol* 2018;3:101.
  21. DeMeester SR (2015) Barrett's oesophagus: treatment with surgery. *Best Pract Res ClinGastroenterol* 29(1):211-217.
  22. Bhat S, Coleman HG, Yousef F, et al. Risk of malignant progression in Barrett's esophagus patients: results from a large population based study. *J Natl Cancer Inst* 2011; 103: 1049-1057.
  23. Bani-Hani KE, Bani-Hani BK, Martin IG. Characteristics of patients with columnar-lined Barrett's esophagus and risk factors for progression to esophagealadenocarcinoma. *World J Gastroenterol* 2005; 11:6807-6814.
  24. Wayne L, Hofstetter, Jeffrey H. Peters, et al: Long-Term Outcome of Antireflux Surgery in Patients With Barrett's Esophagus *ANNALS OF SURGERY* Vol. 234,2001No. 4, 532-539.
  25. Whiteman DC, Appleyard M, Bahin FF, et al. Australian clinical practice guidelines for the diagnosis and management of Barrett's esophagus and earlyesophageal adenocarcinoma. *J Gastroenterol Hepatol* 2015; 30: 804-820.
  26. Pohl H, Pech O, Arash H, et al. Length of Barrett's oesophagus and cancer risk: implications from a large sample of patients with early oesophagealadenocarcinoma. *Gut* 2016; 65: 196-201.
  27. Coleman HG, Bhat S, Johnston BT, et al. Tobacco smoking increases the risk of high-grade dysplasia and cancer among patients with Barrett's esophagus. *Gastroenterology* 2012; 142: 233-240.
  28. Kastelein F, Spaander MC, Biermann K, et al. Nonsteroidal anti-inflammatory drugs and statins have chemopreventative effects in patients with Barrett's esophagus. *Gastroenterology* 2011; 141: 2000-2008; quiz e2013-2004.
  29. Taylor JB, Rubenstein JH. Meta-analyses of the effect of symptoms of gastroesophageal reflux on the risk of Barrett's esophagus. *Am J Gastroenterol* 2010; 105:1729-1737; quiz 1738.

30. Farrell TM, Smith CD, Metreveli RE, et al. Fundoplication provides effective and durable symptom relief in patients with Barrett's esophagus. *Am J Surg* 1999; 178:18–21.
31. Allaix ME, Patti MG (2015) Antireflux surgery for dysplastic Barrett. *World J Surg* 39(3):588–594. <https://doi.org/10.1007/s00268-014-2632-x>.
32. Chang EY, Morris CD, Seltman AK, O'Rourke RW, Chan BK, Hunter JG, Jobe BA (2007) The effect of antireflux surgery on World J Surgesophageal carcinogenesis in patients with Barrett esophagus: a systematic review. *Ann Surg* 246(1):11–21.
33. Tse WHW, Kroon HM, van Lanschot JJB (2017) Clinical challenges in upper gastrointestinal malignancies after bariatric surgery. *Dig Surg*. <https://doi.org/10.1159/000477267>.
34. Patti MG, Arcerito M, Feo CV, Worth S, De Pinto M, Gibbs VC, Gantert W, Tyrrell D, Ferrell LF, Way LW (1999) Barrett's esophagus: a surgical disease. *J Gastrointest Surg* 3(4):397–403.
35. Lagergren J, Ye W, Lagergren P, et al. The risk of esophageal adenocarcinoma after antireflux surgery. *Gastroenterology* 2010;138:1297-301.
36. Wiseman EF, Ang YS. Risk factors for neoplastic progression in Barrett's esophagus. *World J Gastroenterol* 2011;17:3672-83.
37. Löfdahl HE, Lu Y, Lagergren P, et al. Risk factors for esophageal adenocarcinoma after antireflux surgery. *Ann Surg* 2013;257:579-82.

11/23/2019