



Protection against lung toxicity induced by Amiodarone in Albino rats by fish oil

Naglaa A. S. Sarg and Kamal M. Kamal

Anatomy & Embryology Department Faculty of Medicine, Benha University, Egypt
naglasarg@hotmail.com

Abstract: Background: Amiodarone (AD) is a strong anti-arrhythmic drug but has adverse reactions on different organs. Fish oil which is rich in Omega-3 polyunsaturated fatty acids (omega-3 PFAs). **Aim of the study:** to study the toxicity of Amiodarone on Albino rat lungs and its withdrawal. It also study the possible protective role of fish oil. **Materials and Methods:** 32 adult male Albino rats were randomly classified into four equal groups. **Group I** was kept as control group, **group II**, administered Amiodarone in a daily dose of 30 mg/kg BW; **Group III:** Received Amiodarone for 6 weeks; stopped for another 6 weeks then the rats were sacrificed. **Group IV:** Given a daily doses of Amiodarone (30 mg/kg BW) with fish oil 150mg/kg BW. Lungs were prepared for histopathological and Immunohistochemical study. Estimation of oxidative markers ((MDA-SOD- GSH) was done. **Results:** Light microscopical examination of Group II showed distorted pulmonary architecture. Withdrawal of Amiodarone showed very minimal improvement of lung architecture. Group IV showed more or less normal pulmonary architecture with significant decrease of the amount of collagen fibers deposition in comparison to group II. Immunohistochemical results: TGF immuno-expression was positive in group II & III and negative in group IV. Histochemical results showed marked increase in the mean value of MDA level and marked decrease in SOD and GSH levels in Group II and Group III. Protection with fish oil in Group IV reversed this parameter towards the normal values of the control group. **Conclusion:** Fish oil ameliorates Amiodarone -induced lung toxicity.

[Naglaa A. S. Sarg and Kamal M. Kamal. **Protection against lung toxicity induced by Amiodarone in Albino rats by fish oil.** *J Am Sci* 2019;15(12):82-92]. ISSN 1545-1003 (print); ISSN 2375-7264 (online). <http://www.jofamericanscience.org>. 9. doi:[10.7537/marsjas151219.09](https://doi.org/10.7537/marsjas151219.09).

Keywords: Amiodarone-Fish oil-Omega-3-oxidative markers

1. Introduction:

Amiodarone (AD) is known in the market as Cordarone or Pacerone, and is a derivative of iodine benzofuran HCl. The pharmacological action of Amiodarone as efficient and potent anti-arrhythmic drug, where, it is capable for preventing and treating supraventricular and ventricular dysrhythmias. Though, the using of AD as a therapy is the use of AD is frequently restricted due to severe adverse side effects affecting most of vital organs^[1].

Amiodarone Pulmonary Toxicity (APT) is a serious adverse reactions to Amiodarone. This serious complication is manifested by acute or subacute pneumonitis. One of the most common symptoms of AD toxicity is the pneumonia, resembling respiratory distress syndrome (ARDS) in adults; which characterized by a high mortality rate among patients (50%) and can subsequently cause severe fibrosis in the lungs^[2].

AD increases the production of free radicals and induces mitochondrial oxidation^[3]. Cumulative effects of reactive oxygen species (ROS) may result in significant damage to cell structures leading to harmful effects such as lipid peroxidation and DNA damage^[4].

Generally, fish oil is extracted from oily fish tissues. One of the main component of fish oil is the Omega-3 (omega-3 PFAs), which is polyunsaturated fatty acids and are extensively used for the purposes of management and therapy of dyslipidemia and cardiovascular disease^[5]. The most potent constituents of omega-3 PFAs are docosahexaenoic acid (DHA) and eicosapentaenoic acid (EPA), which are considered as precursors of some eicosanoids, which are known by their role in suppressing inflammatory reactions in the body and reduced elevated triglycerides in the circulation^[6]. They suppress inflammation via regulating the release of inflammatory cytokines, like interleukins, lipid mediators and tumor necrosis factor-alpha (TNF- α)^[7]. There are strong evidences that support dietary supplementation with fish oil to prevent cardiac death^[8]. Many recent studies documented the antioxidant, anti-apoptotic and the anti-inflammatory effects of the omega-3 on many tissues^[9].

The purpose of the current investigation is to explore the toxic effects of Amiodarone on the Albino rat lungs and to detect whether or not these effects can be reversed by withdrawal of the drug.

The protective role of fish oil against these toxic effects is also evaluated.

2. Materials

A- Animals:

The present investigation was performed on 32 adult male albino rats 9 weeks old, their weights ranged from 180-220 g. The rats were purchased from the Animal house colony, Faculty of Veterinary Medicine, Benha University, Egypt. The rats were maintained in separate clean cages under standard environmental conditions approved by the Animal Use and Care Committee, under controlled light cycle (12 h light/12 h dark). The rats were kept in uniform husbandry conditions at a temperature of $25\pm 1^\circ\text{C}$, with a relative humidity of $50\pm 10\%$. The rats were freely supplied with sterilized diet that consists of milk, vegetables and bread feed and water. All rats were kept under the same circumstances throughout the experiment.

B- Drugs:

Amiodarone (Amiodarone Hydrochloride) was obtained from Global Napi Pharmaceutical Co., Egypt (under license of Sanofi Aventis, France), in the form of tablets. Each tablet contains 200 mg of Amiodarone hydrochloride. The tablet was dissolved in 20 ml distilled water. Amiodarone was given in a dose of 30 mg/kg/day. It was administered orally via gastric gavage for 6 weeks^[10].

2- Fish oil

Fish oil was purchased from Swiss company (Melbourne, Australia). The given dose was 150mg/kg/day^[11].

Experimental design:

All the animals (32 male Albino rats) were classified randomly into 4 equal groups:

Group I, was kept as (Control group):

The rats received no medications and left to survive for 6 weeks.

Group II (Amiodarone treated group):

Each rat given orally via gastric gavage 30 mg/kg BW Amiodarone, daily for 6 weeks.

Group III (Amiodarone withdrawal group):

The rats received for 6 weeks the same dose of Amiodarone as in group II, and at the end of treatment (6weeks) were sacrificed.

Group IV (Amiodarone and fish oil treated):

Received Amiodarone in a daily dose of 30 mg/kg BW orally via gastric gavage and a daily dose of fish oil 150mg/kg BW orally via gastric gavage (given 2 hours preceding Amiodarone) for 6 consecutive weeks.

Collection of samples:

At the termination of the experimental period, all rats were sacrificed in all groups via a lethal dose of ether, the thorax rats were opened in each rat

individually, and ligated the hilum of the lung. Lungs were separated free from the bronchi, hilar nodes and blood vessels. Fixation of left lungs in 10% neutral-buffered formalin was carried out for both immunohistochemical and histopathological examinations. Some slices of the right lungs were used for biochemical study.

Histopathological analyses:

The lung specimens were carefully washed in normal saline then fixed in 10% formalin solution. Then fixed materials were processed according to the general protocol and embedded in paraffin wax and 5-micrometer thick sections were prepared and subjected to staining with Hematoxylin-Eosin (Hx & E) and Masson's Trichrome (MT)^[12].

Immunohistochemistry

Staining of specimens by anti - TGF - $\beta 1$ antibody (Santa Cruz Biotechnology Inc, Santa Cruz, CA, USA) by streptavidin-biotin technique during Immunohisto chemical method was done. 4 μl section thickness of tissues were deparaffinized and incubated at room temperature with fresh 0.3% H_2O_2 in methanol for 30 min. The tissues were incubated with the primary antibody (anti - TGF - $\beta 1$ antibody). The specimens were stained with haematoxylin as counterstain. Cells showing with yellow/brown granules in cytoplasm of cell is considered a positive^[13].

Morphometric study:

The percentage of a mean area of collagen deposition was quantified in 5 images from 5 non-overlapping fields of every rat sample. Also the mean area % of TGF - $\beta 1$ immuno-expression in lung interstitium was enumerated in 5 images from 5 non-overlapping fields of every rat by applying Image-Pro Plus program version 6.0 (Media Cybernetics Inc., Bethesda, Maryland, USA).

Histochemical analysis (Estimation of oxidative markers):

Fresh lung specimens were homogenized in 10% (w/v) Tris- HCl buffer (5 mmol/L containing 2 mmol/L Ethylene-Diamine-Tetra-Acetic acid (EDTA), adjusted pH to 7.4. The lung homogenates were then centrifuged for 10 min at 1000 rpm and at 4°C , and the supernatants were immediately used for estimation of oxidant-antioxidant level. Malondialdehyde (MDA), Superoxide Dismutase (SOD) and Glutathione Reductase (GSH) as an index of the degree of lipid peroxidation were estimated according to the manufacturer's instruction provided by Biodiagnostic Company.

Statistical analysis

IBM SPSS Statistics software for Windows, Version 19 (IBM Corp., Armonk, NY, USA) were used for analyzing the obtained data from the experiment. To compare differences among the

groups, One-way analysis of variance (ANOVA) with Post Hoc LSD test was used. In each test, the data was expressed as the mean \pm SD and variations were considered to be non-significant at $P>0.05$, significant at $P\leq 0.05$ and highly significant at $P\leq 0.01$.

3. Results:

Histopathological results

Sections of the rat lungs stained with H & E of Group I "control group" showed the normal pulmonary architecture consisting of normal clear alveoli, alveolusacs and alveolar ducts. The alveoli were lined by alveolar epithelium consisting of two forms of cells; kind I pneumocytes, which looked as flat cells with flat nuclei and eosinophilic cytoplasm and kind II pneumocytes, which appeared as rounded cells with rounded nuclei and eosinophilic cytoplasm. The alveoli were separated from each other by thin inter-alveolar septa. The respiratory bronchioles were lined by simple columnar epithelial cells and surrounded by smooth muscle layer and accompanied by bronchial arterioles (Figs. 1 & 2). Group II "Amiodarone- treated group" showed distorted pulmonary architecture. Collapsed alveoli, thickened inter-alveolar septa and mononuclear cellular infiltration were seen. Bronchiolar affection was evident in the form of massive peri-bronchiolar cellular infiltration and degenerated epithelial cells with exfoliated cells in the lumen (Figs. 3 & 4).

Group III (after withdrawal of Amiodarone for 6 weeks). Lung sections showed collapsed alveoli, bronchioles lined by degenerated epithelium with exfoliated epithelial cells in the lumen. Inflammatory cells were also detected around alveoli and bronchiole, thickened interalveolar septa and thick wall blood vessels (Figs. 5 & 6).

Group IV "Amiodarone and fish oil group" showed minimal damage of the pulmonary architecture with more or less normal lung tissues consisting of alveolar ducts, alveolar sacs and alveoli were lined by alveolar epithelium consisting of type I and type II pneumocytes. The alveoli were surrounded and separated from each other by thin inter-alveolar septa but few areas showed thickening of the inter-alveolar septa with mild mononuclear cellular infiltration. Respiratory bronchioles were seen lined

by simple columnar epithelial cells. Mild peri-bronchial cellular infiltration (Figs. 7 & 8).

Masson's Trichrome stained sections of the rat lungs of control Group showed minimal amount of collagen fibers deposition (Fig. 9). The lung tissues of Group II showed increased amount of collagen fibers deposition within the inter-alveolar septa, around bronchioles and around the arterioles (Fig. 10). Group III showed large area of collagen fibers (Fig. 11). Group IV showed decreased amount of collagen fibers deposition within the inter-alveolar septa, around bronchiole and arterioles (Fig. 12).

Immunohistochemistry:

Transforming growth factor- β 1 (TGF- β 1) is the main pro-fibrotic growth factor which enhances production and deposition of fibroblast collagen which subsequently resulting in fibrosis of lungs. analysis of the images of Immunohistochemistry demonstrated that of TGF- β 1 expression was widely expressed in lung tissue: in bronchial epithelial cells, alveolar epithelial cells fibroblast cells, and vascular endothelial cells in the form of yellow/brown granules in the cytoplasm of the cells.

There were negative reaction for immunohistochemical detection of TGF - β 1 in lung sections of group I "control group" and group IV" Amiodarone and fish oil group" (Figs. 13 & 16). Photomicrograph of lung sections of group II "Amiodarone- treated group" for immunohistochemical detection of TGF - β 1 showed strong positive reaction (Fig. 14). Photomicrograph of lung sections of group III "Amiodarone with drawal group" for immunohistochemical detection of TGF - β 1 showed Positive reaction (Fig. 15).

Morphometric results:

The mean area % of collagen deposition for all groups was demonstrated in (Table 1 & Histogram 1). There was insignificant increase ($P>0.05$) in mean area % of collagen deposition in group IV as compared to the control group, but area % of collagen deposition highly significantly increased in groups II & III matched with control & IV groups ($P<0.01$). Also, area % of collagen deposition insignificantly decreased ($P>0.05$). in group III in comparison with group II.

Table (1): Demonstrating the percentage of the mean area, SD of collagen fibers deposition in groups I, II, III and IV, parallel with all groups by Post Hoc LSD test.

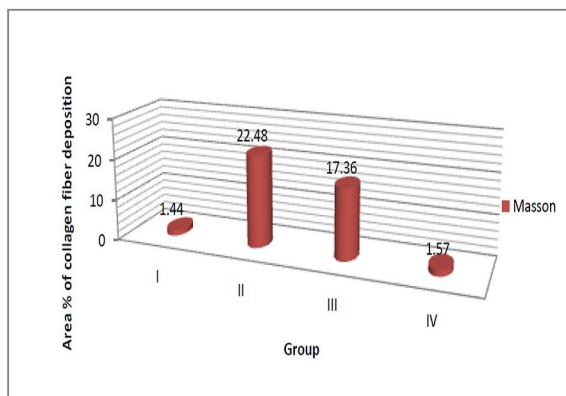
Mean % \pm SD	Group I	Group II	Group III	Group IV	F test	
Masson	1.44 \pm 0.96	22.48 \pm 9.50	17.36 \pm 5.84	1.57 \pm 0.92	11.16	0.003
Significance \leq 0.01	With groups II & III	With groups I & IV	With groups I & IV	With groups II & III		

Table 2 & Histogram 2, showing the mean area % of TGF- β 1 immuno-expression for all groups. There was insignificant elevation ($P>0.05$) in TGF immuno-expression in group IV, in contrast with the control group. Area % of TGF immuno-reactivity was

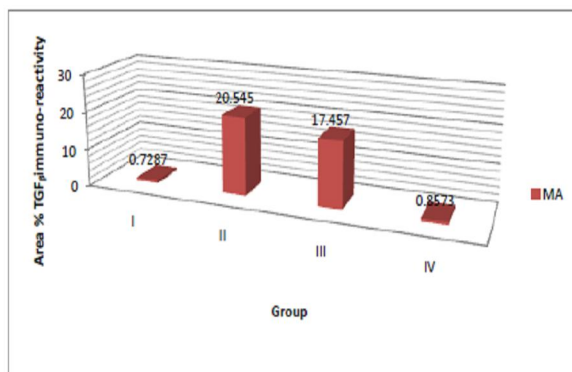
highly increased significantly ($P<0.01$) in groups II & III, in contrast with groups I & IV. Area % of TGF immuno-expression in significantly decreased ($P>0.05$) in group III, matched with group II.

Table (2): Showing mean values of area % immunoreactivity of TGF \pm SD in the 4 groups

Mean % \pm SD	Group I	Group II	Group III	Group IV	F test	P value
TGF	0.729 \pm 0.736	20.545 \pm 3.057	17.457 \pm 2.526	0.857 \pm 0.970	78.17	0.000
Significance \leq 0.05	With groups II & III	With groups I & IV	With groups I & IV	With groups II & III		



Histogram (1): Showing the mean area % of collagen fibers deposition in groups I, II, III and IV.



Histogram (2): Showing mean values of area %TGF immune reactivity in the 4 groups.

Histochemical analysis

The mean value of Malondialdehyde (MDA) in the lung homogenate of Groups I was ($2.15 \pm$

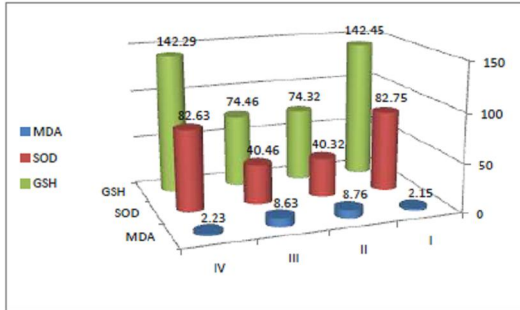
0.028 nmol/mg protein), meanwhile, there was marked increase in the mean value of MDA level in Group II and Group III (8.76 ± 0.118 nmol/mg protein) and (8.63 ± 0.2 nmol/mg protein) respectively. It was statistically highly significant relative to the values of Groups I. On the other hand, fish oil protection in Group IV reversed this parameter towards the normal value (2.23 ± 0.046 nmol/mg protein) which was statistically insignificant high in relation to the same values of Groups I.

The mean value of Superoxide Dismutase (SOD) level in the lung homogenate of Groups I was (82.75 ± 0.1 U/mg protein), meanwhile, Group II and Group III showed marked decrease in SOD level (40.32 ± 0.088 U/mg protein) and (40.46 ± 0.095 U/mg protein) respectively which were statistically highly significant relative to the values of Groups I. On the other hand, fish oil with Amiodaronein (Group IV) showed restoration of the normal value of SOD (82.63 ± 0.03 U/mg protein) that was statistically insignificant in relation to the values of Groups I.

The mean value of Glutathione reductase (GSH) level in lung homogenate of Groups I was (142.45 ± 0.152 U/mg protein) Meanwhile, Group II and Group III showed marked decrease in GSH value (74.32 ± 0.088 U/mg protein and 74.46 ± 0.095 U/mg protein respectively) which were statistically highly significant relative to the value of Group I. On the other hand, protection with fish oil in Group IV reversed this parameter to the normal value (142.29 ± 0.081 U/mg proteins) which was statistically insignificant compared with the value of Groups I (**Table 3 & Histogram 3**).

Table (3): Showing mean values of MDA, SOD & GSH \pm SD in the 4 groups

Mean \pm SD	Group I	Group II	Group III	Group IV	P value
MDA	2.15 ± 0.028	8.76 ± 0.118	8.63 ± 0.2	2.23 ± 0.046	0.000
SOD	82.75 ± 0.1	40.32 ± 0.088	40.46 ± 0.095	82.63 ± 0.03	0.000
GSH	142.45 ± 0.152	74.32 ± 0.088	74.46 ± 0.095	142.29 ± 0.081	0.000
Significance \leq 0.01	With groups II & III	With groups I & IV	With groups I & IV	With groups II & III	



Histogram (3): Showing mean values of MDA, SOD & GSH in the 4 groups.

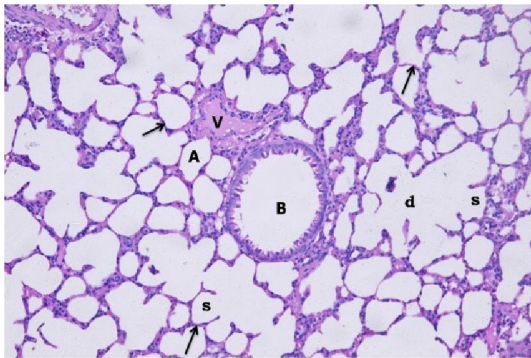


Fig (1): A Photomicrograph of lung section of rat from group I "control group" showing normal architecture of lung tissue, with normal clear alveoli (A), alveolar sac (S) and alveolar duct (d), thin inter-alveolar septa (arrow), normal bronchiole (B). Note the blood vessel (V). (H & E) x 250.

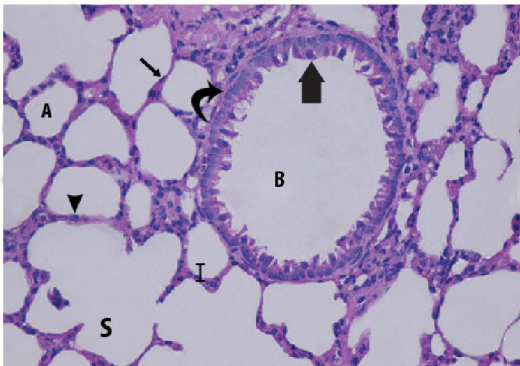


Fig. (2): Magnification of the photomicrograph in fig. 1 showing: lung alveoli (A) lined with type I pneumocyte cells with flat nuclei (thin arrow), type II pneumocyte cuboidal cells (arrow head) with thin interalveolar septa (I) and normal alveolar sacs (s). Normal clear bronchus (B) lined with normal columnar ciliated epithelium (thick arrow) and surrounded by smooth muscle layer (curved arrow) (H & E x 400).

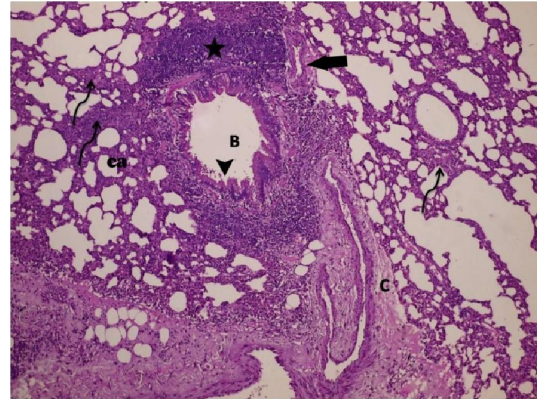


Fig (3): A Photomicrograph of lung section of rat from group II "Amiodarone-treated group" showing collapsed alveoli (ca), bronchus (B) lined with degenerated epithelial cells (arrow head), thickened interalveolar septa (curved arrow), massive mononuclear infiltration (astric), connective tissue (C). (H & E) x 250.

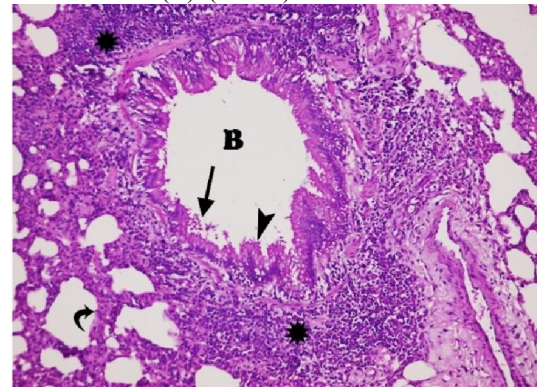


Fig. (4): Magnification of the photomicrograph in fig. 3 showing: Marked cellular infiltration (astric), thickened interalveolar septa (curved arrow). bronchus (B) lined with degenerated epithelial cells (arrow head) with exfoliated epithelial cells in the lumen (arrow). (H & E x 400).

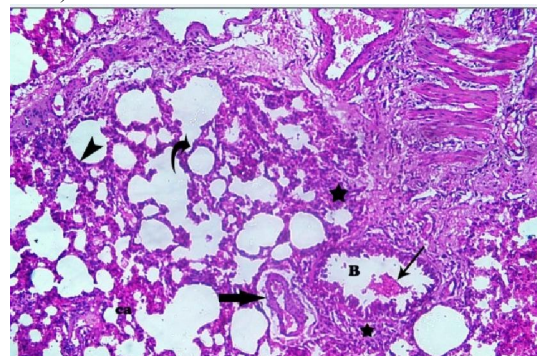


Fig (5): Photomicrograph of lung section of rat from group III "Amiodarone-Withdrawal group" showing collapsed alveoli (ca), bronchiole (B) containing exfoliated epithelial cells (thin arrow), thickened interalveolar septa (arrowhead), Mononuclear infiltration (astric), thickened wall blood vessel (thick arrow). Note thin interalveolar septum (curved arrow). (H & E) x250.

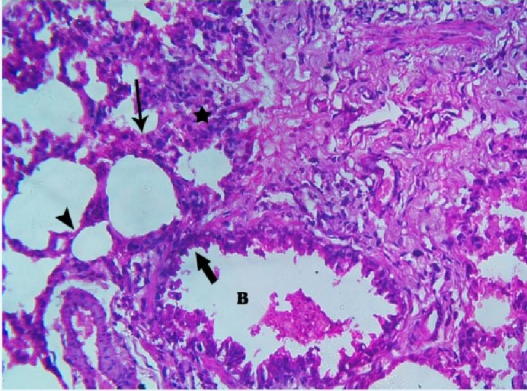


Fig. (6): Magnification of the photomicrograph in fig.5 showing bronchiole (B) lined with degenerated epithelium (thick arrow), thickened interalveolar septa (thin arrow), Massive mononuclear infiltration (astric). Note thin interalveolar septum (arrow head) (H & E) x 250.

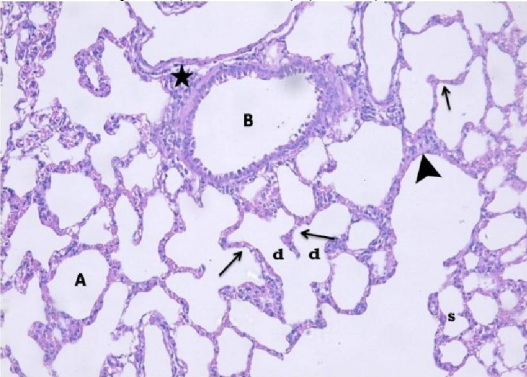


Fig. (7): A Photomicrograph of lung section of rat from group IV "Amiodarone and fish oil - group" showing more or less normal architecture of lung tissue with normal clear alveoli (A), alveolar sac (S), alveolar duct (d), thin interalveolar septa (Arrow), normal bronchus (B), with small area of mononuclear cell infiltration (astric). Note the thick inter-alveolar septum (Arrow head) (H & E) x 250.

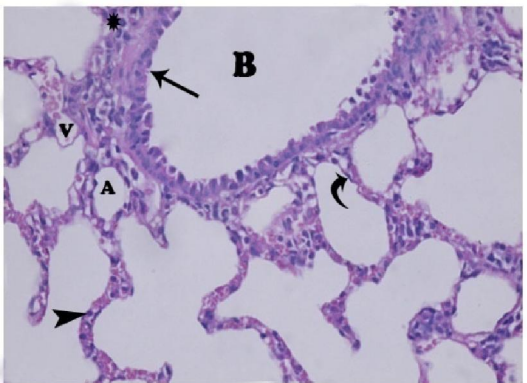


Fig. (8): Magnification of the photomicrograph in fig.7 showing more or less normal architecture of lung tissue with normal clear alveoli (A), lined with type I pneumocyte cells with flat nuclei (curved arrow), type II pneumocyte cuboidal cells (arrow head), normal bronchus (B) lined with normal columnar epithelium (arrow), with small area of mononuclear cell infiltration (astric). Note the blood vessel (V). (H & E) x 400.

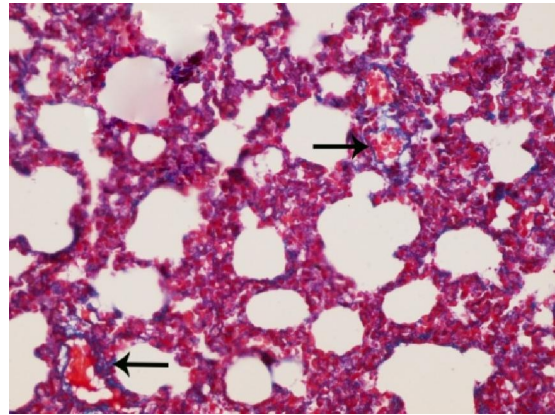


Fig. (9): A Photomicrograph of Masson's Trichrome stained lung section of rat from group I "control group" showing minimal collagen fibers. (arrow) (Masson's Trichrome x 400).

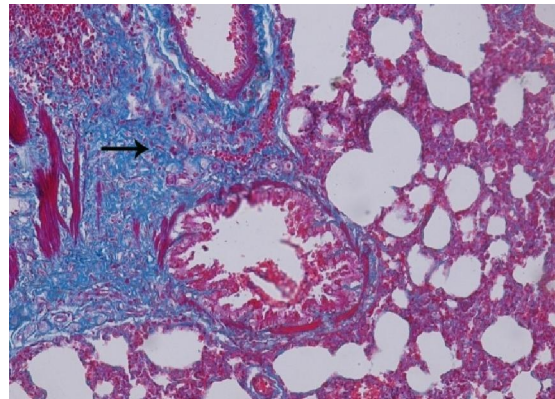


Fig. (10): A Photomicrograph of Masson's Trichrome stained lung section of rat from group II "Amiodarone-treated group" showing large area of collagen fibers (arrow). (Masson's Trichrome x 400).

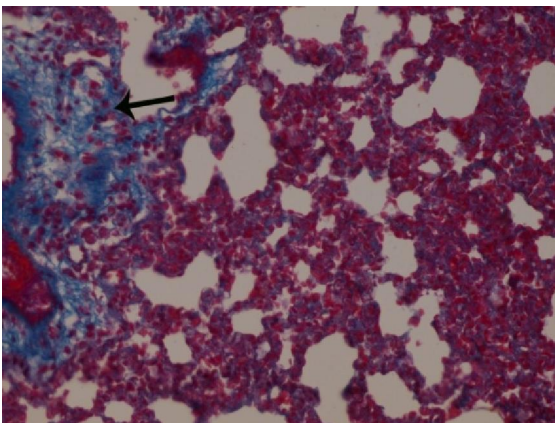


Fig. (11): A Photomicrograph of Masson's Trichrome stained lung section of rat from group III "Amiodarone-Withdrawal group" showing large area of collagen fibers (arrow). (Masson's Trichrome x 400).

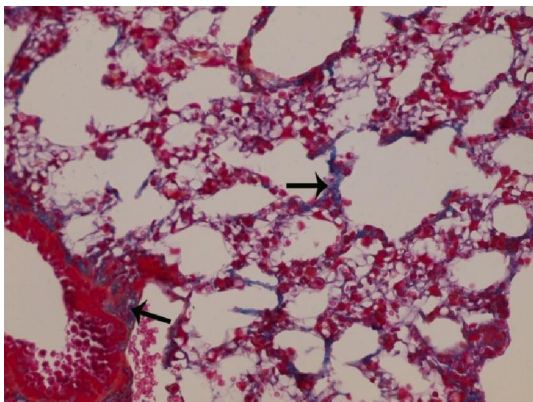


Fig. (12): A Photomicrograph of Masson's Trichrome stained lung section of rat from group IV "Amiodarone and fish oil group" showing decreased amount of collagen fibers (arrow). (Masson's Trichrome x400).

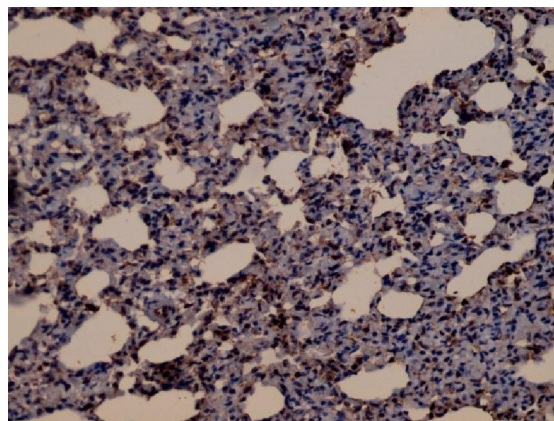


Fig. (15): A Photomicrograph of lung sections of rat from group III "Amiodarone -withdrawal group" for immunohistochemical detection of TGF-B1 showing Positive reaction. (brown colour). (IHC x 400).

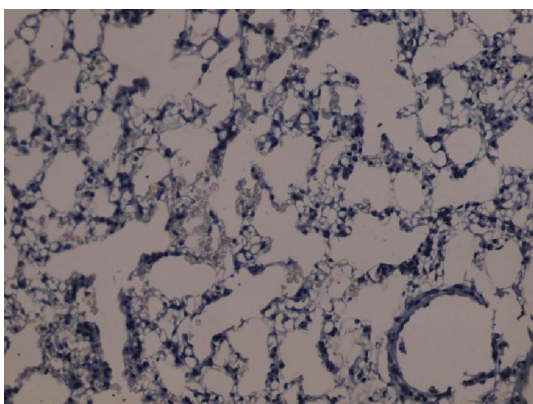


Fig. (13): A Photomicrograph of lung sections of rat from group I "control group" for immunohistochemical detection of TGF-B1 showing negative reaction. (IHC x 400).

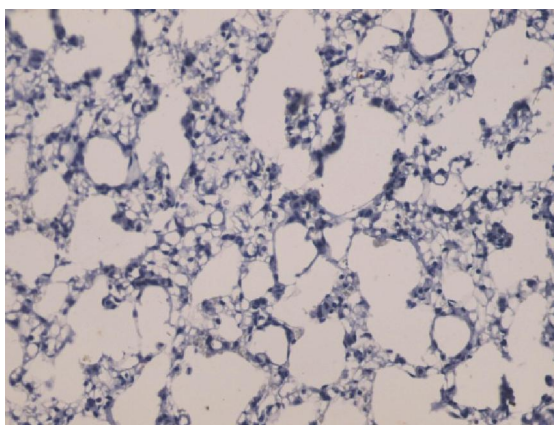


Fig. (16): A Photomicrograph of lung sections of group IV "Amiodarone and fish oil group" for immunohistochemical detection of TGF-B1 showing negative reaction. (IHC x 400).

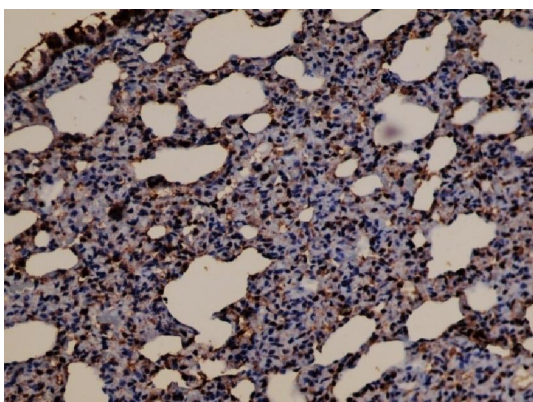


Fig (14): A Photomicrograph of lung sections of rat from group II "Amiodarone-treated group" for immunohistochemical detection of TGF-B1 showing strong positive reaction (brown colour) (IHC x 400).

4. Discussion

Amiodarone is a potent antiarrhythmic agent. serious pulmonary complications are usually liked with its uses, represented in organizing pneumonia, chronic interstitial pneumonitis and finally leads to pulmonary fibrosis ^[14]. In the present work, lung sections of rats from Amiodarone-treated group (Group II) showed marked degenerative changes; distorted pulmonary architecture; thickened inter-alveolar septa and mononuclear cellular infiltration. These findings were in agreement with **Zickri et al., (2014)**, who mentioned similar findings as thickening of the alveolar septa and dense cellular infiltration ^[15]. The results of this study were also similar to the findings of **Zaghlool et al., (2011)**, who observed disrupted alveolar walls and cellular infiltration ^[16]. **Mahavadi et al., 2014** confirmed the thickening of

alveolar septa with patchy fibrosis and cellular infiltration^[17].

The proposed mechanisms of Amiodarone pulmonary effects include direct cellular damage, activation of Natural killer cell and induction of phospholipidosis^[18]. Amiodarone induces phospholipidosis is by inhibiting lysosomal phospholipases enzymes leading to an irregular destruction of phospholipids stimulating its intracytoplasmic position and allowing large quantities of lipids to accumulate in phagocytic cells, which subsequently resulting in the formation of foamy macrophages and vacuolated pneumocytes type II^[19].

In the present study, the lung tissues of Group II stained with Masson's Trichrome showed increased amount of collagen fibers deposition around bronchioles, within the inter-alveolar septa, and round the arterioles. The morphometric results conclude that the mean area percent of collagen deposition highly significantly increased in AD-treated group (group II) in paralleled with control group. The finding is consistent with **Niu et al., (2013)** who showed enhanced collagen deposition in lung in AD-treated animals. Some investigators reported that pulmonary toxicity due to Amiodarone can advanced to pulmonary fibrosis^[20], which is considered as a chronic and irredeemable respiratory illness with atypical accumulation of collagen fibers subsequent leading to destruction of tissue^[21]. It is known that the main cause of pulmonary fibrosis can be induced at first via injury to the epithelium and basement membranes^[22]. Following tissue damage many types of cell migrate to areas of injury, such as immune cells, inflammatory and also fibroblasts, which stimulate the release of several cytokines which add another load of inflammation of cell, and subsequent modeling of matrix. At the end of all these processes leading to sever production of collagen fibers and other matrix constituents that are representative of pulmonary fibrosis^[23].

In the present study, a significant increase in TGF- β 1 expression in lung tissue was observed after AD treatment supporting a main role of cytokine in Amiodarone-induced pulmonary fibrosis. TGF- β 1 expression is up-synchronized in different experimental animal simulations of lung fibrosis^[24].

In this study, withdrawal of Amiodarone for 6 weeks in group III, lung sections showed the bronchioles lined by degenerated epithelium, inflammatory cells around alveoli and bronchi, thickened interalveolar septa. Some other alveoli are normal and this was proved by the morphometric results of this study in which the area percentage of collagen deposition insignificantly decreased in this group (group III) as compared to Amiodarone –

treated (group II) and the mean area percentage of TGF- β 1 immuno-expression insignificantly decreased in group III as compared to group II. These results were in agreement with **Zidan (2011)** who concluded that the withdrawal of Amiodarone showed little improvement of its harmful effect^[25]. The partial histological ateration reversibility of the lung tissue following withdrawal of Amiodarone might be attributed to the long durability (half-life) of Amiodarone drug and its affinity to deposited in the pulmonary tissue^[2].

Walaa et al., (2017) & Chakraborty et al., (2014) stated that the role of oxidative stress in the development of Amiodarone-induced pulmonary toxicity was suggested and they attributed these findings to the massive damage of the blood air barrier and increase in free radicals generation and mitochondrial hydrogen peroxide production^[18-26]. The mechanisms proposed for Amiodarone-induced pulmonary fibrosis may due to cell membrane perturbation; phospholipidosis promotion; altered Ca²⁺ cellular homeostasis; mitochondrial dysfunction; and free radical production^[27].

In this study histochemical analysis revealed significant increase in malondialdehyde (MDA) in groups II and III in comparison to group I and IV. polyunsaturated lipids are degraded to malondialdehyde by reactive oxygen species. The release of this reactive aldehyde as Malondialdehyde can cause severe irritation to the cells and considered as a toxic stress in cells and can be used as an indicator or biomarker for estimation of oxidative stress level in an organism^[28].

Also Histochemical analysis of this study revealed significant decrease in SOD and GSH in Amiodarone –treated group and Amiodarone withdrawal group in comparison to groups I and IV. Superoxide dismutase enzyme that consecutively catalyzes the dismutation of the superoxide (O_2^-) radical into hydrogen peroxide (H_2O_2) or ordinary molecular oxygen (O_2). Many types of cell damage can be induced from exposure to un control superoxide (by-product of oxygen degradation) release. H_2O_2 is degraded by other enzymes such as catalase and considered as a damaging cell factor. Therefore, Superoxide dismutase (SOD) is an essential defensive factor where it acting as antioxidant in approximately all living cells exposed to oxygen emission^[29]. Glutathione reductase (GR) is an enzyme that catalyzes the reduction of glutathione disulfide (GSSG) to the sulfhydryl form glutathione (GSH), which is a serious molecule in resisting oxidative stress and preserving the reducing media of the cell^[30].

In the current study, group IV (Amiodarone and fish oil group) showed marked improvement of the

pulmonary architecture consisting of almost normal clear alveoli, Thin inter-alveolar septa (Arrow), normal bronchiole with normal columnar epithelial cells, Mild peri-bronchial cellular infiltration were observed with minimal mononuclear cell infiltration. In Masson's Trichrome stained sections, the amount of collagen fibers deposition decreased within the inter-alveolar septa and around the bronchiole. In a similar study **KÜÇÜK et al., (2019)** found that damage to the lung tissue caused by cigarette smoking could be significantly prevented by Omega 3. They also found that the number of alveoli increased, the volume of the lung tissue was similar to the control group, and fibrosis regressed^[31]. Also **Juan et al., (2019)** proved that exposure to fine particulate matter PM2.5 induces oxidative stress, lung injury and inflammation, which is ameliorated significantly by fish oil^[11]. Histochemical analysis of this study fish oil with Amiodarone in Group IV decrease the mean value of MDA and increase the mean value of SOD, GSH towards the normal values. This finding is in agreement with **Possamai et al., (2010)** who proved that Omega-3 PFAs representing the main efficient constituent of fish oil, possess anti-inflammatory properties, anti-oxidant properties and immune-modulated characters^[32]. Omega-3 PFAs can effectively reduce the lipid peroxidation and augment antioxidant metabolism. Omega-3 FA prompted a significant improvement of the inflammatory cytokines (IL-6, IL-1 β , TNF- α) and promotion of the anti-oxidative action^[33].

Bo et al., (2016) proved that Vit. E and Omega-3 PFAs can fall the concentrations of ROS, malondialdehyde (MDA), TNF- α and IL-6, but in the same time stimulate SOD activity in PM2.5-exposed vascular endothelial cells^[34]. **Mckeever et al., (2008)** reported that Omega 3 protects respiratory tissues against oxidative stress, improves lung function, and alleviates chronic obstructive pulmonary disease (COPD) and asthma symptoms^[35].

Conclusion:

We can concluded from the current work that treatment of rat with Amiodarone for long period can lead to severe pulmonary injury. Slight improvement of the adverse effect of the drug can be occur post withdrawal of the drug, but connected with giving of fish oil may ameliorate Amiodarone -induced lung toxicity. So, it is advisable to give fish oil with Amiodarone to reduce its toxicity on the lung.

Abbreviations

Amiodarone (AD)

Omega-3 polyunsaturated fatty acids (omega-3 PFAs).

Transforming growth factor-b1 (TGF-b1)

Malondialdehyde (MDA)

Superoxide Dismutase (SOD)

Glutathione reductase (GSH)

chronic obstructive pulmonary disease (COPD)

References:

1. Schwaiblmair M, Berghaus T, Haeckel T, Wagner T, von Scheidt W. (2010): Amiodarone-induced pulmonary toxicity: an under-recognized and severe adverse effect? *Clin Res Cardiol*; 99(11): 693–700.
2. Nacca N, Bhamidipati CM, Yuhico LS, Pinnamaneni S, Szombathy T. (2012): Severe amiodarone induced pulmonary toxicity. *J Thorac Dis*; 4(6): 667–670.
3. Van Erven L and Schalij MJ. (2010): Amiodarone: an effective antiarrhythmic drug with unusual side effects. *Heart*; 96:1593–600.
4. Aggarwal D, Sharma M, Singla SK (2013): The role of natural antioxidants as potential therapeutic agent in nephrolithiasis. *Asian J Pharm Clin Res*, 6(3): 48-53.
5. Calder PC. (2010): fatty acids and inflammation—from the membrane to the nucleus and from the laboratory bench to the clinic. *Clin Nutr*; 29:5–12.14.
6. Li MY, Wang YY, Cao R, Hou XH, Zhang L and Yang RH, et al (2015): Dietary fish oil inhibits mechanical allodynia and thermal hyperalgesia in diabetic rats by blocking nuclear factor-kappa B-mediated inflammatory pathways. *J Nutr Biochem*; 26:1147–55.
7. Lobo BW, Lima CK, Teixeira MS, Silva NL, Takiya CM, Ramos MF et al.; (2016): Fish oil attenuates persistent inflammatory pain in rats through modulation of TNF-alpha and resolving. *Life Sci*; 152:30–7.
8. Maki, KC and Dicklin, MR (2018): "Omega-3 Fatty Acid Supplementation and Cardiovascular Disease Risk: Glass Half Full or Time to Nail the Coffin Shut?". *Nutrients*. 10 (7): 864.
9. Uygur, R., Aktas, C., Tulubas, F., Uygur, E., Kanter, M., Erboga, M., et al.; (2014): Protective effects of fish omega-3 fatty acids on doxorubicin-induced testicular apoptosis and oxidative damage in rats. *Andrologia* 46(8):917-926.
10. Kolettis TM, Agelaki MG, Baltogiannis GG, Vlahos AP, Mourouzis I, Fotopoulos A et al.; (2007) Comparative effects of acute vs. chronic oral amiodarone treatment during acute myocardial infarction in rats. *Europace*, 9: 1099-1104.
11. Juan Li, Hang Li, Haibin Li, Weili Guo, Zhen An, Xiang Zeng et al.; (2019) Amelioration of PM2.5-induced lung toxicity in rats by nutritional supplementation with fish oil and

- Vitamin E. *Respir Res*; 20: 76.
12. Bancroft J. D, Layton C. and Suvarna S. K. (2018): The hematoxylin and eosin, Connective and other mesenchymal tissues with their stains, Transmission electron microscopy. Bancroft's Theory and practice of histological techniques. 8th ed., Churchill Livingstone of Elsevier, Philadelphia Ch. 10, P. 126-138, Ch.12, p. 153-175 and Ch. 21, p. 434-475.
 13. Abeer A. I. Sharaf El-Din and Omaira M. Abd Allah (2016): Impact of Olmesartan Medoxomil on Amiodarone-Induced Pulmonary Toxicity in Rats: Focus on Transforming Growth Factor- β 1. *Basic & Clinical Pharmacology & Toxicology*, 119, 58–67.
 14. Al-Shammari B, Khalifa M, Bakheet S A, Yasser M A. (2016): Mechanistic Study on the Amiodarone-Induced Pulmonary. *Toxicity Oxid Med and Cell Long*; 2: 1-10.
 15. Zickri Mb, Aboul Fadl Sg and Metwally Hg (2014): Comparative study between intravenous and intraperitoneal stem cell therapy in amiodarone induced lung injury in rat. *Inter J Stem Cells*, 7: 1-11.
 16. Zaghlool Ss, Zickri Mb, Abd El Aziz Dh, Ma-Brouk D, Metwally Hg (2011): Effect of stem cell therapy on amiodarone induced fibrosing interstitial lung disease in albino rat. *Inter J Stem Cells*, 4: 133-142.
 17. Mahavadi P, Henneke I, Ruppert C, Knudsen L and Venkatesan S (2014): Altered surfactant homeostasis and alveolar epithelial cell stress in amiodarone-induced lung fibrosis. *Toxicol Sci*, 4: 1-13.
 18. Walaa AM El-Nahrawy, Amr ME Zaher and Sara MR Ali (2017): Therapeutic effects of Laser and L-carnitine against amiodarone-induced pulmonary toxicity in adult male rats. *Trop J Pharm Res*, July 2017; 16(7): 1565.
 19. Mortuza GB, Neville WA, Delaney J, Waterfield CJ, Camilleri P. (2003): Characterisation of a potential biomarker of phospholipidosis from amiodarone-treated rats. *Biochim Biophys Acta*; 1631:136–146.
 20. Niu CH, Wang Y, Liu JD, Wang JL and Xiao JH. (2013): Protective effects of neferine on amiodarone- induced pulmonary fibrosis in mice. *Eur J Pharmacol*;714:112–119.
 21. Narjes Zaeemzadeha, Aliasghar Hemmati, Ardeshir Arzia, Mohammadtaha Jalaliband Iran Rashidic (2011): Protective Effect of Caffeic Acid Phenethyl Ester (CAPE) on Amiodarone-Induced Pulmonary Fibrosis in Rat. *Iranian Journal of Pharmaceutical Research*, 10 (2): 321-328.
 22. Nevins W Todd, Irina G Luzina and Sergei P Atamas, (2012): Molecular and cellular mechanisms of pulmonary fibrosis. *Fibrogenesis & Tissue Repair*, 5:11.
 23. Thomas A. Wynn (2011): Integrating mechanisms of pulmonary fibrosis. *J Exp Med*. 208(7): 1339–1350.
 24. Otsuka M, Takahashi H, Shiratori M, Chiba H and Abe S. (2004): Reduction of bleomycin induced lung fibrosis by candesartan cilexetil, an angiotensin II type 1 receptor antagonist. *Thorax*;59:31–8.
 25. Zidan, Rania Ahmad (2011): Effect of long-term administration of amiodarone on rat lung and the possible protective role of vitamin E: a histological and immunohistochemical study. *The Egyptian Journal of Histology* 34 (1): 117–128.
 26. Chakraborty A, Mondal C, Sinha S, Mandal J. and Chndra AK. (2014): Amiodarone induced oxidative stress in stress vulnerable organs of adult male rats. *Asian J Pharm Clin Res.*; 7: 177-183.
 27. Nicolescu AC, Comeau Takahashi T, Brien JF, Racz WJ and Massey TE. *Aryl* (2007):27 radical involvement in amiodarone-induced pulmonary toxicity: investigation of protection by spin-trapping nitrones. *Toxicol. Appl. Pharmacol*. 220: 60-71.
 28. Del Rio D, Stewart AJ and Pellegrini N (2005): "A review of recent studies on malondialdehyde as toxic molecule and biological marker of oxidative stress". *Nutr Metab Cardiovasc Dis*. 15 (4): 316–28.
 29. Hayyan M, Hashim MA and Al Nashef IM (2016): "Superoxide Ion: Generation and Chemical Implications". *Chem. Rev*. 116 (5): 3029–3085.
 30. Deponte M (2013): "Glutathione catalysis and the reaction mechanisms of glutathione-dependent enzymes". *Biochim. Biophys. Acta*. 1830 (5):3217–66.
 31. KÜÇÜK, Z.; TIMUR, B.; GÖZLÜKGILLER, H.; TIMUR, H.; ERKENEKLI, K.; ÇAYDERE, M. et al.; (2019): Protective effect of Omega 3 and vitamin D in preventing lung-tissue damage of newborn rats exposed to cigarette smoke during intrauterine period. *Int. J. Morphol.*, 37(1):87-92.
 32. Possamai FP, Junior SA, Parisotto EB, Moratelli AM, Inacio DB, Garlet TR, et al.; (2010): Antioxidant intervention compensates oxidative stress in blood of subjects exposed to emissions from a coal electric-power plant in South Brazil. *Environ Toxicol Pharmacol.*;30:175–80.
 33. Du X, Jiang S, Bo L, Liu J, Zeng X, Xie Y, et al.; (2017): Combined effects of vitamin E and

- omega-3 fatty acids on protecting ambient PM2.5-induced cardiovascular injury in rats. *Chemosphere*. Apr;173:14-21.
34. Bo L, Jiang S, Xie Y, Kan H, Song W and Zhao J. (2016): Effect of Vitamin E and Omega-3 fatty acids on protecting ambient PM2.5-induced inflammatory response and oxidative stress in vascular endothelial cells. *PLoS One*. 11(3) e0152216.
35. Mckeever, T. M.; Lewis, S. A.; Cassano, P. A.; Ocké, M.; Burney, P.; Britton, J. et al.; (2008): The relation between dietary intake of individual fatty acids, FEV1 and respiratory disease in Dutch adults. *Thorax*, 63(3):208-14.

11/16/2019