



Sensation Assessment of Dorsal Digital Artery Perforator Flap In Fingertip Reconstruction (A Prospective Study)

Prof. Dr. Mohamed Ahmed Khalaf Allah¹, Dr. Ahmed Gamal Othman¹, Dr. Ahmed Mohamed Gad Ali², Mostafa Kotb Abdelrazik Mohammed¹

¹General Surgery Department, Faculty of Medicine, Ain Shams University, Cairo, Egypt

²Plastic Surgery Department, Faculty of Medicine, Ain Shams University, Cairo, Egypt
mostafakotbau@yahoo.com

Abstract: Finger tip amputation is really a complicated issue because high rate of incidence and highly specialized functions of it. Surgeons make their efforts to reconstruct fingertip normal shape and restore its function in the form of restoration of sensations, and it is a challenging procedure. In this study we repaired fingertip amputations by DDAP flap without nerve coaptation and after a period of recovery, our goal been tested which was evaluation of flap sensation restoration. We found that this flap has considerable sensory return fair enough that enable patient to manipulate and deal normally with life activities and protect his hand and fingers. Homodigital donor-site morbidity is a major concern when raising a DDAP flap. Skin graft contracture and extensor tendon adhesion are inevitable, but early rehabilitation with the help of a physical therapist can be less prone to these complications. In conclusion, the use of the DDAP flap for fingertip reconstruction appears to result in excellent functional and aesthetic outcomes without sacrificing the digital artery. Therefore, we suggest that the DDAP flap may be a useful technique in all types of fingertip pulp defects.

[Mohamed Ahmed Khalaf Allah, Ahmed Gamal Othman, Ahmed Mohamed Gad Ali, Mostafa Kotb Abdelrazik Mohammed. **Sensation Assessment of Dorsal Digital Artery Perforator Flap In Fingertip Reconstruction (A Prospective Study)** *J Am Sci* 2019;15(9):91-99]. ISSN 1545-1003 (print); ISSN 2375-7264 (online). <http://www.jofamericanscience.org>. 12. doi: [10.7537/marsjas150919.12](https://doi.org/10.7537/marsjas150919.12).

Keywords: Sensation; Assessment; Dorsal; Digital; Artery; Perforator; Flap; Fingertip ; Reconstruction ; Prospective

1. Introduction

The hand is the main autologous “tool” used by primates and humans, so it is no surprise that fingertip and thumb tip injuries are the most frequently encountered injuries of the upper limb. The fingertips are the most important organs of tactile sensibility. The high density of Vater-Pacini bodies and the branches of the palmar digital nerves usually provide dynamic 2-point discrimination between 3 and 4 mm.¹

A fingertip injury is any soft tissue, nail or bony injury distal to the insertions of the long flexor and extensor tendons of a finger or thumb.²The terminal branches of the main palmar digital arteries provide the fingertip with arterial blood. Venous drainage on the palmar side is provided by superficial palmar veins and oblique communicating veins. The architecture of the subcutaneous tissue and fascia of the pulp withstands substantial pressure and shear force.¹

Hand and finger injuries can be crippling and affect all ages, the most is between the working-class adults and children. In adults, injuries are commonly due to occupational activities. In this setting,

lacerations are the major type of injury, followed by crush and avulsion injuries. Most injuries tend to be single and of minor severity, and can be treated as an outpatient. However, powered machines and non-powered hand tools are more likely to result in multiple types of injuries.³

The National Institute for Occupational Safety and Health in the United States conducted a survey across multiple emergency departments in 1982, and estimated occupational finger injuries to account for 25.7% of its workload. 1.6% had amputations of one or more fingers.⁴

Distal replantation is the best way to restore finger length and offer the best cosmetic results. Although microsurgical developments and techniques have enabled the replantation of even extreme distal tip amputations, replantation may not be feasible for distal pulp crush injuries. Several treatment options are available, including closure with shortening, simple skin grafting, composite grafting, transposition flaps, advancement flaps, antegrade-retrograde flow flaps, perforator flaps, and free flaps.⁵

The decision to choose which method of

reconstruction should be used depends on the localization, the geometry of the defect, and the exposed structures (bone, tendon, and nerve). The advantages and disadvantages of each technique depend on the difficulty and reliability of the procedure, donor site morbidity, and the recovery of sensation, all of which have to be carefully considered when choosing the best technique for the patient.⁵

The digital artery perforator flap is a vascular island flap elevated on the distal and either the radial or ulnar sides of the digit for the reconstruction of fingertip defects. The flap based on the small perforators coming out of the digital artery at the level of the distal interphalangeal joints (DIPJ) or near the DIPJ.⁶

This flap is used to reconstruct fingertip with versatile and debatable issue for sensation restoration. It is not necessary to analyse the geometry of defects when using the DDAP flap, as it is rotated around the perforators in a propeller-like fashion and can be easily applied and rotated to all types of fingertip defects. Although all types of pulp defects have been reconstructed with the DDAP flap, coverage of the dorsal oblique defects were easier.⁶

Aim of the work

The aim of this study is to assess the restoration of sensation in dorsal digital artery perforator flap for finger tip reconstruction.

3. Patients and Methods

This study was conducted on 15 patients who were presented to ER department Ain Shams university hospital and El Obour medical insurance hospital starting from (may/2018) till (September/2019).

The patients were complaining of fingertip

amputated, includes:

- Index: six cases.
- Middle finger: four cases.
- Ring finger: three cases.
- Little finger: two cases.

They were (13) males and (2) females.

Inclusion criteria:

- Adult cases.
- Cases with single or multiple fingertip amputation.
- Cases need coverage of fingertip (exposed bone).

- Clean sharp injury.

Exclusion criteria:

- pediatric cases
- Cases with co-morbidities (like DM).
- Cases with previous scar in flap design
- Crushed fingers. (Including zone of flap).
- Post- bite amputated tip. (Animal or human bites).

Surgical management:

❖ Patients were admitted to ER department they were examined clinically to assess the fingertip injury and were investigated.

❖ The investigation includes:

1. Routine labs.
2. Radiology (x-ray) hand.

❖ The patients were also assessed by preoperative photography.

❖ The patients were prepared for surgical intervention by repairing fingertip injury using dorsal digital artery perforator flap.

❖ **Surgical technique:**

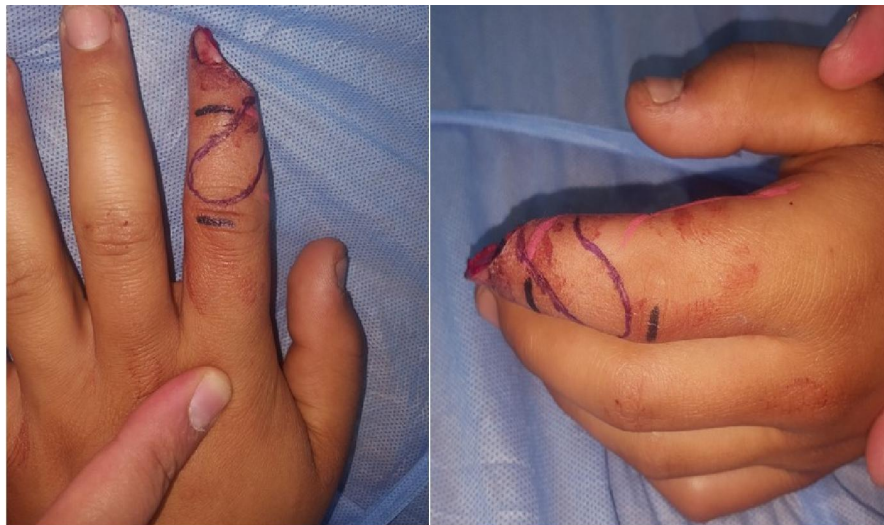

Fig. (1): Marking of the flap

1. Marking of the dorsal digital artery perforator flap for fingertip amputations according to Chao Chen et al in 2014, the flap was designed over the dorsum of the middle phalanx of the injured finger. According to the location of the defect, we selected the nearest uninjured dorsal branches of the digital artery to the defect as the vascular pedicle of the flap. The flap size was designed 10 to 15 percent larger than the defect. Fig. (1)

2. **Anaesthesia:** all anaesthesia were done using local (nerve block anaesthesia)

3. Digital Tourniquet was used according to Salem's technique.⁸⁷

4. Magnification loupe and sometimes microscope were used.

5. After inspecting the lesion, the affected finger was derided and cleansed; the lesion was also measured, in millimetres, using a sterile ruler.

6. Incision was done: according to marking we start by making the initial incisions along the free edges of the flap. The flap was then harvested with preservation of the tenosynovium. Judicious dissection of the perforator to avoid compromising of blood flow, from the proximal edge of the flap to the starting point of the dorsal branch of the digital artery, a cuff of subcutaneous tissue surrounding the dorsal branches of the digital artery was included in the pedicle. A strip of skin as a racquet shape⁸⁸ modification 3 mm in width was harvested with the pedicle to avoid compression after flap transfer. After that, the pedicle was released to the pivot point. Thus, the maximal pedicle length was achieved. After flap transposition, it is sutured by simple interrupted non absorbable 5-0 sutures. The flap was transferred to the defect. The donor defects were resurfaced with the full-thickness skin graft, and the graft was bolstered with tie-over dressings. Fig. (2)

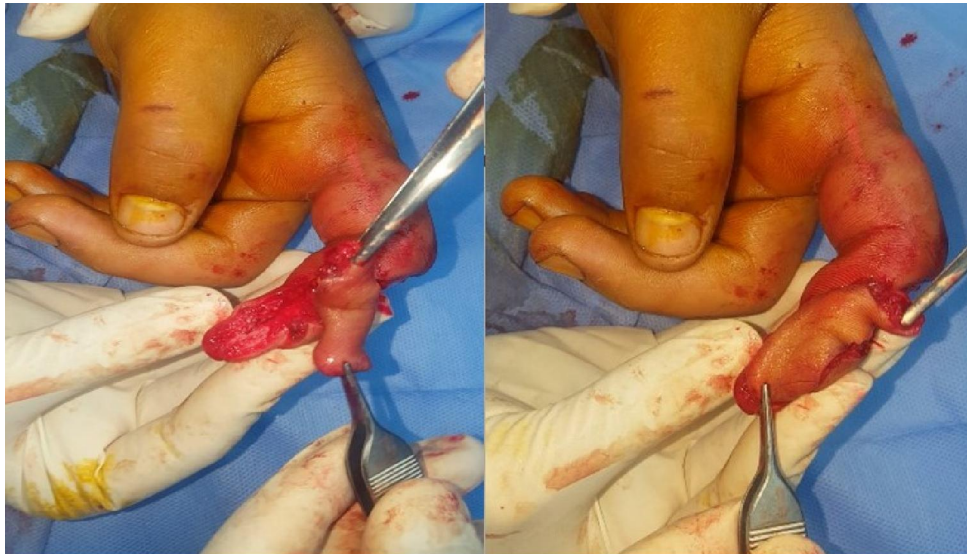

Fig. (2): Form of the flap after elevation

Postoperative:

Medication (antibiotic, analgesia) and repeated dressing, elevation of hand to minimizing venous congestion and prevent tight compression. Sensory stimulation and rehabilitation was applied to the recipient site and continued until the patient returned to work.

Follow up visits

- 1st visit: 24 hours after operation for assessment of flap vascularity.

- 2nd visit: 5 days after operation for clinical examination and follow up of postoperative complications as (infection, flap loss) and photography.

- 3rd visit: 15-30 days for photography, physiotherapy and follow up of partial loss (using repeated dressing till healing by 2ry intention.

- 3 months for sensation assessment and photography. Fig. (3)

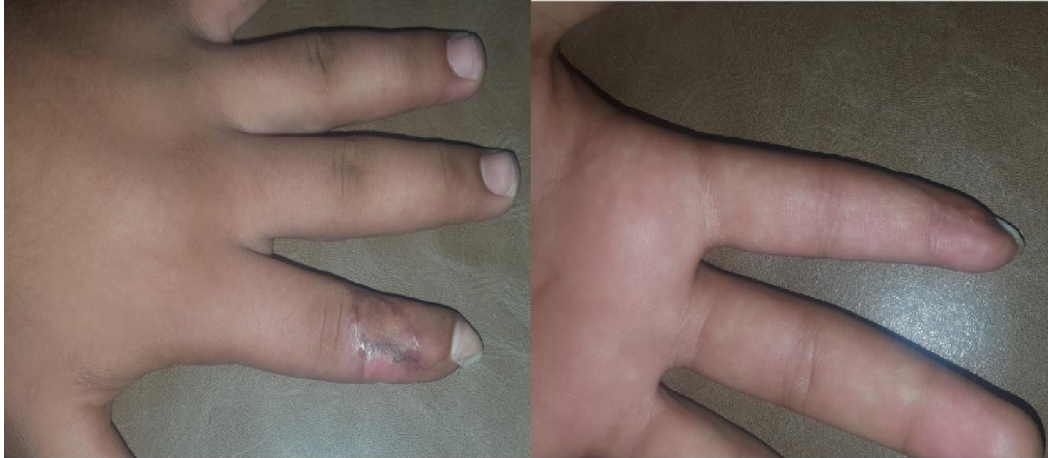

Fig. (3): Post operative follow up

3. Results

The present study was conducted for 15 patients clinically diagnosed as amputated fingertip at Al Demerdash university hospital and Elobour health insurance hospital and will be carried out in the period from May 2018 to the end of the study.

Patients Demography

The study included 13 male patients (86.7%) and 2 female patients (13.3%) with (male: female) rate of (6.5: 1)

Table (1): Demographic characteristics of the studied patients

Sex	No.	%
Male	13	86.7%
female	2	13.3%
Age		
<20	5	33.3%
20-30	6	40%
>30	4	26.7%

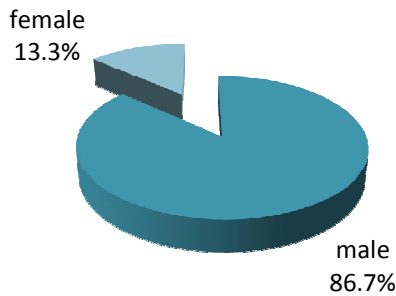


Fig. (4): Distribution of the patients according to sex

- Their mean age was (30), ranging from 18-42 with a median of 27.

-

patients distribution

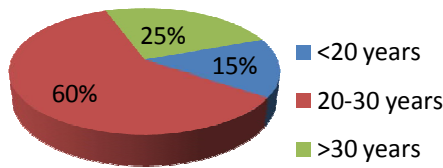


Figure (5): Distribution of the patients according to age.

Patients with occupational injury to normal trauma are 9 patients to 6 respectively in a ratio of 60% to 40%.

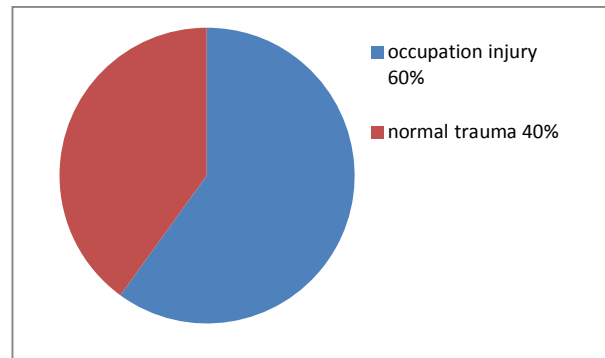


Fig. (6): occupation relationship

Clinical data of the patients:

In our study, a non-innervated flap was used in all 15 patients. The flap was harvested from middle phalanx to cover fingertip amputations. Digit were six indexes, four middle, three rings and two little fingertip amputations. The mean flap size was 2.2×2.0 cm (range 2.0×1.8 to 2.6×2.3 cm). Mean operation time was 1.4 hours.

Table (2):clinical data of cases:

	finger	Injury shape	site of pedicle	Flap size	Flap outcome
Case 1	middle	Proximal transverse	Radial side	2.5×2.1 CM	Congestion & distal necrosis
Case 2	index	Lateral oblique	Radial side	2.1×1.8 cm	Normal
Case 3	index	Palmar oblique	Radial side	2.4×2.3 cm	Congestion
Case 4	little	Lateral oblique	Ulnar side	2.0×1.8 cm	Normal
Case 5	ring	Proximal transverse	Ulnar side	2.0×2.0 cm	Distal necrosis
Case 6	ring	Palmar oblique	Radial side	2.2×1.9 cm	normal
Case 7	middle	Steep palmar oblique	Ulnar side	2.6×2.3 cm	Distal necrosis
Case 8	index	Proximal transverse	Radial side	2.3×1.8 cm	congestion
Case 9	little	Palmar oblique	Ulnar side	2.0×1.9 cm	normal
Case 10	middle	Steep palmar oblique	Radial side	2.6×2.0 cm	normal
Case 11	index	Steep palmar oblique	Radial side	2.4×1.9 cm	normal
Case 12	ring	Proximal transverse	Ulnar side	2.2×1.9 cm	normal
Case 13	index	Proximal transverse	Radial side	2.2×2.2 cm	congestion
Case 14	middle	Steep palmar oblique	Ulnar side	2.4×2.3 cm	Congestion & distal necrosis
Case 15	index	Palmar oblique	Ulnar side	2.5×2.2 cm	normal

Flap ischemia was not observed in any finger and venous congestion was noted in 5 fingers which consider high rate (33%). Partial distal flap necrosis was noted in 4 cases (26.6%), and healed without surgical intervention, No significant functional morbidity caused by secondary intention after flap necrosis was noted in these patients. Flap survived completely in 8 fingers. No wound infection was observed in this series.

Postoperative complications:

- Partial flap necrosis → repeated dressing till 2ry healing occurs.
- Complete flap loss → change plan to cross finger flap.
- Numbness → were assured the patient and physiotherapy.
- Scars → scar-remodelling products.
- venous congestion → relieved spontaneously within seven days.

Fingertip Pain

Based on the visual analogue scale, the median (range) pain score was 1 (range, 0 to 3) in the non-innervated dorsal digital artery perforator island flap groups.

Joint Motion arch

In the middle phalanx flap, the mean active motion arcs of the proximal and distal interphalangeal joints were 99 degrees (range, 85 to 110 degrees) and 69 degrees (range, 35 to 90 degrees), respectively. The measurements of the contralateral side were 101 degrees (range, 90 to 110 degrees) and 73 degrees (range, 45 to 90 degrees), respectively. There was a significant difference in the distal interphalangeal joint of the injured finger and that of the contralateral side. Maximum amplitude losses of 15 degrees were seen in 10 percent of patients in the distal

interphalangeal joint. No significant difference was found in the proximal interphalangeal joint.

Evaluation of fingertip sensations after reconstruction by DDAP flap:

We collected data regarding flap sensibility. We found no significant difference for patient age, sex, dominant hand, or follow up period. A significant difference was found for defect size.

At the final follow-up, the average two-point discrimination is 10.5 mm (range from 6 to 11 mm) and Semmes-Weinstein monofilament scores was 4.14 (range from 3.84 to 4.56)

In our study, reconstruction of fingertip injuries with a dorsal digital artery perforator flap, this allows provide the pulp by a glabrous skin and preserve length with excellent postoperative contour. There is a relative preservation of the volar skin and pulp.

Donor-Site Complications

Based on the visual analogue scale, 13 patients reported no pain and 2 reported mild donor-site pain. Four donor fingers showed signs of extensor tendon adhesion in the donor sites. The symptoms were alleviated by means of systemic rehabilitation. No functionally significant contracture caused by the flap procedure was noted in any of the patients. Color matching of the skin graft in the donor defect was normal in twelve patients, hypopigmented in two patients, and hyperpigmented in one patient.

Overall Patient satisfaction about DDAP flap:

We collect data about patient satisfaction by asking survey and the results is 14 out of 15 patients are satisfied about dorsal digital artery perforator flap for fingertip, we asked about contouring, shape, color matching, function restoration and time elapsed to return work.

Table (3): sensory assessment of DDAP flap:

	Two point discrimination		Semmes-Weinstein monofilament	
	Affected finger	Opposite normal finger	Affected finger	Opposite normal finger
Case 1	5mm	5mm	3.84	2.83
Case 2	8mm	5mm	3.84	2.83
Case 3	11mm	5mm	4.08	2.83
Case 4	8mm	4mm	3.84	2.83
Case 5	9mm	3mm	3.84	2.83
Case 6	11mm	4mm	4.17	2.83
Case 7	8mm	3mm	3.84	2.83
Case 8	10mm	4mm	4.08	2.83
Case 9	11mm	3mm	4.08	2.83
Case 10	12mm	4mm	4.17	2.83
Case 11	12mm	5mm	4.17	2.83
Case 12	9mm	3mm	3.84	2.83
Case 13	10mm	5mm	4.08	2.83
Case 14	7mm	4mm	3.84	2.83
Case 15	11mm	4mm	4.17	2.83

4. Discussion

While a fingertip injury is any soft tissue, nail or bony injury distal to the insertions of the long flexor and extensor tendons of a finger or thumb, and Tissue reconstruction in the fingers presents marked functional and aesthetic challenges.⁹

The main principles of fingertip reconstruction involve providing durable coverage for adequate cushioning surface, preserving sensation and length, minimizing discomfort, and prompting a timely return to work and leisure.⁷

To repair small to moderate defects, a variety of flaps have been described, allowing the use of a specific flap for each reconstructive situation. However, most are associated with drawbacks, such as the need to immobilize the finger, sacrifice of a digital artery, or poor sensory return.¹⁰

The volar V-Y advancement flaps work well for the covering of fingertip defects.¹¹ However, these flaps have limited size, deliver restricted mobility and are impossible to use for volar oblique defects or relatively distal transverse injuries of the fingertip without bone shortening. Lemmon et al. described bilateral V-Y advancement flaps as having certain limitations in cases with such indications. Regional flaps, such as a cross finger or thenar flaps, require two-stage operations.¹² The reconstructed finger must be flexed with a prolonged immobilization, which causes joint stiffness. This makes such flaps uncomfortable for the patients. In cases where the amputated part was not available for replantation, composite grafts deliver a high success rate and good results in treating fingertip amputations in children.¹³ Although lower success rates have been

reported, in recent studies, successful functional and aesthetic outcomes have also been reported in adults.¹⁴

Venkataswami and Subramanian¹⁵ described the oblique triangular flap in 1980, Evans and Martin¹⁶ developed the step-advancement flap based on neurovascular bundle in 1988 and Lanzetta et al.¹⁷ described the versatile homodigital triangular neurovascular island flap in pulp reconstructions in 1995. The advantages of these flaps are that they are single-stage procedures that produce a sensate flap and can be performed without sacrificing the digital artery. The limitations of these flaps include the difficulty in advancing more than 2 cm and risk of proximal interphalangeal (PIP) joint flexion contracture. Ozaksar et al. reported very good results in covering large pulp defects.¹⁸ Disadvantages of this flap are extensile incision and donor site graft requirement.¹⁹

Retrograde flow flaps are versatile flaps which may be performed homodigitally or heterodigitally. Advantages include the fact that it is a one-stage procedure resulting in a reliable vascular pedicle and extensive arc of rotation. Its disadvantages include increases in cold intolerance by 41.6%, sacrifice of a digital artery, long operating procedure, venous congestion, PIP joint contracture and higher incidence of total or partial loss.^{7, 19}

Free flaps are also available for fingertip coverage such as the medial plantar artery and its perforator flaps, the medialis pedis flaps and arterialized venous flaps. These techniques require a steep learning curve and strong microsurgical skills for the surgeon and a long operating time and period of recovery before to return to work.^{20, 21}

The DDAP flap was first described by Bertelli and Pagliei in 1994, then described by Koshima et al. as a perforator based flap.²² Mitsunaga et al. developed DDAP flaps in 2010 and reported their experiences and modifications with successful results in a limited numbers of patients.²³ In a previous study, Haluk ÖZCANLI reported the innervated digital artery flap as a new technique providing a sensate reconstruction for pulp defects with successful results and low complication rates.⁵

Classically, the fashion of defects such as transverse, volar or dorsal oblique with/without exposed bone is critical in choosing the most appropriate treatment method. However, it is not necessary to analyse the geometry of defects when using the DDAP flap, as it is rotated around the perforators in a propeller-like fashion and can be easily applied and rotated to all types of fingertip defects. This allows surgeons to insert the flap to the defect area in a tension-free manner. Although we have reconstructed all types of pulp defect with the DDAP flap, coverage of the dorsal oblique defects were easier.⁶

This flap is preferred to multistage regional flaps because of single-stage procedure, simultaneous coverage of multiple-finger defects, sensory reconstruction in important anatomical regions, minimal donor-site morbidity, lower cost, and minimal disability time. DDAP flaps allow reconstruction of pulp defects without sacrificing the digital artery. In this study and according to Chao Chen et al the time period needed for recovery and return to work is relatively short when compared to the other methods mentioned above.⁸² This factor is crucial in patients with a number of occupations, such as manual labourers or musicians. Limited flap size is its major disadvantage.⁹

The dissection and harvesting of the DDAP flap is neither difficult nor laborious. Koshima et al. reported that rich perforating arterioles and venules exist between the perforators of the digital artery within the subcutaneous tissue in the distal phalanx, and that these perforators permit the harvesting of the flap based on adipose tissue, which generally has superficial arterioles, in case of absence of the dominant perforator at the flap base.²⁴

However, the main drawback of the DDAP flap is that surgeons cannot be sure whether the flaps will involve the perforator or not until the flap is completely elevated and the risk of damaging the perforator in situations that require further dissections is high. But, according to this study and in concordance with Koshima et al., further dissection of the perforator to visually confirm entrance in the flap is not necessary. And also we encountered a flap venous congestion which improved spontaneously

within averages even days after surgery. The exact reason for the venous congestions is unclear, but it may be due to insufficient venous plexus compared to the arterial supply within the pedicle in the fingertip region. Completely elevating and skeletonizing the pedicle may contribute to the congestion, and is thus accepted as a second cause of venous failure. However, preserving a skin strip over the pedicle seems to be an efficient method for protecting the tiny venules and avoiding compression after flap transfer, and thus improving venous drainage.^{24, 25}

Multiple-finger defects are often complex and severe, and thus reconstructive alternatives are limited. Abdominal flaps are frequently used for repairing these complicated injuries. However, they are characterized by several drawbacks, such as long-term immobilization, prolonged rehabilitation, and bulky and insensate tissue coverage. In contrast, the entire dorsum of the middle and proximal phalanges can be used as the donor for DDAP flap based on the different levels of the dorsal branches of the digital artery. This important feature makes it more versatile for reconstructing defects in different regions of the finger, especially for simultaneously reconstructing small to moderate defects in multiple fingers.²⁶

It was reported that sensate flaps with a sensory nerve to reconstruct fingertip defects would better restore sensation of the injured fingertip. However, sensate or insensate reconstruction of the fingertip was still controversial among hand surgeons. Although previous articles and experiences had demonstrated that flaps larger than 1.0×1.0 cm had a reduced capacity for recovery of sensation without nerve coaptation, many authors obtained protective 2-point discrimination at a satisfactory level in their series by using insensate flaps.^{27, 28}

In 2012, Chao Chen described a dual-innervated dorsal homodigital island flap based on the end dorsal branches of the digital artery and the transverse palmar arch for reconstructing a fingertip defect associated with double transacted digital nerves. The modified flap has a longer pedicle that allows it to easily reach a defect as far as the fingertip. Moreover, both injured digital nerves can be simultaneously repaired with double dorsal branches of the digital nerves. And that comparison study showed that superior sensory recovery was achieved using the dual-innervated dorsal homodigital island flap compared with the single-innervated and noninnervated DDAP flaps. Therefore, he suggested performing double neurotaphies to improve flap sensation when reconstructing a fingertip defect combined with a transacted digital nerve on both sides.

Spontaneous sensory restoration was revealed in this study during the follow-up period despite the fact

that nerve coaptation was not performed between diminished light touch to diminished protective sensation according to Semmes Weinstein test, and between fair to poor 2pd sensation.

According to Chao Chen et al he used partial thickness skin graft for donor site coverage. In contrary in this study, we used full thickness skin graft for better cosmeses and there is no difference.⁹

Homodigital donor-site morbidity is a major concern when raising a dorsal digital artery perforator flap. Skin graft contracture and extensor tendon adhesion are inevitable, but early rehabilitation with the help of a physical therapist can be less prone to these complications. Although resection of the dorsal branch of the digital nerve or dorsal digital nerve may result in hypersensitivity or symptomatic neuroma, the complications were not noted in our series. Burying its proximal end into healthy soft tissue or the dorsal interosseous muscle may make it less symptomatic.⁹

References

- Germann G, Rudolf KD, Levin SL, et al. Fingertip and thumb tip wounds: changing algorithms for sensation, aesthetics, and function. 2017;42(4):274-284.
- Murai M, Lau H-K, Pereira BP, et al. A cadaver study on volume and surface area of the fingertip. 1997;22(5):935-941.
- Sorock GS, Lombardi DA, Hauser RB, et al. Acute traumatic occupational hand injuries: type, location, and severity. 2002;44(4):345-351.
- Coleman PJ, Sanderson LMJM, Summaries MWRS. Surveillance of occupational injuries treated in hospital emergency rooms—United States, 1982. 1983;31SS-37SS.
- Ozcanli H, Coskunfirat OK, Bektas G, et al. Innervated digital artery perforator flap. 2013;38(2):350-356.
- Özcanli H, Bektaş G, Cavit A, et al. Reconstruction of fingertip defects with digital artery perforator flap. 2015;49(49):18-22.
- Lemmon JA, Janis JE, Rohrich RJJ, et al. Soft-tissue injuries of the fingertip: methods of evaluation and treatment. An algorithmic approach. 2008;122(3):105e-117e.
- Chen C, Tang P, Zhang XJP, et al. The dorsal homodigital island flap based on the dorsal branch of the
- Oetgen ME, Dodds SDJ, Crimm. Non-operative treatment of common finger injuries. 2008;1(2):97-102.
- Liu Y, Jiao H, Ji X, et al. A comparative study of four types of free flaps from the ipsilateral extremity for finger reconstruction. 2014;9(8):e104014.
- Atasoy E, IOAKIMIDIS E, KASDAN ML, et al. Reconstruction of the amputated finger tip with a triangular volar flap: A new surgical procedure. 1970;52(5):921-926.
- Nishikawa H, Smith PJJ, HS. The recovery of sensation and function after cross-finger flaps for fingertip injury. 1992;17(1):102-107.
- Rose EH, Norris MS, Kowalski TA, et al. The “cap” technique: nonmicrosurgical reattachment of fingertip amputations. 1989;14(3):513-518.
- Chen S-Y, Wang C-H, Fu J-P, et al. Composite grafting for traumatic fingertip amputation in adults: technique reinforcement and experience in 31 digits. 2011;70(1):148-153.
- Venkataswami R, Subramanian NJP, Surgery R. Oblique triangular flap: a new method of repair for oblique amputations of the fingertip and thumb. 1980;66(2):296-300.
- Evans D, Martin DJB, Jops. Step-advancement island flap for fingertip reconstruction. 1988;41(2):105-111.
- Lanzetta M, Mastropasqua B, Chollet A, et al. Versatility of the homodigital triangular neurovascular island flap in fingertip reconstruction. 1995;20(6):824-829.
- Özaksar K, Toros T, Sığün T, et al. Reconstruction of finger pulp defects using homodigital dorsal middle phalangeal neurovascular advancement flap. 2010;35(2):125-129.
- Yildirim S, Avci G, Akan M, et al. Complications of the reverse homodigital island flap in fingertip reconstruction. 2002;48(6):586-592.
- Koshima I, Urushibara K, Inagawa K, et al. Free medial plantar perforator flaps for the resurfacing of finger and foot defects. 2001;107(7):1753-1758.
- Lee H-B, Tark K-C, Rah D-K, et al. Pulp reconstruction of fingers with very small sensate medial plantar free flap. 1998;101(4):999-1005.
- Basat SO, Ugurlu AM, Aydin A, et al. Digital artery perforator flaps: an easy and reliable choice for fingertip amputation reconstruction. 2013;47(4):250-254.
- Mitsunaga N, Mihara M, Koshima I, et al. Digital artery perforator (DAP) flaps: modifications for fingertip and finger stump reconstruction. 2010;63(8):1312-1317.
- Koshima I, Urushibara K, Fukuda N, et al. Digital artery perforator flaps for fingertip reconstructions. 2006;118(7):1579-1584.
- Suzuki S, Koshima IJHS. Digital artery perforator flap for reconstruction of fingertip after resection of melanoma in situ. 2011;16(03):395-398.

26. Urushidate S, Yotsuyanagi T, Yamauchi M, et al. Modified thin abdominal wall flap (glove flap) for the treatment of acute burns to the hands and fingers. 2010;63(4):693-699.
27. JOHNSON RK, IVERSON REJJ. Cross-finger pedicle flaps in the hand. 1971;53(5):913-919.
28. KLEINERT HE, MCALISTER CG, MACDONALD CJ, et al. A critical evaluation of cross finger flaps. 1974;14(9):756-763.

9/20/2019