



Role of Diagnostic Laparoscopy in Management of Acute Abdomen of Unknown Aetiology

To: Prof. Dr. Mahmoud Ahmed El-Shaf'ey, Assist. Prof. Dr. Hesham Mohamed Ali Omran, Dr. Mohamed Gamal Abd El-Rahman and Reda Harby Marzouk Mithany*

General Surgery Department, Faculty of Medicine, Ain Shams University, Cairo, Egypt
E-mail: reda7rby@gmail.com

Abstract: Background: Acute abdominal pain (AAP) is a medical emergency, characterized by pain arising from the abdominal area, of non-traumatic origin with a maximum duration of five days. It is the most common surgical emergency, one of the most common reasons for referral to an emergency department (ED) and the most common cause for non-trauma-related hospital admissions. **Aim of the Work:** To evaluate the role of laparoscopy in the diagnosis and treatment of unexplained acute abdominal pain and establish it instead of conventional exploratory laparotomy. **Results:** Maximum numbers of patients were of age 26 to 30 years (9 patients i.e. 30.0%). Least number of patients were from age group of 31-35 years. Female patients of acute abdomen were slightly more than that of male patients, due to increased number of cases of acute cholecystitis in females. Most common cause of acute abdomen in this study was acute appendicitis, while least common causes were pelvic inflammatory disease and mickel's diverticulum equally. Laparoscopy was done in all cases (100%); therapeutic laparoscopy was successful in 22 cases (73.30%) while 8 (26.7%) patients required to be converted to laparotomy. Complications related to laparoscopy in our study were observed in 15 out of 30 cases (50%); with shoulder pain is the most common one. **Conclusion:** Diagnostic Laparoscopy is helpful in confirming a diagnosis made on clinical grounds and laboratory evaluation.

[Mahmoud Ahmed El-Shaf'ey, Hesham Mohamed Ali Omran, Mohamed Gamal Abd El-Rahman and Reda Harby Marzouk Mithany. **Role of Diagnostic Laparoscopy in Management of Acute Abdomen of Unknown Aetiology.** *J Am Sci* 2019;15(9):84-90]. ISSN 1545-1003 (print); ISSN 2375-7264 (online). <http://www.jofamericanscience.org>. 11. doi:[10.7537/marsjas150919.11](https://doi.org/10.7537/marsjas150919.11).

Keywords: Acute abdominal pain - Diagnostic Laparoscopy – Aetiology

1. Introduction

Despite substantial improvement in the diagnostic approach to AAP, mainly attributable to the extensive use of imaging techniques [especially computed tomography (CT)], many diagnostic pitfalls remain, which can be associated with a substantial number of misdiagnoses and/or avoidable surgery⁽¹⁾.

Acute appendicitis, diverticulitis, cholecystitis, and bowel obstruction are common causes of acute abdominal pain, but other important, even if less frequent conditions, that may cause acute abdominal pain include perforated viscus or vascular diseases such as aortic dissection and mesenteric ischemia⁽²⁾.

Laparoscopies are now widely used to diagnose many different conditions:

Pelvic inflammatory disease (PID) – a bacterial infection of the female upper genital tract, including the womb, fallopian tubes and ovaries.

- Endometriosis – where small pieces of the womb lining (the endometrium) are found outside the womb.

- Ectopic pregnancy – a pregnancy that develops outside the womb.

- Ovarian cyst – a fluid-filled sac that develops on a woman's ovary.

- fibroids – non-cancerous tumours that grow in or around the womb (uterus)

- Female infertility

- Undescended testicles – a common childhood condition where a boy is born without one or both testicles in their scrotum.

- Appendicitis – a painful swelling of the appendix (a small pouch connected to the large intestine)

- Unexplained pelvic or abdominal pain

- Laparoscopy can also be used to diagnose certain types of cancers. The laparoscope is used to obtain a sample of suspected cancerous tissue, so it can be sent to a laboratory for testing. This is known as a biopsy.

- Cancers that can be diagnosed using laparoscopy include:

- Liver cancer

- Pancreatic cancer

- Ovarian cancer
- Cancer of the bile duct
- Cancer of the gallbladder

Treating conditions

■ Removing an inflamed appendix – in cases of appendicitis where there's a high risk of the appendix bursting.

■ Removing the gallbladder – often used to treat gallstones.

■ Removing a section of the intestine – often used to treat digestive conditions, such as Crohn's disease or diverticulitis, that don't respond to medication.

■ Repairing hernias – such as those found in the groin

- Repairing burst or bleeding stomach ulcers
- Performing weight loss surgery

■ Removing some or all of an organ affected by cancer – such as the ovaries, prostate, liver, colon, kidney or bladder.

■ Treating ectopic pregnancy – it's usually necessary to remove the embryo to prevent damage to the fallopian tubes.

- Removing fibroids

■ Removing the womb (hysterectomy) – sometimes used to treat pelvic inflammatory disease (PID), endometriosis, heavy periods or painful periods.

Minimally invasive surgery continues to transform the field of gynecologic oncology and has now become the standard of care for many early-stage malignancies. The proven benefits of minimally invasive surgery are driving the rapid introduction and dissemination of novel technologies and the increasing ability to perform even the most complex procedures less invasively⁽³⁾.

While laparotomy is the standard of care in hemodynamically unstable patients, stable patients are usually treated by non-operative management (NOM), incorporating adjuncts such as interventional radiology. However, although NOM has shown good results in solid organ injuries, other lesions, namely those involving the hollow viscus, diaphragm, and mesentery, do not qualify for this approach and need surgical exploration. Laparoscopy requires adequate training and experience as well as sufficient staffing and equipment⁽⁴⁾.

Aim of the work

■ To evaluate the role of laparoscopy in the diagnosis and treatment of unexplained acute abdominal pain and establish it instead of conventional exploratory laparotomy.

■ Provide educational preliminary laparoscopy courses for the junior staff.

■ Support the laparoscopy as an emergency tool in the first 24 hours of patients admissions at the emergency department.

2. Patients and methods

Type of study:

A prospective study randomized by closed envelope method.

Study setting:

The current study was carried out in Ain Shams University Hospitals

Study period:

During the period from January 2018 and December 2018.

Study population:

Inclusion criteria:

- Aged from 20 to 40 years old.
- Symptomatic acute abdomen.
- Informed consent provided.
- Patients with recurrent abdominal pain of unknown aetiology after conventional ultrasonography.

Exclusion criteria:

- An active infection in the anterior wall near the planned entry or accessory trocar site.
- Uncorrectable coagulopathy
- Morbid obesity
- Hemodynamically unstable patients.
- Patients presenting with chronic abdominal pain.
- Patients refusing the invasive techniques

Sampling method:

A total of 30 patients with acute abdomen (20 - 40 years old).

Ethical consideration:

Approval was obtained from the ethical committee of the department of general surgery, faculty of medicine, Ain Shams University.

Study procedure:

In many cases, abdominal problems can also be diagnosed with imaging techniques such as:

- Ultrasound, which uses high-frequency sound waves to create images of the body.
- CT scan, which is a series of special X-rays that take cross-sectional images of the body.
- MRI scan, which uses magnets and radio waves to produce images of the body.

Laparoscopy is performed when these tests don't provide enough information or insight for a diagnosis. The procedure may also be used to take a biopsy, or sample of tissue, from a particular organ in the abdomen.

Pre-operative:

- FBC, U & E, LFTs, ESR, CRP, Serum amylase, Urinalysis.
- Erect CXR, Pelviabdominal USS, CT Scan.

Procedure:**Precautions:**

The patient is fasting for 6 hours beforehand.

Stop (anticoagulants), such as aspirin or warfarin, a few days beforehand. This is to prevent excessive bleeding during the operation.

Most people can leave hospital either on the day of the procedure or the following day.

Creation of Pneumoperitoneum

10-20 degree head down

10 mm transumbilical incision

Insert Veress needle at 45 degree elevation angle

Start insufflation at 1litre/minute

Laparoscopic Appendectomy

Acute appendicitis (AA) is a clinical diagnosis. The first appendectomy was performed in New York in 1886. Then, appendectomy was considered to be the most common emergency surgery ⁽⁵⁾.

The introduction of the laparoscopic approach for appendectomy, described by Kurt Semm in 1982, has brought significant aesthetic benefits, since it is almost always performed with three incisions, two of which are located in different positions in the abdominal wall, but always visible on the exposed abdomen. This is particularly important when the operation is in young female. In the technique proposed here, the first incision of 5 or 10 mm in length is not visible, due it is located inside the umbilicus. The other two, being held in low hypogastrium, are also almost imperceptible because they can be hidden by underclothes ⁽⁶⁾.

Indications:

- Female of reproductive age
- Pre-menopausal age
- Suspected appendicitis
- Working status
- Obese patients
- Cirrhosis & Sickle cell disease
- Immune-compromised

Ports / Instruments:

Three incisions for trocars are performed. The first, 5 to 10 mm in length, is made in the umbilicus for the optical device (incision is dependent on optical diameter) using permanent metallic trocar. Two other suprapubic incisions are performed at low bilateral position, medial to the epigastric vessels. On the right side is introduced one 5 mm permanent metallic trocar; on the left, another of 10 mm with reducer to 5 mm. The surgeon is on the left side of the patient, with the first assistant on his right and instrumentation table on the left. The monitor is put on the right side of the patient ⁽⁵⁾.

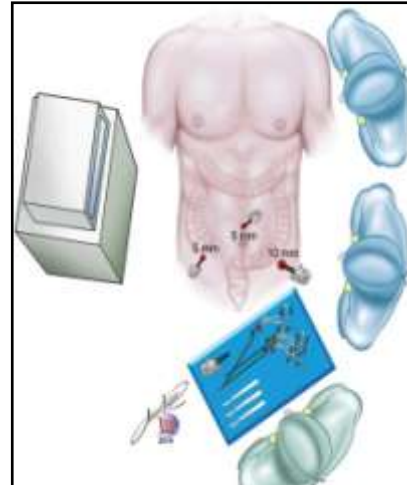


Figure (1): Technique of laparoscopy ⁽⁵⁾.

Procedure:

- An atraumatic grasper is inserted via the RUQ port.
- The cecum is retracted upward toward the liver.
- The appendix is grasped at its tip with a 5 mm claw grasper via the RUQ trocar. It is held in upward position.
 - Create a mesenteric window of 1cm size behind the base of the appendix as close as possible to the base of the appendix.
 - Extra-corporeal knotting performed for mesoappendix as well as appendix.
 - The appendix is now amputated from the GIT.
 - The appendix held by the grasper and is placed into the specimen bag.
 - Close the wound Using vicryl for rectus and Unabsorbable intra-dermal or Stapler for skin.

Pain management following this procedure is important, as either the presence of inadequately treated pain or the occurrence of significant side effects associated with opiate analgesics may prolong surgical recovery ⁽⁷⁾.

Laparoscopic cholecystectomy:

Both laparoscopic and open cholecystectomy procedures altered the inflammatory milieu of our patients in the postoperative period. Inflammation caused by the laparoscopic procedure was significantly less. More research is needed to target specific inflammatory and anti-inflammatory cytokines to reduce surgical stress and improve patient outcomes ⁽⁷⁾.

Laparoscopic cholecystectomy (LC) has become one of the most effective procedures for the treatment of benign gallbladder pathology since its introduction in 1985 ⁽⁸⁾.

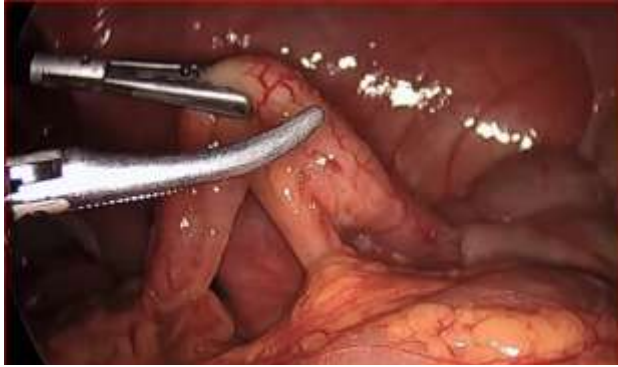

Figure (2): Laparoscopic appendicectomy.

Position:

Port positions:

- 5-mm (preferred) or 10-mm port in the periumbilical position for a 5-mm or 10-mm laparoscopic scope.
- 10-mm port in the subxiphoid position with the intra-abdominal portion located to the right of the falciform ligament.
- 5-mm port 2 fingerbreadths below the costal margin and close to the midclavicular line, to position the port over the gallbladder intra-abdominally.

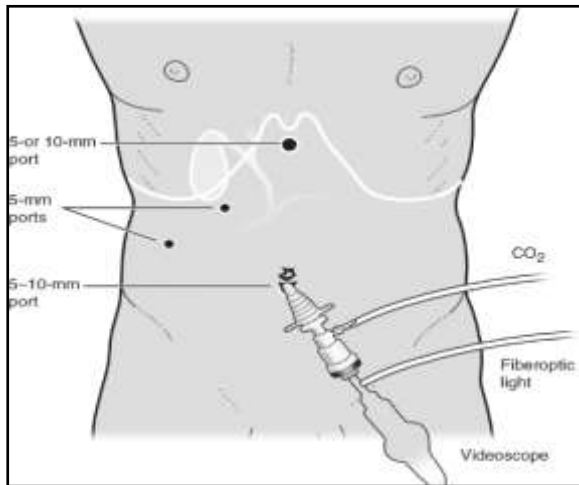


Figure (3): Port positions ⁽⁵⁾.

- 5-mm port laterally along the anterior axillary line for gallbladder fundus retraction.
- Traction & Lysis of Adhesion
- Dissection starts on the anterior edge of Hartmann's pouch.
 - Peritoneum of the superior leaf of the cystic pedicle is divided superficially as far back as the liver by pledget, Scissors, Hook or Maryland.
 - Dissection of Cystic Pedicle

- Separation of the cystic duct anteriorly from the cystic artery performed by opening the jaw of Maryland.
- Clipping of cystic artery
- Two clips are placed proximally on the cystic artery
 - Cystic artery is clipped and then divided by hook scissors
 - Artery is then grasped with a grasper on the gallbladder wall and then divided distal to the clips.
 - Ligation of Cystic Duct o Roeder or Meltzer extracorporeal slip knot is used o Clipping though easy but unsafe because of reports of internalization of clip and formation of Cat eye stones
- Dissection of Gallbladder from Bed
- Extraction of Gallbladder
- The gallbladder is extracted through the 11.0mm operating port inside a bag
 - Extraction inside a bag is recommended as a safeguard against stone loss and contamination of the exit wound.
 - Ovum forceps should be used to extract stones from inside the gallbladder.

Ending of the operation:

- Abdomen should be examined for any possible bowel injury or haemorrhage
- Remove the Instrument and then port
- Remove telescope leaving gas valve of umbilical port open.
- Remove port carefully and close the port wound.

Routine application of drainage tube is not required

Pure laparoscopic surgery (PLS) has been adopted in various fields. Compared with open surgery (OS), PLS has substantial advantages in terms of less blood loss, less pain, a lower morbidity rate, a shorter time to a postoperative diet, and a shorter hospital stay. Unfortunately, especially in the field of hepatobiliary and pancreatic (HBP) surgery, PLS has developed relatively slowly due to technical difficulties and a protracted learning curve ⁽⁵⁾.

Ovarian Cyst:

The complete laparoscopic approach for huge cyst is a feasible treatment when having a normal tumor marker profile and benign imaging appearance. In addition to the advantages of laparoscopic surgery, it is less invasive, with perfect cosmetic outcome and shorter hospital stay, which are particularly important for young women ⁽⁶⁾.

Selection of Case:

Before selecting any case for laparoscopy Ca-125 an ovarian cancer marker that may help to identify cancerous cysts in older women.

Hormone levels (such as LH, FSH, estradiol, and testosterone) may be checked to evaluate for associated hormonal conditions.

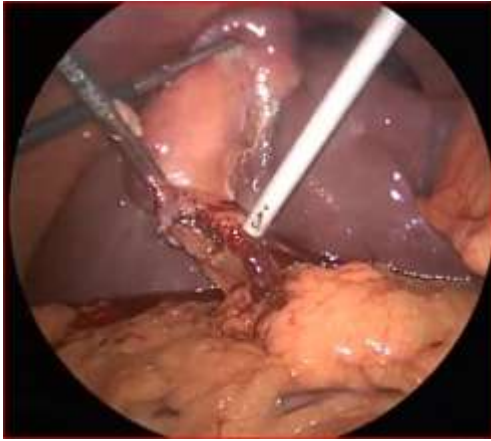

Figure (4): Laparoscopic cholecystectomy.

Table (1): Age incidence in acute abdomen

Age group (in years)	No. of cases	Percentage (%)
20-25	7	23.3%
26-30	9	30.0%
31-35	6	20.0%
36-40	8	26.7%
Total	30	100.00%

Table (2): Sex distribution in cases of acute abdomen

Sr. no	Gender	No. of cases	Percentages
1	Male	14	46.7%
3	Female	16	53.3%
	Total	30	100.0%

Indications:

- Laparoscopy is gold standard management of Ovarian Cyst.
- Oophorectomy in special circumstances e.g Ovarian Endometrioma.
- Malignancy is a Absolute contraindication

Post-procedural:

- Patients are instructed to walk immediately after the procedure and to continue their normal daily activities.
- All patients receive routinely antibiotics for on.

Statistical Analysis

Data were collected, revised, coded and entered to the Statistical Package for Social Science (IBM SPSS) version 20 and the following were done:

Qualitative data were presented as number and percentages while quantitative data were presented as mean, standard deviations and ranges.

3. Results

Table (3): Incidence of various pathologies in acute abdomen

Pathology	No. of cases	(%)
Acute appendicitis	8	26.7%
Acute cholecystitis	7	23.3%
Adhesive intestinal obstruction	3	10.0%
Negative laparoscopic exploration	3	10.0%
Rupture ectopic pregnancy	3	10.0%
Rupture ovarian cyst	2	6.7%
Perforated DU	2	6.7%
Pelvic inflammatory disease	1	3.3%
Meckel's diverticulum	1	3.3%
Total	30	100.0%

Table (5): Relation between pathology and age of acute abdomen cases

Pathology	Age groups (in years)			
	20-25	26-30	31-35	36-40
Acute appendicitis	4 (57.1%)	2 (22.2%)	2 (33.3%)	0 (0%)
Acute cholecystitis	1 (14.3%)	2 (22.2%)	0 (0%)	4 (50.0%)
Adhesive intestinal obstruction	0 (0%)	0 (0%)	1 (16.7%)	2 (25.0%)
Negative laparoscopic exploration	0 (0%)	1 (11.1%)	1 (16.7%)	1 (12.5%)
Rupture ectopic pregnancy	1 (14.3%)	1 (11.1%)	1 (16.7%)	0 (0%)
Rupture ovarian cyst	1 (14.3%)	1 (11.1%)	0 (0%)	0 (0%)
Perforated DU	0 (0%)	0 (0%)	1 (16.7%)	1 (12.5%)
Pelvic inflammatory disease	0 (0%)	1 (11.1%)	0 (0%)	0 (0%)
Meckel's diverticulum	0 (0%)	1 (11.1%)	0 (0%)	0 (0%)
Total	7 (100%)	9 (100%)	6 (100%)	8 (100%)
Chi-square test	23.579			
P-value	0.486 (NS)			

Table (4): Management policies for patients of acute abdomen

Management	No. of cases	Percentages
Therapeutic laparoscopy	22	73.3%
Laparotomy (conversion)	8	26.7%
Total	30	100.0%

Table (5): Comparison between radiological investigations and laparoscopy findings regarding diagnosis of acute abdomen

Diagnosis	Radiological	Laparoscopy	Test value	P-value	Sig.
Correct	18 (60.0%)	27 (90.0%)	7.200	0.007	HS
Incorrect	12 (40.0%)	3 (10.0%)			

Table (6): Incidence of laparoscopic complications in cases of acute abdomen

Complications	No of cases	Percentages
Non complicated	15	50.0%
Complicated	15	50.0%
Types of complications*		
Shoulder pain	4	26.7%
Wound gaping	3	20.0%
Subcutaneous emphysema	2	13.3%
Port site infection	2	13.3%
Major vessel injury	1	6.7%
Bowel injury	1	6.7%
Omental prolapse	1	6.7%
Port site hernia	1	6.7%

* Types of complications percentages was calculated from the 15 complicated patients

4. Discussion

This study for role of laparoscopy in acute abdomen included 30 cases of acute abdomen who presented to Ain Shams University Hospitals for emergency management. They were posted for emergency laparoscopy after necessary investigations.

1. Age incidence

In this study, patients included were from 20-40 years old. Maximum patients of acute abdomen were from age group 26 to 30 years i.e. 9 to 30 cases (30.0%). Next to follow is age group of 36 to 40 years, with 8 cases (26.7%). Age groups of 20-25 years are 7 cases (23.3%) and 31-35 years are 6 cases (20.0%).

2. Sex distribution

Among 30 patients of acute abdomen, 16 were females (53.3%) and 14 were males (46.7%). More number of females is due to more incidence of acute cholecystitis in females.

3. Incidence of various pathologies in acute abdomen

Cases of acute appendicitis are actually the most common cause of acute abdomen i.e. 8 of 30 cases (26.7%). Acute cholecystitis was the second most frequent cause of acute abdomen in our study i.e. 7 of

30 cases (23.3%). Age groups having acute cholecystitis commonly were 20 to 25 years i.e. 4 of cases (50.0%). Next to acute appendicitis is acute cholecystitis with 7 cases (23.3%), maximum of which were from age group of 31 to 35 years i.e. 4 cases (66.7%).

Waclawiczek et al. ⁽¹⁰⁾ in their study of 172 patients acute inflammation of gall bladder was seen in 48 patients (27.9%) while ulcer perforation was present in 9 patients (5.2%). Scott and Rosin ⁽¹¹⁾ in their study of 67 patients, of which 4 were of perforated duodenal ulcer (5.9%) and 2 were of torsion ovarian cyst (2.9%). These findings also correlate with this study.

4. Laparoscopic treatment of perforated ulcer

In this study, laparoscopic exploration was done successfully for all patients; therapeutic laparoscopy was done to 22 cases (73.3%) and 8 cases (26.7%) out of 30 were converted to laparotomy.

Siu et al. ⁽¹²⁾ in their study of 121 patient of which 98 (81%) were male. They did laparoscopic repair of perforated peptic ulcer. Mean postoperative hospital stay was 6 days. Lorand et al. ⁽¹³⁾ in their study of 59 cases of perforated ulcers, of which 3 (6.89%) required conversion to open surgery and remaining 56 were treated by laparoscopy. Mean post operative stay was 8.2 +/- 4 days. Findings of above studies correlate with this study findings but differences seen may be due to small number of cases in this study.

5. Laparoscopic management of acute abdomen

In this study, total laparoscopic management was possible in 22 cases (73.3%) while laparotomy conversion was done in 8 cases (26.7%).

Waclawiczek et al. ⁽¹⁰⁾ studied 172 cases of acute abdomen using laparoscopy. They found conversion rate to be 2.7% which is less than our study. Difference in percentages may be due to difference in number of cases. Navej et al. ⁽¹⁴⁾ studied 231 cases in which unnecessary laparotomy was avoided in 6.5% patients. This correlates with our study.

6. Comparison between findings on radiological investigations and laparoscopic findings

In this study, 3 cases (10.0%) presented as adhesive small bowel obstruction, 1 case (3.3%) with inflamed Meckels diverticulum and 2 cases (6.7%) as case of rupture ovarian cyst. All these findings were missed on radiological investigations, but were diagnosed accurately on laparoscopy. So diagnostic accuracy of radiological investigations was 60.0% (18 out of 30 cases) while the same for laparoscopy was 90.0% (27 out of 30 cases).

Zantut et al. ⁽¹⁵⁾ in their study of 45 patients, 28 cases had nontraumatic acute abdomen. The laparoscopic and ultrasound accuracy were 97.8% and 53% respectively.

7. Complications of laparoscopy in acute abdomen

In this study, complications were seen in 15 cases (50.0%), 4 cases (26.7%) had shoulder pain which were treated accordingly, 3 cases (20.0%) had wound gaping, subcutaneous emphysema and port site infection cases where 2 cases (13.3%) each and bowel injury, omental prolapse and port site hernia cases were 1 case (6.7%) each.

Waclawiczek et al. ⁽¹⁰⁾ studied 172 cases in which complications rate was 11%. While in this study complication occurred in 1 of 9 cases of acute small bowel obstruction (11.1%). This correlates with this study. Probably the difference in percentages is due to less number of cases of acute small bowel obstruction in this study.

Conclusion

Following are the conclusions derived from our study:

1. Diagnostic Laparoscopy is helpful in confirming a diagnosis made on clinical grounds and laboratory evaluation.
2. It reduces chances of unnecessary laparotomies.
3. It is superior to imaging modalities like CT abdomen for staging of GI malignancies.
4. It reduces patient suffering by establishing definitive diagnosis and thus early initiation of definitive treatment.
5. It is therapeutic in some of the cases by performing definitive procedure.
6. Diagnostic Laparoscopy is safe, less time consuming, cosmetic with lesser complications and lesser morbidity and mortality.
7. Diagnostic Laparoscopy is specifically important in females of reproductive age group with pain abdomen to confirm or refute pelvic pathology.

References

1. Cervellin G, Mora R, Ticinesi A, et al. Epidemiology and outcomes of acute abdominal pain in a large urban Emergency Department: retrospective analysis of 5, 340 cases. *Annals of Translational Medicine*. 2016; 4(19): 362.

2. Mazzei MA, Guerrini S, Cioffi Squitieri N, et al. The role of US examination in the management of acute abdomen. *Critical Ultrasound Journal*. 2013; 5(1): S6.
3. Stewart KI, Fader AN. New Developments in Minimally Invasive Gynecologic Oncology Surgery. *Clinical Obstetrics and Gynecology*. 2017; 60(2): 330-348.
4. Justin V, Fingerhut A, Uranues S. Laparoscopy in Blunt Abdominal Trauma: for Whom? When? and Why? *Current Trauma Reports*. 2017; 3(1): 43-50.
5. Hori T, Oike F, Furuyama H, et al. Protocol for laparoscopic cholecystectomy: Is it rocket science? *World Journal of Gastroenterology*. 2016; 22(47): 10287-10303.
6. de Oliveira AL. Video laparoscopic appendectomy: a prospective analysis of 300 cases, 12: 245-267.
7. Tupper-Carey DA, Fathil SM, Tan YKG, et al. A randomised controlled trial investigating the analgesic efficacy of transversus abdominis plane block for adult laparoscopic appendectomy. *Singapore Medical Journal*. 2017; 58(8): 481-487.
8. Naqvi SEH, Zaka-ur-Rab A, Islam N, et al. A Prospective Study of Altered Inflammatory Response and Its Clinical Outcome following Laparoscopic and Open Cholecystectomy. *Iranian Journal of Medical Sciences*. 2017; 42(4): 347-353.
9. Baradwan S, Sendy F, Sendy S. Complete Laparoscopic Extirpation of a Giant Ovarian Cyst in an Adolescent. *Case Reports in Obstetrics and Gynecology*. 2017; 2017: 7632989.
10. Waclawiczek HW, Schneeberger V, Bekk A, Dinnewitzer A, Sungler P, Boeckl O. Value of diagnostic laparoscopy and minimal invasive procedures in acute abdomen. *Zentralbl Chir*. 2011; 122(12):1108-12.
11. Scott HJ, Rosin RD. The influence of diagnostic and therapeutic laparoscopy on patients presenting with an acute abdomen. *J R Soc Med*. 2012; 86 (12):699-701.
12. Siu WT, Leong HT, Law BK, Chau CH, Li, AC, Fung KH, Tai YP, Li MK. Laparoscopic repair of perforated peptic ulcer a randomized controlled trial. *Ann Surg* 2014; 235; 313-319.
13. Lorand I, Molinier N, Sales JP, Douchez F, Gayral F. Result of laparoscopic treatment of perforated viscus. *Chirurgiae*. 2010; 124 (2) : 149-53.
14. Navej F, Tassetti S, Scotry F, Mutter L et al. Laparoscopic management of acute peritonitis. *British Journal of Surgery*. 2014; 85: 32.
15. Zantut LF, Zantut PE, Rodrigues AJ, Birolini D. Comparative analysis of the diagnostic value of ultrasound and laparoscopy in acute abdomen. *AMB Rev Assoc Med Bras*. 2012; 37 (3):143-9.

9/16/2019