



Coragen induced toxicity and the ameliorative effect of an *Origanum majorana* L. in male albino Rats

Noha M. Meligi, Hanaa Fawzy Hassan and Honyda, S.M.

Zoology Department, Faculty of Science, Minia University 61519, Minia, Egypt.

*Correspondence: noha.melege@mu.edu.eg hanaafawzy78@yahoo.com

Abstract: Pesticides are chemical substances used to kill variety of different animal pests. Because of they are sprayed across whole agricultural fields, they can affect many species other than their goal species. Pesticides encompass different types of compounds such as insecticides. Worldwide, insecticides are known to be a main reason behind the increase in the agricultural production in the last century. However, insecticide class comes with a specific set of environmental concerns. Therefore, insecticides must be estimated for their toxicity. The present work aimed to evaluate the toxic effects of the insecticide, Coragen and the ameliorative effects of an *Origanum majorana* L. suspension on male albino rats. The administration of a sub-lethal dose of Coragen (2000 mg/kg b.wt. orally three times a week for 30 days) was associated with significant inhibition of glutathione peroxidase (GPx) and superoxide dismutase (SOD) enzyme activity and enhanced lipid peroxidation. Moreover, a significant increase in the concentration of aspartate aminotransferase (AST) and alanine aminotransferase (ALT) enzymes and low-density lipoprotein cholesterol (LDL-C) were detected. In contrast, there were a decline in the concentrations of total protein, high-density lipoprotein cholesterol (HDL-C) and albumin in the present study in response to the insecticide. In addition, the histopathological changes of liver, spleen and lung by Coragen were evaluated. Treatment with (5 g/kg b.wt.) suspension of *Origanum majorana* L given orally, 3times/week for 4 weeks, showed a probable way to mitigate the Coragen induced toxicity.

[Noha M. Meligi, Hanaa Fawzy Hassanand Honyda, S.M. **Coragen induced toxicity and the ameliorative effect of an *Origanum majorana* L. in male albino Rats.** *J Am Sci* 2019;15(9):33-44]. ISSN 1545-1003 (print); ISSN 2375-7264 (online). <http://www.jofamericanscience.org>. 5. doi: [10.7537/marsjas150919.05](https://doi.org/10.7537/marsjas150919.05).

Keywords: Ooxidative stress, biochemical parameters; histological changes; Coragen; albino rats; *Origanum majorana*.

1. Introduction

Coragen 20% SC is a new chemical insecticide product whose active substance is Chlorantraniliprole. This product is applied on a large numbers of crops against a huge numbers of pests of the order Lepidoptera and some species as Isoptera, Coleoptera, and Diptera. Chlorantraniliprole belongs to a novel class of selective mode of action of pesticides (anthranilic diamides) with a new mechanism of action (Kar et al. 2013). These insecticides act as ryanodine receptor modulators (ryanoids) through stimulation the release of calcium stores from the intracellular stores like the sarcoplasmic reticulum of muscle cells, initiating many complications like paralysis and reduced regulation (Dutta et al. 2014).

Pesticides can produce reactive oxygen species (ROS) which stimulate the production of free radicals across inhibition the activity of the antioxidant defense system. Oxygen free radicals are known to induce lipid peroxidation through the reaction with polyunsaturated fatty acids, which subsequently, inducing peroxidation of lipids (Gandhi et al. 2012).

Guyton and Hall (2006) reported that the liver is a vital organ in the body concerned with the metabolic

processes essential for maintaining energy levels and the permanence of metabolism in the body. In addition, the liver is considered the main organ responsible for detoxification of many toxic substances reducing their toxicity (Hodgson, 2004). Research done by Dutta et al. (2014) showed elevated serum levels of the enzyme aspartate aminotransferase (AST) in Charles Foster rats after exposure to a sub-lethal dose of Coragen (1000 mg/kg body weight). This change in enzyme levels is a sign of the cellular and tissue injury resultant from exposure to many insecticides in experimental rats, possibly due to alteration of specific molecular pathways.

Herbal and natural products derived from plant extracts are one of the most common forms of alternative and complementary therapies. Recent studies have indicated that these herbal and natural products exhibit antioxidant properties against many toxic materials and show lesser side effects than synthetic drugs. *Origanum majorana*, also known as sweet marjoram, is an evergreen herbaceous plant belonging to the family Lamiaceae (Shati 2011). It was grown in Egypt over 3,000 years ago and most countries around the world and used widely in the

world as culinary herbs (Ramadan et al. 2013). Additionally, *Origanum majorana* have been used conventionally as they have antilipidemic, antiulcer antimicrobial and antihyperglycemic properties. Additionally, has been employed for the treatment of various diseases, being used as an expectorant, sudorific, stomachic, emmenagogic, stimulant, antiseptic, hepatoprotective or nephroprotective agent (Pimple et al. 2012). The target from the present investigation was to evaluate the toxic effects of a sub-lethal dose of Coragen on the antioxidant defense system, hepatic function and histopathological changes in the liver, the spleen and the lung as well as the protective role of *Origanum majorana* in male albino rats.

2. Materials and Methods

Experimental animals

Thirty adult male albino rats (Sprague-Dawley, *Rattus norvegicus*) at the age 6-8 weeks, weighing 150–200 g were obtained from Egypt, at the animal house of the research laboratory. All animals had access to an ordinary food and water ad libitum. The rats were left in plastic cages in a well-ventilated room (temperature $25^{\circ}\text{C} \pm 3$) for 2 weeks prior the commencement of the experiment as an acclimatization period.

Test pesticide

Chlorantraniliprole (trade name: Coragen 20% SC) was purchased from the Ministry of Agriculture, Agrimatco Company, Minia, Egypt. The tested sub-lethal doses of Coragen (2000 mg/kg body) was administered orally via a stainless-steel stomach tube three times a week for 30 days.

Preparation of plant material

Origanum majorana (dried plant) was purchased from a local market in Egypt. The samples were washed with distilled water, crushed mechanically and then suspended in distilled water until use (5 g/kg body weight).

Experimental protocol

Rats were divided into three groups (10 rats each). Group 1 (control) 1 ml of distilled water orally three times a week for 30 days. Group 2 (Coragen-treated group) received 1ml of Coragen at a dose of 2000 mg/kg, administered orally three times a week for 30 days. Group 3 (Coragen + *Origanum majorana*-treated group) received Coragen orally three times a week for 30 days at the same dose as in group 2, but mixed with 0.5 ml of an *Origanum majorana* suspension (5 g/kg).

Measurement of body weights

All animals were weighed with an automatic balance (AND GX-600, Japan) at the beginning of the experiment and before dissection.

Blood sampling

At the end of the period of experimental treatment (30 days), the rats in each group were fasted overnight and then sacrificed via cervical decapitation to collect blood samples. Plasma samples were separated through centrifugation of the blood for 15 min at 3000 rpm using EDTA as an anti-coagulant. More blood samples were centrifuged at 3000 rpm for 15 min to get Serum samples. The plasma and serum samples were held at -80°C for subsequent biochemical analysis.

Biochemical analysis

Plasma lipid peroxide (LPx) levels and glutathione peroxidase (GPx) activity were determined calorimetrically following Ohkawa et al. (1979) and Paglia and Valentine (1967), respectively, using bio-diagnostic kits. Plasma superoxide dismutase (SOD) activity was analyzed according to the method adopted by Marklund and Marklund (1974). According to the method of Bergmeyer et al. (1986), Serum alanine aminotransferase (ALT) and aspartate aminotransferase (AST) activities were analyzed calorimetrically with a spectrophotometer, using ERBA Diagnostics Mannheim GmbH kits. Serum total protein and albumin were determined according to Young and Friedman (2001) and Leonard et al. (1971), respectively, using Diamond Diagnostics kits. According to the method of Badimon et al. (1990). Serum high-density lipoprotein cholesterol (HDL-C) and low-density lipoprotein cholesterol (LDL-C) levels were determined using kits developed by Architect Diagnostics kits.

Histopathology

For histopathological examination, the liver, the spleen and the lung samples were isolated and fixed in 30% formal saline for 24 h, processed through a graded ethanol series, and embedded in paraffin. The paraffin sections were cut into slices 5 microns thick and stained with hematoxylin and eosin for light microscopy examination. The sections were viewed and photographed using an Olympus light microscope (Olympus CH20BIMF200, Olympus Optical Co. Ltd., Japan) with an attached camera (MicroCam PHD-5MP).

Statistical analysis

Data were analyzed using SPSS version 22 for Windows. The significance was calculated via one-way analysis of variance (ANOVA), followed by Tukey's multiple comparison procedure, to calculate significance. Data were expressed as the mean \pm SD, and $P < 0.05$ was considered as the level of significance.

3. Results

Morbidity and mortality

After sub-lethal Coragen exposure (2000 mg/kg, 3times/week/4 weeks, the animals indicated

symptoms of toxicity, like closed eyes, nose bleeds, spasms of muscles in legs and arms (muscle paralysis) and overall weakness of body as seen in (Fig. 1).

Body weight

The net weight of body gain of rats treated with Coragen alone was lower than in the other experimental rats.

Evaluation of biochemical parameters

Changes in oxidative stress parameters

Data of some oxidative stress enzymes are shown in Table 1, the study showed a significant

elevation ($P < 0.05$) in the concentration of LPx in the Coragen-treated rats in comparison with the control group. In the other words, the data showed a significant decrease in the GPx and SOD in the treated group with Coragen in comparison with respective control. Moreover, the results showed significant alterations ($P < 0.05$) in the activity of SOD and GPx enzyme and LPx level, after treatment with *Origanum majorana*.

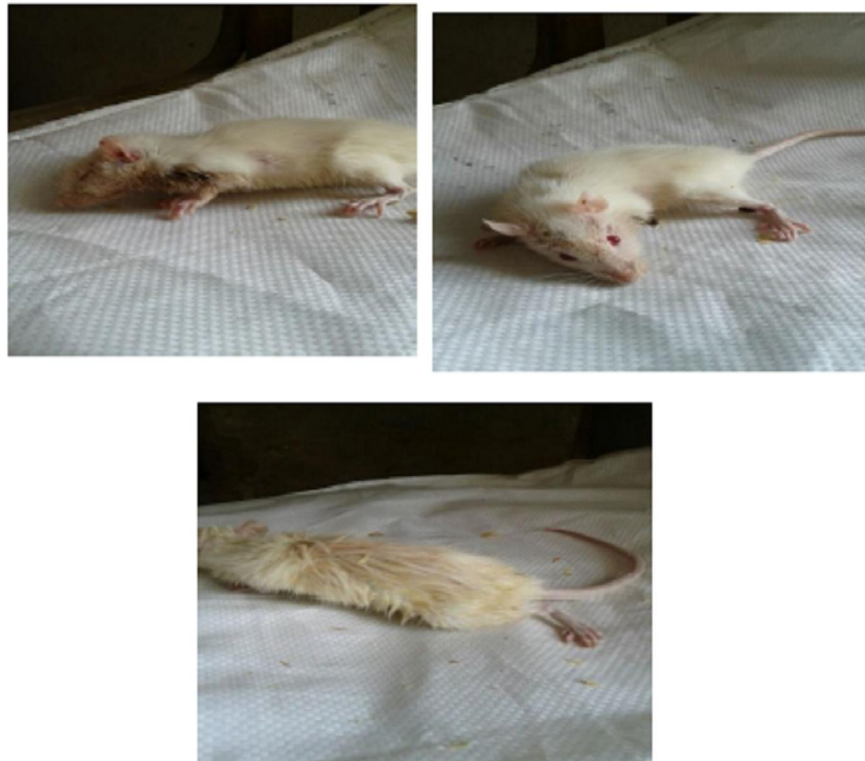

Fig (1): Digital images showing the signs of toxicity in the Coragen-treated group.

Table (1): Plasma LPx concentration and activity of SOD and GPx enzyme in control and experimental rats.

Groups Parameters	Control group	Coragen-treated group	Coragen + <i>Origanum majorana</i> -treated group
LPx (nmol/ml)	4.48± 1.37	10.62± 0.46 ^a	5.38± 0.87 ^b
GPx (U/L)	445.65± 57.13	143.90 ±27.42 ^a	218.00 ± 40.57 ^{a,b}
SOD (U/ml)	217.52± 34.98	163.90± 25.82 ^a	198.50±8.10 ^b

Values are expressed as (means ± SD) for 6 rats/group. Significant at ($P < 0.05$). ^a Comparison of the control with other groups. ^b Comparison of the Coragen-treated group with the Coragen + *Origanum majorana*-treated rats.

Changes in hepatic function and the lipid profile

Results in Tables (2) summarized the values of some biochemical parameters. There were statistically significant increases ($P < 0.05$) in ALT, AST activities and LDL-C levels in the Coragen experimental group compared with the control group. The varied trends were observed in case of albumin, total protein, and HDL-C concentrations in the Coragen-treated rats

matched with those in the control rats. Moreover, Table (2) showed significant decreases in the activity of AST, LDL-C and ALT levels, with a significant increases in the total protein, albumin and HDL-C concentrations in the Coragen + *Origanum majorana*. group compared with those in the Coragen group ($P < 0.05$).

Table (2): ALT and AST serum enzyme activity and total protein, albumin, HDL-C and LDL-C concentrations in control and experimental animals

Groups Parameters	Control group	Coragen-treated group	Coragen + <i>Origanum majorana</i> -treated group
ALT (UL)	37.46 ± 2.61	106.60 ± 2.91 ^a	77.62 ± 3.11 ^{a,b}
AST (UL)	47.16 ± 4.77	65.70 ± 3.46 ^a	53.37 ± 1.77 ^{a,b}
Total protein (g/dl)	8.35 ± 0.50	6.74 ± 0.39 ^a	8.28 ± 0.76 ^b
Albumin (g/dl)	6.04 ± 1.62	3.58 ± 0.36 ^a	7.17 ± 0.16 ^b
HDL-C (mg/dl)	31.80 ± 3.01	24.00 ± 5.84 ^a	42.75 ± 2.96 ^{a,b}
LDL-C (mg/dl)	36.40 ± 1.17	41.70 ± 5.57 ^a	33.87 ± 2.23 ^b

Values are expressed as (means ± SD) for 6 rats/group. Significant at ($P < 0.05$). ^a Comparison of the control with other groups. ^b Comparison of the Coragen-treated group with the Coragen + *Origanum majorana*-treated rats.

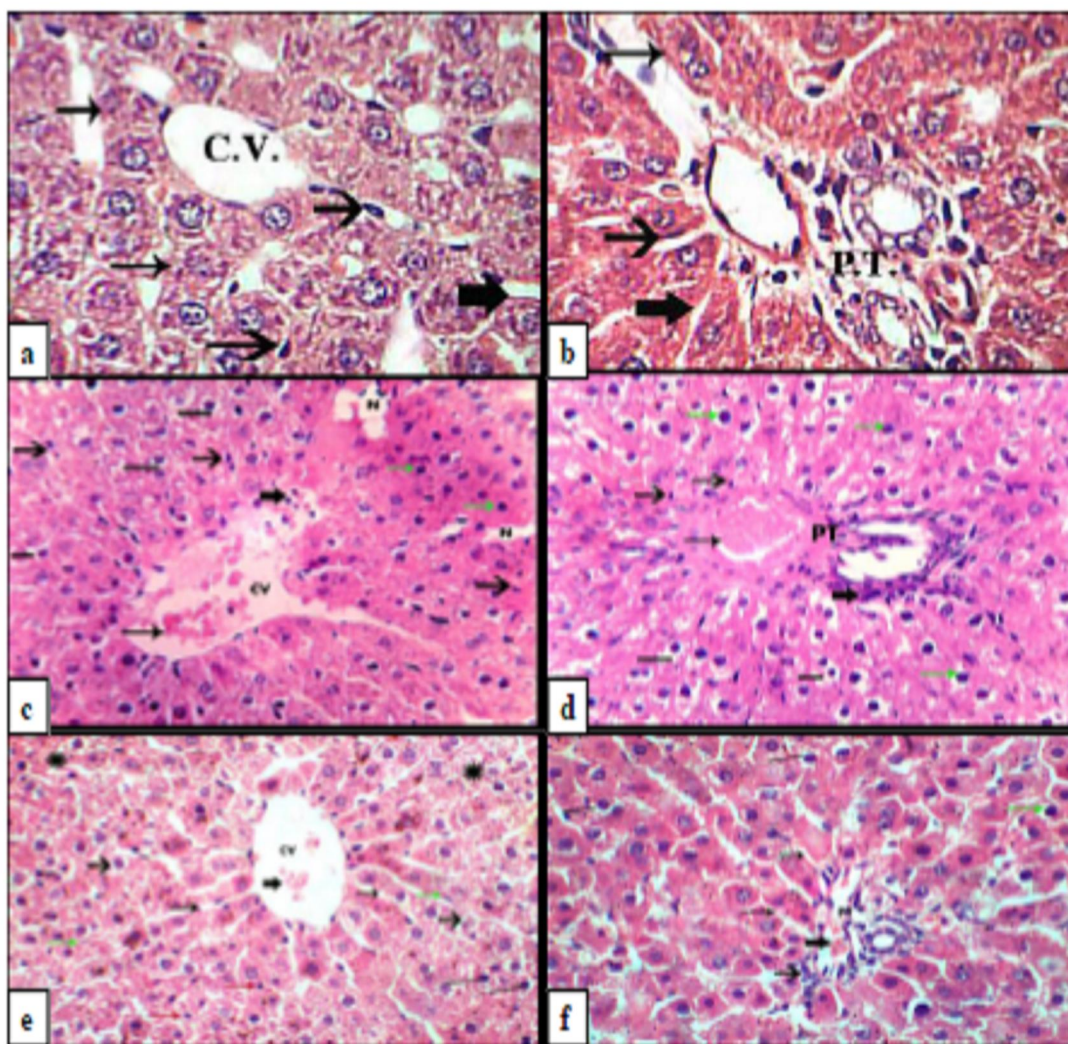


Fig.2: **a)** Liver of control group, showing normal hepatocytes (thin arrows), central vein (C.V.), sinusoids (thick arrows) and kupffer cells (moderate arrows). (H & E, × 400). **b)** Liver of control group, showing normal hepatocytes (thin arrow), sinusoids (thick arrow), kupffer cells (moderate arrow) and portal tract (P.T.). (H & E, × 400). **c)** Liver of Coragen-treated group, showing distribution of hepatocyte strands, vacuolation of cytoplasm (lines), interrupted wall of central vein (CV), central vein was congested with haemolysed blood (thin arrow) and infiltrated with lymphocytes (thick arrow), there were activated kupffer cells in sinusoids (moderate arrows), hepatocellular necrosis (N) in some areas and nuclear pyknosis (green arrow). (H & E, × 400). **d)** Liver of Coragen-treated group, showing

distribution of hepatocyte strands, portal tract (PT) was congested with haemolysed blood (thin arrow) and infiltrated with lymphocytes (thick arrow), vacuolation of cytoplasm (lines), activated kupffer cells in sinusoids (moderate arrows) and nuclear pyknosis (green arrow). (H & E, $\times 400$). **e**) Liver of Coragen + *Origanum majorana*-treated group, showing arranged wall of central vein (C.V.) with few congestion (thick arrow), arranged hepatocyte strands in some areas (thin arrows), but there was few distribution of hepatocyte strands in another areas (star), normal kupffer cells (green arrows) but there were some activated kupffer cells (red arrows), few nuclear pyknosis (lines) and less vacuolation (moderate arrow). (H & E, $\times 400$). **f**) Liver of Coragen + *Origanum majorana*-treated group, showing nearly normal appearance of portal tract (PT) with few haemolysed blood (thick arrow), few lymphocyte aggregation (moderate arrow) around portal tract, arranged hepatocyte strands (thin arrows), few nuclear pyknosis (green arrow) and less vacuolation (lines). (H & E, $\times 400$).

Histopathological findings in the liver

The examination of specimens of liver samples of control (Figs. 2a & 2b) were matched with that in treated animals, the liver sections of the Coragen-treated group showed histopathological changes such as distribution of hepatocyte strands, vacuolation of cytoplasm, the appearance of a necrotic area, congestion of central vein which has interrupted wall and portal tract with infiltration of lymphocytes, activated kupffer cells in sinusoids and nuclear pyknosis (Figs. 2c & 2d). However, the liver sections of rats in the Coragen + *Origanum majorana*-treated group showed some histopathological improvements such as arrangements in hepatocyte strands in some areas and in the wall of central vein accompanied by few congestions in the central vein and in the portal tract, few accumulations of lymphocytes in the portal space, less cytoplasmic vacuolation of hepatocytes and less nuclear pyknosis (Figs. 2e & 2f).

Histopathological findings in the spleen

Compared with those in the control group (Figs. 3a & 3b), the spleen sections of the Coragen-treated group showed histopathological changes such as disruption of white pulp and red pulp with many vacuolated cells, congested blood sinuses in red pulp, aggregation of erythroid elements and nanoparticles,

highly thickened arterial wall with narrow lumen, some degenerated and necrotic areas and highly dilated and congested vein with infiltrated lymphocytes (Figs. 3c & 3d & 3e). While, the spleen sections of rats in the Coragen + *Origanum majorana*-treated group showed some histopathological improvements such as differentiation between white and red pulps, nearly normal appearance of the artery with less thickness of arterial wall, less vacuolation and less degeneration of the spleen tissue (Fig.3f).

Histopathological findings in the lung

Compared with those in the control group (Figs. 4a & 4b), the lung sections of the Coragen-treated group showed histopathological changes such as severe thickness of the wall of alveoli with haemolysed blood and into the bronchus which accompanied by infiltrated lymphocytes, congestion and thickness of the wall of pulmonary artery, wide area of bronchial associated lymphoid tissue (BALT) and necrosis in some areas of lung tissue (Figs. 4c & 4d). While, the lung sections of rats in the Coragen + *Origanum majorana*-treated group showed some histopathological improvements such as moderate thickness of wall of alveoli in some areas with few haemolysed blood and reduction in size of BALT (Figs. 4e & 4f).

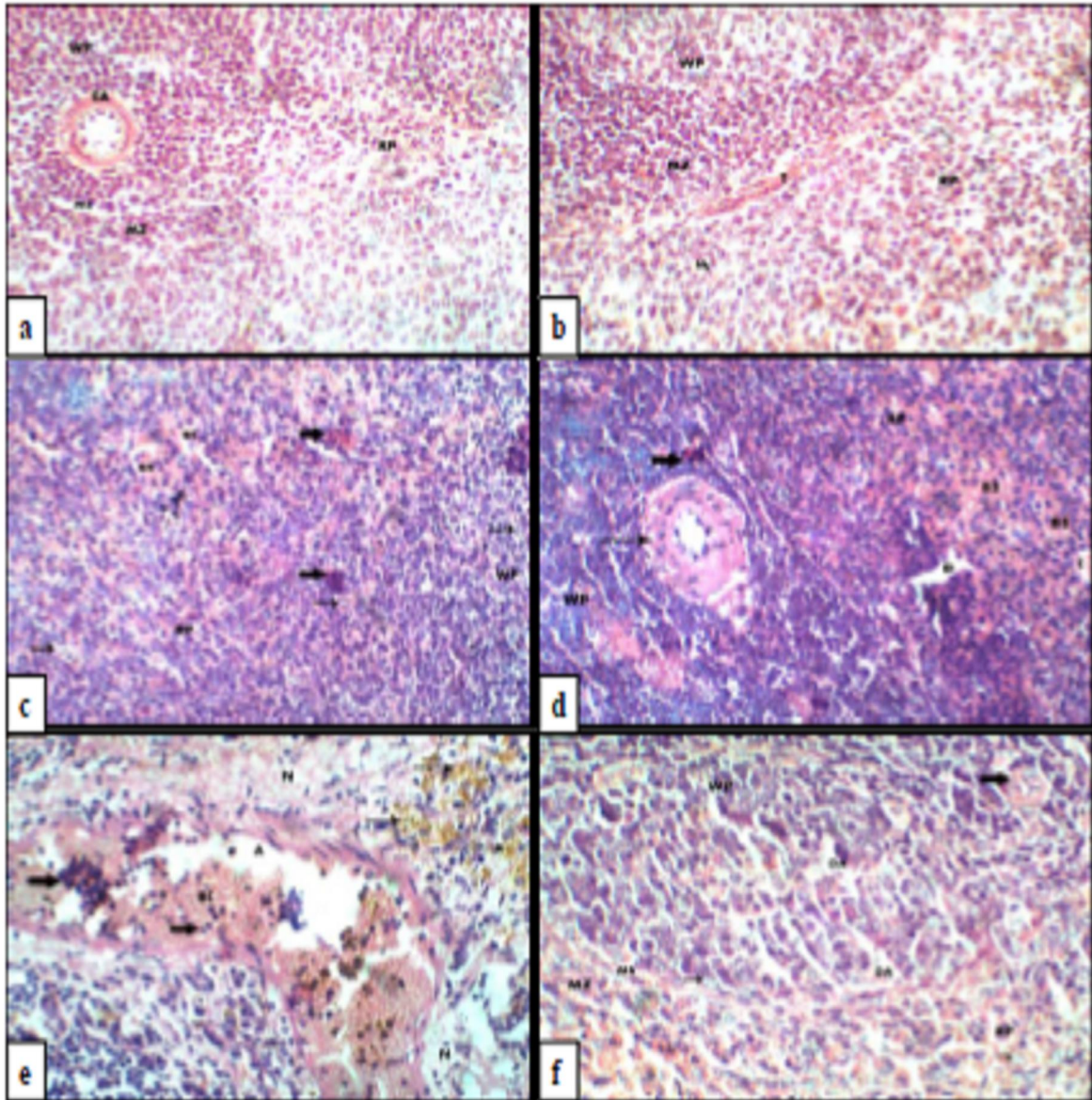


Fig.3: **a)** spleen of the control group showing, normal spleen architecture with its two major components; white pulp (WP) and red pulp (RP). The marginal sinus (MS) Separates the white pulp and marginal zone (MZ). The white pulp has eccentric artery (EA). (H & E, 400X). **b)** spleen of the control group showing, splenic sinuses (SS) in The red pulp and part of the fibrous trabecula (T) is also seen. (H & E, 400X). **c)** spleen of the Coragen-treated group showing, disturpted white pulp (WP) and red pulp (RP) with many vacuolated cells (thin arrows), There is no marginal sinus (MS) which separates white pulp and marginal zone, There were congested blood sinuses (BS) in red pulp and aggregation of erythroid elements (thick arrows) (H & E, 400X). **d)** spleen of the Coragen-treated group showing, some degenerated areas (D) and highly thickened arterial wall with narrow lumen (thin arrow). (H & E, 400X). **e)** spleen of the Coragen-treated group, showing highly dilated vein (DV) with blood congestion (BC) and lymphocytes infiltration (thick arrows). Also, there were many necrotic areas (N). Nanoparticles (thin arrows) are also seen. (H & E, 400X). **f)** spleen of the Coragen + *Origanum majorana*-treated group, showing some clear signs of spleen tissue repair, the red and white pulps appeared with more defined outlines like marginal sinus (MS) and marginal zone (MZ), less thickness of arterial wall (thick arrow) but some degenerated areas (DA) and some vacuolated cells (thin arrows) were still detected. (H & E, 400X). 4.

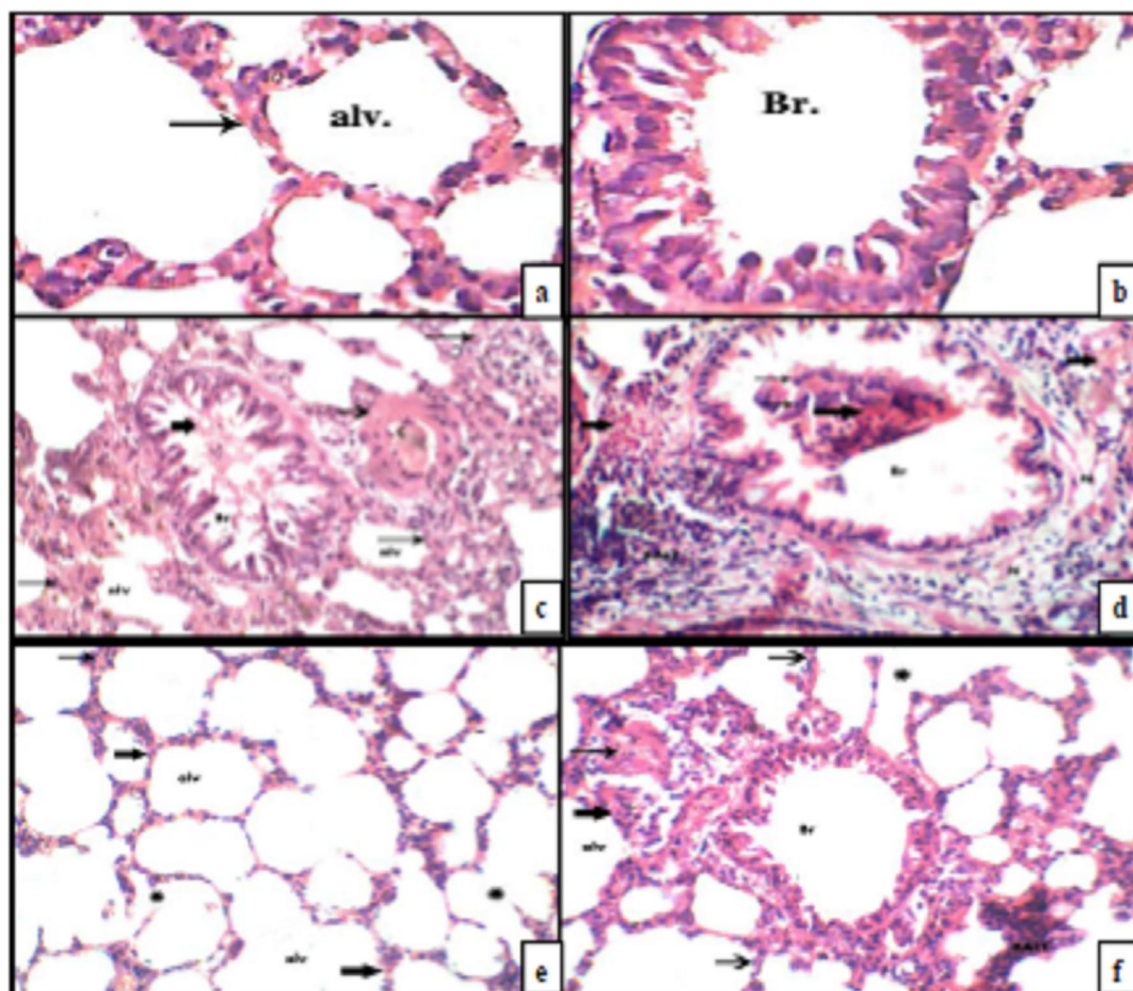


Fig.4: **a)** lung of the control group showing alveoli (alv.) with normal thickness of the wall (thin arrow) (H & E, $\times 400$). **b)** lung of the control group showing normal bronchus (Br.) (H & E, $\times 400$). **c)** lung of the Coragen-treated group showing severe thickness of wall of alveoli (alv.) (thin arrows), haemolysed blood into the bronchus (Br.) (thick arrow), congestion (C) in pulmonary artery and thick arterial wall (moderate arrow). (H & E, $\times 400$). **d)** lung of the Coragen-treated group showing, tissue destruction of alveoli with haemolysed blood, inflammation in the wall of alveoli and into the bronchus (Br.) (thick arrows), infiltration of lymphocytes into the bronchus (thin arrows), wide area of bronchial associated lymphoid tissue (BALT) and necrosis (N) in some areas of lung tissue. (H & E, $\times 400$). **e)** lung of the Coragen + *Origanum majorana*-treated group, showing nearly moderate thickness of wall of alveoli (alv.) (thick arrows) with rupture in some areas of alveoli (stars) and fewer haemolysed blood (thin arrow). (H & E, $\times 400$). **f)** lung of the Coragen + *Origanum majorana*-treated group, showing some improvement in lung tissue represented in reduction in size of BALT when compared with Coragen-treated group, no haemolysed blood into bronchus (Br.), nearly moderate thickness of wall of alveoli (moderate arrows) except in some areas (thick arrow), fewer haemolysed blood in wall of alveoli (thin arrow) and rupture in some areas of alveoli (stars). (H & E, $\times 400$).

4. Discussion

Globally, widespread application of pesticides is generally accompanied by severe pollution and health hazards. It has been demonstrated that several pesticides in common use can produce highly toxic and adverse effects on certain organs and other

biological systems when tested on different types of experimental animals, either through their direct action or via the generation of free radicals that damage various tissue components (El-Demerdash 2011). Many factors induce oxidative stress starting from disturbances in the stability between the levels of

oxidants and antioxidants to tissue impairment. Increased oxidative stress can lead to many complications including lipid peroxidation which is a widely indicator of oxidative stress (Agrawal and Sharma 2010). The present study revealed the occurrence of oxidative stress and an increase in plasma LPx levels induced by Coragen administration. Dutta et al. (2014) reported that the levels of thiobarbituric acid-reactive substances (an indicator of LPx levels) increase in rats serum as a result of Coragen treatment, causing oxidative stress owing to the liberation of free radicals and, consequently, alteration of the antioxidant protection system.

The results of the present investigation indicated significant decreases in Gpx and SOD enzyme activities in the plasma of Coragen-treated rats compared with those in the control rats. In contrast to our results, Bantu et al. (2013) found that Coragen significantly increased the activities of the Gpx and SOD enzymes in the tissues of Coragen-treated fish. These chemicals might be interacting primarily with tissues, resulting in a rise or fall of enzyme activities via increases in reactive oxygen species, H₂O₂ accumulation (Halliwell and Gutteridge 1999) and superoxide anion formation (El-Shafey et al. 2011) in the fishes as a result of stress conditions.

Hepatic tissues is primarily responsible for the metabolic processes for saving and preserving the energy required for all vital processes in the body. Moreover, the liver is the main place of biotransformation, through which a detoxication of toxic substances occurred, either changed into a non-toxic or less damaging element. Changes in hepatic enzymes (ALT and AST) are a sign of the toxicity in the hepatic and leads to alteration in the hepatic tissues resulting from exposure of the animals to insecticides, mainly due to changing in the specific molecular paths (Dutta et al. 2014). The obtained results showed significant elevation of liver enzyme levels in Coragen-treated rats. The obtained data were parallel with the finding of Uzun and Kalender (2013), which indicated an increase in the activity of the ALT and AST enzymes in the blood of chlorpyrifos-treated rats. Moreover, Gathwan et al. (2013) reported that organophosphorus insecticides conjugate with the natural complement of aminotransferases, acid phosphatases and alkaline phosphatases in the body, causing significant elevation of these enzymes in plasma and the liver. Other studies have showed that the raise of liver enzyme activities may be related to various factors. Those factors have summarised as liver dysfunction, with a consequent decrease in the biosynthesis of the enzyme and altered membrane permeability, permitting enzyme leakage into the blood (Abd-

Elhady and Abou-Elghar 2013). Our study indicates that the insecticide Coragen increased the levels of ALT and AST, which could be due to hepatotoxicity, subsequently leading to an impairment in the permeability, and the release of lysosomal enzymes, increasing the discharge of enzymes.

The present study demonstrated significant decreases in the levels of total protein, albumin and HDL-cholesterol and an increase in the LDL-cholesterol level in the serum of rats exposed to Coragen compared to controls. Relating to protein profile, the decrease in the protein content may be due to the toxic effects of pesticides through disturbance of protein synthesis along with disturbance of kidney function and may also be attributed to the utilization of free amino acids in gluconeogenesis to compensate for the energy need of animals under chemical stress (Mostafalou and Abdollahi 2013).

According to the results of Bantu et al. (2013), the levels of glucose, glycogen and lipids decrease after a sub-lethal dose of Coragen is administered to fishes. These authors explained that due to the starvation or low accessibility of carbohydrates (glucose, glycogen), fatty acids will work as a source of replaced energy for subsidiary the physiological roles of the body. The lipid level declines as a result of the consumption of lipids to meet energy demands under insecticide stress. Comparable findings were obtained in another study (Ambali et al. 2011) in which organophosphate insecticides, such as chlorpyrifos, were found to decrease serum HDL-cholesterol and elevate serum LDL-cholesterol in treated rats. There are two sites for synthesization high density lipid-cholesterol (HDL-cholesterol), mainly the hepatic tissues and cells of intestine. The principle function of HDL-cholesterol through efflux of cholesterol from cells and tissues and return it to the liver in the form of bile acids. Low HDL-cholesterol may be produced due to chlorpyrifos-induced hepatic damage, which causes impairment of lipoprotein synthesis. On the other hand, high LDL-cholesterol may be produced due to exposure to insecticides that suppress the development of novel LDL receptors, by this means diminishing the intake of LDL-cholesterol by the cells. Additionally, the increase in LDL-cholesterol recorded in chlorpyrifos-treated rats, accompanied by low VLDL-cholesterol levels, suggests that exposure to chlorpyrifos stimulates the deleterious conversion of some VLDL-cholesterol to LDL-cholesterol (Ambali et al. 2011).

The results of the present study revealed variable histopathological changes in the liver, the spleen and the lung of Coragen-treated animals which were in agreement with those of Saafi et al. (2011), who found that pesticide intoxication displayed serious alterations in the histopathological patterns like

infiltration with mononuclear cells in the portal area and parenchymatous tissues, enlargement of the hepatic sinusoids congestion, enlargement of the portal and central veins in addition to occurrence of hepatocellular alterations. EL-bendary et al. (2014) found that chlorpyrifos as a toxic material reached to the liver via the gastro intestinal tract blood supply, therefore, the necrosed areas mainly appeared around portal tract and central vein. Also, inflammatory cells were aggregated in portal tracts. The inflammatory cells act as a defence mechanism as a result of irritation of toxic material. The kupfer cells were activated for the same reason (Abd-Allah, 1987). The congestion in the spleen was the most apparent changes that may be as a result of intra-splenic destruction of erythrocytes (Pereira et al. 1996). Also, hepatic lesions leading to congestion and haemorrhages of spleen treated with chlorpyrifos has been described (EL-bendary et al. 2014). These findings were confirmed with those of Chaudhary and Sahal (1994), who found that the toxic effect of chlorpyrifos on hepatic lesion leading to congestion and haemorrhages of spleen. We further observed the aggregation of nanoparticles of Coragen in spleen induced by Coragen administration (Bo Cui et al. 2016). In lung we observed in our study an extension in the width of bronchial-associated lymphoid tissue (BALT) in rats exposed to Coragen. This go along with the observations in the lungs of rats exposed to dichlorvos for 1, 4 and 5 weeks by Olatunde et al. (2012). Moreover, this finding was in agreement with the observations in the lungs of rats treated with dermal absorption of dichlorvos for 4 weeks by Luty et al. (1998). The extension in the width of bronchial-associated lymphoid tissue (BALT) may be due to an increase in the amount of the lymphocytic reaction to Coragen in our study which is an indication of the measure of the integrity of the immune system's response in these rats to the absorption of Coragen.

Histopathological changes that observed in the examined liver, spleen and lung tissues after exposure to Coragen may be due to the formation of ROS. This agree with Verma et al. (2007) and Kalender et al. (2012) who recognized ROS as a source of toxic effects exerted by chlorpyrifos as it increased oxidative stress in different tissues and organs. Also, Akhgari et al. (2003) and Abdollahi et al. (2004) inform that biologically active compounds such as pesticides support the formation of ROS which is responsible for the stimulating of oxidative stress in the tissues and subsequently their damage.

Our results revealed that co-administration of an *Origanum majorana* suspension along with Coragen treatment of rats significantly altered the plasma levels of LPx, GPx and SOD compared with the control values. These data are inconsistent with the

findings of Refaie et al. (2014), who showed that *Origanum majorana* significantly decreased plasma LPx levels and increased plasma GPx and SOD activity in rats exposed to prallethrin. Our results may be due to the antioxidant activity of *Origanum majorana* through its antioxidant compounds. Previous studies have shown that *Origanum majorana* exhibits a rich content of the high-potential phenolic components that scavenge radicals due to their capability to provide a hydrogen atom from their phenolic hydroxyl groups. These phenolic components include phenolic terpenoids (carvacrol, thymol), phenolic glycosides (vitexin, arbutin, methyl arbutin, and orientin/thymonin), flavonoids (apigenin, diosmetin, and luteolin), tannins, triacontane, hydroquinone, sitosterol, and cis-sabinene hydrates (Refaie et al. 2014). Moreover, the leaves of *Origanum majorana* and its extracts contain other antioxidants, such as acids (carnosic, oleanolic and ursolic acids), hydrocarbons (P-cymene and c-terpinene), small amount of minerals (calcium and potassium) and vitamins (vitamin C) (Ramadan et al. 2013). According to some studies, *Origanum majorana* leaves contain essential oils, such as 4-terpineol, γ -terpinene, trans-sabinene hydrate and α -terpinene. Moreover, Refaie et al. (2014) has reported that the antioxidant nature of *Origanum majorana* related to the antioxidant action of these essential oils.

The present study showed that *Origanum majorana* has the ability to prevent liver dysfunction induced by Coragen, due to the significantly low activities of serum hepatic enzymes (ALT and AST) and significantly high levels of serum total protein and albumin in the Coragen + *Origanum majorana*-treated group. The resultant action is in a precisely coordinated with the generally recognized concept that the aqueous extract of *Origanum majorana* carried a therapeutic action capable for protecting the hepatocytes from Cadmium-induced liver damage and consequent escape of enzymes into the serum (Shati 2011). Additionally, some studies have indicated that *Origanum majorana* exerts ameliorative action on disordered hepatic enzymes in toxic mice with other toxic substances, e.g. lead (El-Ashmawy et al. 2005). Furthermore, the therapeutic effect of *Origanum majorana* may be attributed to the hypothesis that the plant extract may possess a stimulatory effect capable for regeneration of hepatic tissues and, consequently, increase protein synthesis in altered liver cells (Shati 2011). The *Origanum majorana* extract has a chelating effect, due to the strong free radical scavengers it contains, such as T3b, and exhibits considerable antioxidant properties opposing oxidative damage in the liver. The activity of the extract is mostly five times higher than that of α -

tocopherol, which is an effective natural free radical scavenger (Ramadan et al. 2012).

The administration of the *Origanum majorana* suspension in the present study significantly increased the serum HDL-cholesterol level and decreased the serum LDL-cholesterol level compared with those in the Coragen-treated group. These results are in line with those of Desouky et al. (2015) from rats treated with cisplatin. These authors reported that the improvement effect of *Origanum majorana* on HDL- and LDL-cholesterol levels in cisplatin-treated rats could be returned to the existence of flavonoids, glycosides, tannins, saponins and phenolics. The actions of these compounds may be due to increased inhibition of the intestinal absorption of cholesterol, interference with lipoprotein discharge, and increased expression of hepatic LDL receptors, leading to increased withdrawal of LDL-cholesterol from the blood and subsequent increased degradation and catabolism of cholesterol in the body.

The administration of *Origanum majorana* has a protective role against oxidative damage of Coragen as was insured from improvement of almost all histological alterations. The antioxidant potency of *Origanum majorana* may be due to its various antioxidant components (flavonoids, phenols and alkaloids) and their free radical scavenger activity (Shreen et al. 2015). These results were agreed with those of Abd- El Ghany and El-Metwally (2010) who used *Origanum majorana* leaves to protect against liver injury induced by carbon tetrachloride due to its high content of antioxidant compounds that are released during toxicity and can protect cells against reactive oxygen species. From the achieved results, it could be concluded that the *Origanum majorana* oil possesses a conspicuous modulating effects against the adverse effect of Coragen.

5. Conclusions and Recommendations

The present study revealed that a sub-lethal dose (2000 mg/kg b.wt.) of Coragen induced oxidative damage, biochemical alterations and histopathological changes in male albino rats. In addition, the simultaneous administration of *Origanum majorana* had ameliorating effects to combat the deleterious effect of Coragen to a higher degree. Thus, *Origanum majorana* can be considered one of the optional antidotes against Coragen toxicity. Overall, for health issue, we recommend all activities regarding Coragen should be based on scientific considerations, besides the importance of education and training of workers should be progressively expected to ensure a safe use of Coragen.

Declaration of interest statement

Authors have no conflict of interest to declare.

Animal use

The whole study was performed after obtaining the formal approval from the Faculty of Science, Minia University's policy on animal use and ethics. All required laboratory health and safety measures have been complied with while conducting the experimental work described in this study.

References

1. Abd-Allah GH (1987) Effect of dimethoate and decamethrin on reproductive performance on some haematobiochemical characteristics in male rabbits. Ph.D. Thesis, Fac. Of Agric, Alexandria Univ.
2. Abd- El Ghany MA, El-Metwally NY (2010) Effect of marjoram leaves on injured liver in experimental rats. Rep Opinion 2(12):181-191.
3. Abd-Elhady HK, Abou-Elghar GE (2013) Abamectin induced biochemical and histopathological changes in the albino rat, *Rattus norvegicus*. J Plant Prot Res 53:263–270.
4. Abdollahi M, Mostafalou S, Pournourmohammadi S, Shadnia S (2004) Oxidative stress and cholinesterase inhibition in saliva and plasma of rats following subchronic exposure to Malathion. Comp Biochem Physiol C Toxicol Pharmacol 137(1): 29-34.
5. Agrawal A, Sharma B (2010) Pesticides induced oxidative stress in mammalian systems: A review. Int J Biol Med Res 1:90-104.
6. Akhgari M, Abdollahi M, Kebryaezadeh A, Hosseini, Sabzevari O (2003) Biochemical evidence for free radical-induced lipid peroxidation as a mechanism for subchronic toxicity of Malathion in blood and liver of rats. Hum Exp Toxicol 22(4): 205-211.
7. Ambali SF, Shittu M, Ayo JO, Esievo KAN, Ojo SA (2011) Vitamin C Alleviates Chronic Chlorpyrifos Induced Alterations in Serum Lipids and Oxidative Parameters in Male Wistar Rats. Am J Pharm and Toxicol 6:109-118.
8. Badimon JJ, Badimon L, Fuster V (1990) Regression of atherosclerotic lesions by high-density lipoprotein plasma fraction in the cholesterol-fed rabbit. J Clin Invest 85:1234–1241.
9. Bantu N, Vakita VR, Karra S (2013) Effect of chlorantraniliprole on biochemical and certain biomarkers in various tissues of freshwater fish *Labeo rohita* (Hamilton). Environ Ecol Res 1(4): 205-215.

10. Bergmeyer HU, Horder M, Rej R (1986) Approved recommendation on IFCC methods for the measurement of catalytic concentration of enzymes. Part 3. IFCC method for alanine aminotransferase (L-alanine:2-oxoglutarate aminotransferase, EC 2.6.1.2). *J Clin Chem Clin Biochem* 24:481–495.
11. Cui B, Feng L, Wang C, Yang D, Yu M, Zeng Z, Wang Y, Sun S, Zhao X, Cui H (2016) Stability and Biological Activity Evaluation of Chlorantraniliprole Solid Nanodispersions Prepared by High Pressure Homogenization. *PLOS One* 11(8): e0160877.
12. Chaudhary S, Sahal S (1994) Lambda-cyhalothrin-induced changes in oxidative stress biomarkers in rabbit erythrocytes and alleviation effect of some antioxidants. *J Toxicol Vitro* 21:392-39.
13. Desouky S, Marzouk M, Soliman AM, Sayed AA (2015). Modulatory effect of extract *Origanum majorana* against cisplatin-induced dyslipidemia in rats. *IJCRLS* 4:228-234.
14. Dutta k, Ali M, Najam A, Kumar R, Kumar A (2014) Ameliorative effect of seed extract of *Pterocarpus santalinus* on Coragen induced haematological alterations and serum biochemical changes in Charles Foster rats. *J Toxicol Environ Health Sci* 6: 194-202.
15. El-Ashmawy IM, El-Nahas AF, Salama OM (2005) Protective effect of volatile oil, alcoholic and aqueous extracts of *Origanum majorana* on lead acetate toxicity in mice. *Basic Clin Pharmacol Toxicol* 97(4): 238–243.
16. El-bendary HM, Shaker MH, Saleh AA, Negm SE, Khadey ME and Hosam Eldeen FA (2014) Histopathological Changes Associated with Exposure of Male Mice to Profenofos and Chlorpyrifos. *ARRB* 4(5): 766-777.
17. El-Demerdash FM (2011) Lipid peroxidation, oxidative stress and acetylcholinesterase in rat brain exposed to organophosphate and pyrethroid insecticides. *Food and Chem Toxicol* 49(6):1346–1352.
18. El-Shafey AAM, Seliem MME, El-Mahrouky F, Gabr WM, Kandil RA (2011) Some physiological and biochemical effects of oshar extract and abamectin biocide on male albino rats. *J Am Sci* 7(12):254–261.
19. Gandhi RG, Ignacimuthu S, Paulraj MG (2012) Hypoglycemic and β -cells regenerative effects of Aegel marmelos (L.) corr. bark extract in streptozocin-induced diabetic rats. *Food Chem. Toxicol.* 50(5):1667-1674.
20. Gathwan KH, Al-Karkhi IHT, Yaseen AK (2013) Organophosphorus insecticides induced alterations in liver of male albino rat. *Chem Sci Trans* 2(S1):S95-S98.
21. Guyton AC, Hall JE (2006) Textbook of Medical Physiology, 9th Ed. Prism Book (Pvt.) Ltd., Bangalore, India, XLIII, 1148.
22. Halliwell B, Gutteridge JMC (1999) Free radicals in biology and medicine, 3rd edn. Clarendon Press, Oxford, pp 146–150.
23. Hodgson E (2004) A textbook of modern toxicology, 3rd Edition. John Wiley & Sons, Inc, New Jersey. pp 203-211.
24. Kalender Y, Kaya S, Durak D (2012) Protective effects of catechin and quercetin on antioxidant status, lipid peroxidation and testis-histoarchitecture induced by chlorpyrifos in male rats. *Environ Toxicol Pharmacol* 33(2): 141-148.
25. Kar A, Mandal K, Singh B (2013) Environmental fate of chlorantraniliprole residues on cauliflower using QuEChERS technique. *Environ Monit Assess* 185(2):1255-1263.
26. Leonard PJ, Persaud J, Motwani R (1971) The estimation of plasma albumin by BCG RCG binding on the Technicon SMA 12/60 analyzer and a comparison with the HABA dye binding technique. *Clin Chim Acta* 35:409–412.
27. Luty S, Latuszynska J, Hanina H, Tochman A, Obuchowska D, Przylepa E, Korczak E, Bychawski E (1998) Toxicity of dermally absorbed dichlorvos in rats. *Ann Agric Environ Med*, 5: 57-64.
28. Marklund S, Marklund G (1974) Involvement of the superoxide anion radical in the autoxidation of pyrogallol and a convenient assay for superoxide dismutase. *Eur J Biochem* 47:469–474.
29. Mostafalou S, Abdollahi M (2013) Pesticides and human chronic diseases: Evidences, mechanisms, and perspectives. *Toxicol Appl Pharmacol.* 268 (2): 157-177.
30. Ohkawa H, Ohishi N, Yagi K (1979) Assay for lipid peroxides in animal tissues by thiobarbituric acid reaction. *Anal Biochem* 95:351–358.
31. Olatunde O, Fabian VE, Bukola SA, Sheu R, Effiong EA, Ganiyu OA (2012) Histological changes in liver and lungs of rats exposed to dichlorvos before and after vitamin supplementation. *Eur J Anat*, 16 (3): 190-198.
32. Paglia DE, Valentine WN (1967) Studies on the quantitative and qualitative characterization of erythrocyte glutathione peroxidase. *J Lab Clin Med* 70:158–169. <https://www.ncbi.nlm.nih.gov>.
33. Pereira SP, Langley PG and Williams R (1996) The Management of Abnormalities of

- Hemostasis in Acute Liver Failure. *Semin Liver Dis* 16:403-414.
34. Pimple BP, Patel AN, Kadam PV, Patil MJ (2012) Microscopic evaluation and physicochemical analysis of Linn leaves. *Asian Pac J Trop Dis* S897- S903.
 35. Ramadan G, El-Beih NM, Zahra MM (2012) Egyptian sweet marjoram leaves protect against genotoxicity, immunosuppression and other complications induced by cyclophosphamide in albino rats. *Br J Nutr* 108: 1059–1068.
 36. Ramadan G, El-Beih NM, Arafa NMS, Zahra MM (2013) Preventive effects of Egyptian sweet marjoram (L.) leaves on haematological changes and cardiotoxicity in isoproterenol-treated albino rats. *Cardiovasc Toxicol* 13(2):100–109.
 37. Refaie AA, Amal Ramadan A, Mossa AH (2014) Oxidative damage and nephrotoxicity induced by prallethrin in rat and the protective effect of essential oil. *Asian Pac J Trop Med* 7: S506-S513.
 38. Saafi EB, Louedi M, Elfeki A, Zakhama A, Najjar MF, Hammami M, Achour L (2011) Protective effect of date palm fruit extract (*Phoenix dactylifera* L.) on dimethoate induced-oxidative stress in rat liver. *Exp Toxicol Pathol* 63 (5):433-441.
 39. Shati AA (2011) Effects of *Origanum majorana* L. on cadmium induced hepatotoxicity and nephrotoxicity in albino rats. *Saudi Med. J.* 32(8): 797- 805.
 40. Shreen D, Mohamed M, Amel MS, Amany AS (2015) Modulatory effect of *Origanum majorana* extract against cisplatin-induced dyslipidemia in rats. *IJCRLS* 4(6): 228-234.
 41. Uzun FG, Kalender Y (2013) Chlorpyrifos induced hepatotoxic and hematologic changes in rats: the role of quercetin and catechin. *Food Chem Toxicol* 55:549-556.
 42. Verma RS, Mehta A and Srivastava N (2007) In vivo chlorpyrifos induced oxidative stress: Attenuation by antioxidant vitamins *Pestic Biochem Physiol* 88(1): 191-196.
 43. Young DS, Friedman RB (2001) Effects of disease on clinical laboratory tests, vol 1 and 2, 4th edn. AACC Press, Washington, DC.

9/8/2019