

Study the anatomical variation of the Jugular Foramen in Egyptian dry skulls (Morphological and Morphometric studies)

Samia M. Manawy¹ and Eman A. El-Sawaf²

¹Anatomy Department, Faculty of Medicine, Benha University, Benha, Egypt

²Anatomy Department, Faculty of Medicine, Helwan University, Cairo, Egypt

drsamiamanawy@yahoo.com

Abstract: Background: The jugular foramen is a large foramen in the base of the skull. It transmits important vascular and nervous structures. Understanding of normal dimensions of this foramen is necessary and of great help to neurosurgeon while approaching this foramen. **Aim:** To study the morphometric analysis and anatomical variations of jugular foramen in Egyptian dry skulls. **Materials and methods:** One hundred skulls of unknown sex were studied morphologically. The shape was observed. Antero-posterior and medio-lateral diameters were measured by digital vernier caliper. Detection of presence or absence of dome and septations was done. **Statistical analysis:** The mean, standard deviation (SD) and range of dimensions was computerized. Comparison between two sides was made using student's t-test. **Results:** Oval shaped foramen was common (70%), round shaped foramen (30%). Dome was bilateral in 79%, unilateral in 21%. Septation was in 97% of foramina. Complete septation bilaterally in 25% of, unilateral in 40%. While partial septation was in 32%. Absence of septation in 3%. AP diameter (right - 6.8 ± 2.39 mm, left - 5.4 ± 1.58 mm) and was side insignificant difference. ML diameter (right - 17.2 ± 4.6 mm, left - 14.6 ± 2.07 mm) and was significantly higher on the right side. **Conclusion:** This study demonstrated that the right is dominance in the parameters of the foramen. Presence of septation and dome are more frequent. The oval shape foramen is common. Good imaging of the foramen preoperative is recommended to avoid injury of its contents due to foramen variability.

[Samia M. Manawy and Eman A. El-Sawa. **Study the anatomical variation of the Jugular Foramen in Egyptian dry skulls (Morphological and Morphometric studies)**. *J Am Sci* 2019;15(5):17-25]. ISSN 1545-1003 (print); ISSN 2375-7264 (online). <http://www.jofamericanscience.org>. 4. doi:[10.7537/marsjas150519.04](https://doi.org/10.7537/marsjas150519.04).

Keywords: Jugular foramen, Jugular dome, Septation, Skull, Foramen dimensions.

1. Introduction

Jugular foramen is a large opening in the base of the skull. It is located behind the carotid canal and is formed by the petrous part of the temporal bone and the occipital bone. The jugular foramen is the main route of venous outflow from the skull and is characterized by laterality based on the predominance of one of the sides [1]. Ligation of the internal jugular vein is sometimes performed during radical neck dissection with the risk of venous infarction, which some adduce to be due to ligation of the dominant internal jugular vein [2]. In general Jugular foramen is larger on the right side compared to the left; its size as well as its height and volume vary in different racial groups and sexes. The foramen's complex shape, its formation by two bones, and the numerous nerves and venous channels that pass through it further compound its anatomy [3]. The jugular foramen is commonly divided into three compartments-two venous and a neural or intra jugular compartment. The structures that traverse the jugular foramen are the sigmoid sinus and jugular fossa, the inferior petrosal sinus, meningeal branches of the ascending pharyngeal and occipital arteries, the glossopharyngeal, vagus and accessory nerves with their ganglia [4, 5].

Tumors involving the jugular foramen and adjacent structures require a microsurgical approach to this region [6, 7]. Most of the surgical approaches are designed to drill the bone around the jugular foramen for proper exposure [8-10]. Thus, the knowledge of the anatomical details and dimensions of jugular foramen in the regional population would be of great help to surgeon while approaching this foramen.

The present work was carried out to study normal range of variations in relation to size, shape and compartments of jugular foramina.

2. Materials and Methods

Study has been conducted on one hundred dry skulls of unknown sex. They were collected from the department of anatomy, faculty of medicine Benha University and Shebin EL Kom faculty of medicine with respecting the ethical behaviors with bone. All skulls in this study are devoid of gross malformations. Manual vernier caliper were used for the measurement of jugular foramen (fig 1).

The morphological examination was done by inspection. Measurements were taken by the method described by Singla et al [11].

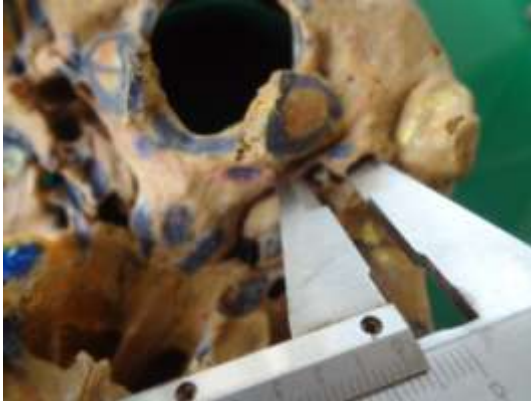


Fig (1) Photograph of measurement by Vernier caliber

Osteometric parameters

The following measurements were taken in millimeters with the help of vernier caliper (accuracy up to 0.02 mm).

Side: Right or left which determined by putting skull in the anatomical position.

Shape: the shape was either oval or rounded.

Medio -lateral (ML): Maximum medio -lateral diameter of the foramen (ML) was taken between medial-most and lateral-most point of the jugular foramen. (fig 2)

Anteroposterior (AP): Maximum antero-posterior diameter of the foramen (AP). (fig 2)

Dome: Presence or absence of domed bony roof was noted which is related to the presence of superior jugular bulb.

Septations: Bony bridges dividing the foramen into compartments (arrows) was observed and if present determined these compartments are complete or partial. (fig 3)

Width of the sigmoid sinus groove (SG). (fig 3)

All the measurements were taken bilaterally, and photography was done using Sony digital camera.

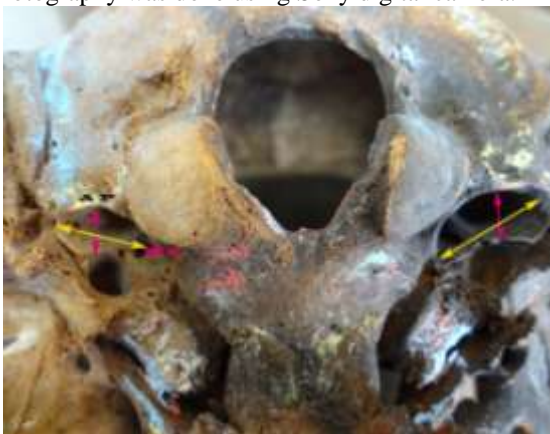

Fig (2): Photograph of base of the skull showing parameters of JF on exocranial aspect (AP) antero posterior diameter (ML) mediolateral (ML) diameter.



Fig (3): A photograph of cranial cavity showing JF on endocranial aspect, septation (arrow) of the foramen and groove for sigmoid sinus (SG).

The measurements were taken bilaterally and statistical analysis was performed.

Statistical Analysis

The AP and ML diameters of jugular foramen on the right and left sides were recorded and analyzed using IBM SPSS Statistics software for Windows, Version 19 (IBM Corp., Armonk, NY, USA). Independent sample T test was used to compare differences among the right and left sides. In each test, the data was expressed as the mean (M) value, standard deviation (SD) and range.

Observations and results were tabulated and compared with previous studies.

3. Results

The jugular foramen was examined with respect to its size and shape, and the presence of a domed bony roof and presence or absence of septae which are bony structures dividing JF into compartment.

The jugular foramen varied in terms of septation presence of dome and side difference in AP and ML diameters. The foramen is like a canal, with an endocranial and exocranial opening.

This study were carried on one hundred dried skulls.

On examination of the skulls we found that the medio- lateral diameter (ML) of the foramen was greater than the antero- posterior (AP) diameter.

The right foramen parameters are larger than the left parameters in most of skulls used (80%) (fig4). Some skulls have foramen looks like slit specially on left side (fig 5). In few skulls (17%), the left foramen parameters are larger than the right parameters (fig6). In about 3% the two foramina are nearly equal. Foramina mainly have bilateral domes (fig7). Few skulls have unilateral dome (fig 8). Most of the foramina have septations. Some foramina have

bilateral septations (fig 9, 11 & 12); others have unilateral septations (fig 10 & 13). Few have no septations (fig 14).

According to shape: Oval shape is common (70%) and (30%) rounded.

According to antero- posterior diameter (AP): (fig 4,5, & 6).

It varies from (10mm to 3mm). Mean AP dimension was greater for the right JF than the left JF.

The mean AP diameter is (6.8 ± 2.39 mm) in RT and (5.4 ± 1.58 mm) in LT side.

More than (75%) varies from (7 to 5mm). Few number have narrow foramina (3 mm) (slit like foramina) specially on left side (fig5). More than 20% have AP diameter more than 9 mm specially in RT side. When comparing between two sides there were no significant difference between both sides (table 1 & histogram 1).

According to medio- lateral diameter (ML): (fig 4, 5 & 6):

It varies from (24 mm to 9 mm). Mean ML dimension was greater for the right JF than the left JF. The mean ML diameter is (17.2 ± 4.6 mm) in RT and (14.6 ± 2.07 mm) in LT side. More than 80% varies from (20 to 15 mm). Few numbers have ML diameter less than 10 mm. More than 10% have wide foramina ML diameter more than 21 mm especially in RT side.

In comparing between both side there were significant difference. (table 1 & histogram 2).

According to dome: (fig 7 & 8)

The presence of dome in the foramen is common in this study. Bilateral presence is 79% (fig 7). Unilateral presence represented 21% (fig 8). There are no case reported of absence of dome on both sides.

According to septations: (fig 9,10,11,12,13 & 14)

Presence of septa is common (97%) in jugular foramen as they divide the foramen into compartments. They can be complete (fig9, 10 & 11) or incomplete (fig 12). Also they can be bilateral (fig 9, 11 & 12) or unilateral (fig 10 & 13). Bilateral complete in 25%, unilateral in40%(26%RT, and 14% LT). Partial in 32%.

In this study few numbers (3%) had no septation (fig 14).

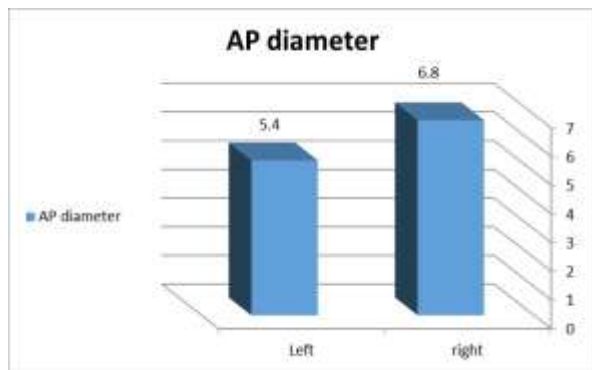
Sigmoid sinus groove: (fig 11 & 15)

The groove for sigmoid sinus was larger in the RT side in 92% (fig 11). It was larger in LT in 8% (fig 15).

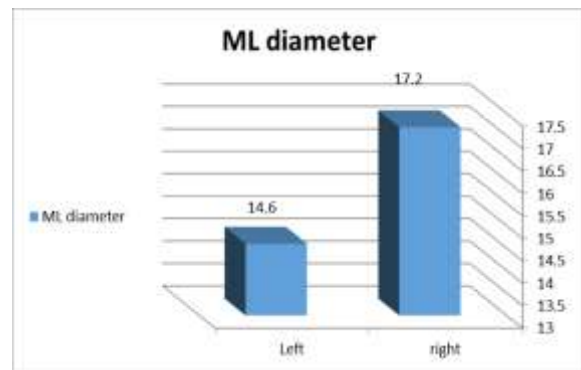
Mean AP diameter on the right and left side was found to be 6.8mm. and 5. 4 mm. respectively. Right is large but is insignificant ($P>0.05$). Mean ML diameter was found to be 17.2 and 14.6mm on the right and left sides respectively, Right is large which is highly significant ($P \leq 0.05$).

Table (1)

Parameter	Right jugular foramen		Left jugular foramen		p	T
	Range	Mean \pm SD	Range	Mean \pm SD		
AP jugular diameter in mm	3 - 10	6.8 ± 2.39	3 - 8	5.4 ± 1.58	0.14	1.5
ML jugular diameter in mm	9 - 24	17.2 ± 4.6	10 - 17	14.6 ± 2.07	0.05	1.6



Histogram (1)



Histogram (2)

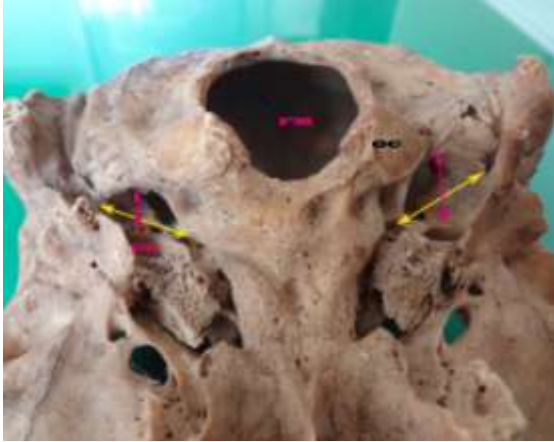


Fig (4): Photograph of exocranial aspect of jugular foramen showing following parameters, anteroposterior diameter (red arrow) is (8 mm) in RT and (5 mm) in LT side. Medio-lateral diameter (yellow arrow) is (14 mm) in RT and (11 mm) in LT side (CC) carotid canal, (OC) occipital condyle, (FM) foramen magnum.

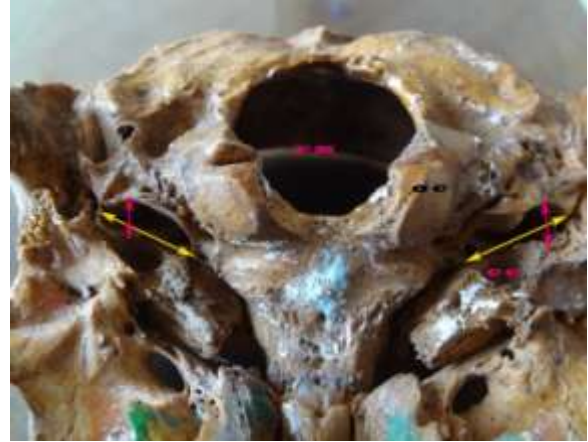

Fig (6): Photograph of exocranial aspect of jugular foramen showing following parameters, anteroposterior diameter (red arrow) is (6 mm) in RT and (8 mm) in LT side. Medio-lateral diameter (yellow arrow) is (8mm) in RT and (12 mm) in LT side (CC) carotid canal, (OC) occipital condyle, (FM) foramen magnum.

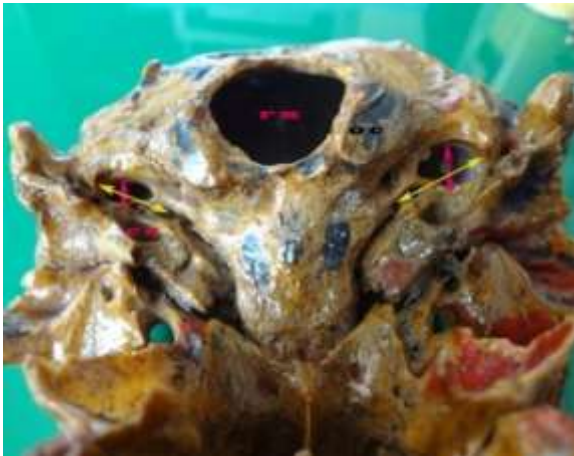

Fig (5): Photograph of exocranial aspect of jugular foramen showing following parameters, anteroposterior diameter (red arrow) is (5 mm) in RT and (3 mm) (slit like) foramen in LT side. Medio-lateral diameter (yellow arrow) is (13 mm) in RT and (9mm) in LT side (CC) carotid canal, (OC) occipital condyle, (FM) foramen magnum

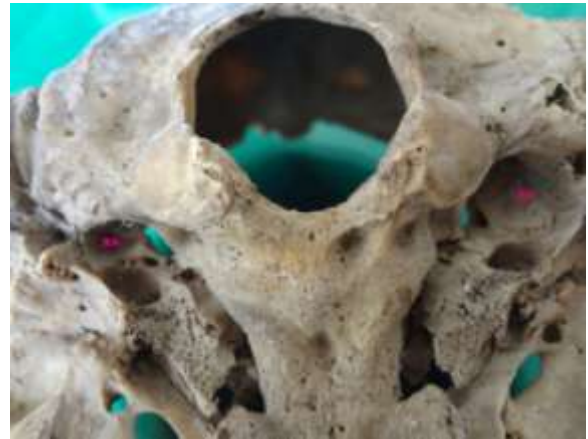

Fig (7): Photograph of exocranial aspect of jugular foramen showing bilateral dome of the foramen (D).

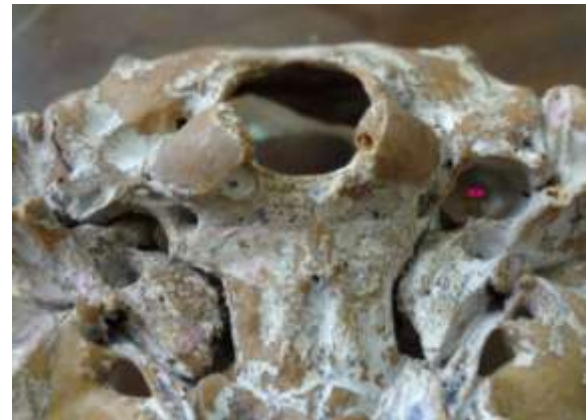

Fig (8): Photograph of exocranial aspect of jugular foramen showing unilateral dome of the foramen (D).

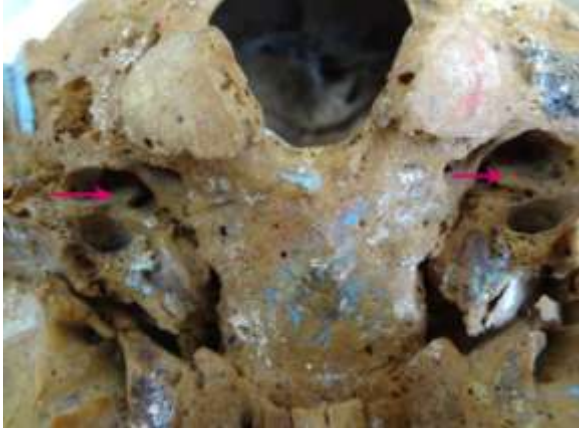


Fig (9): Photograph of exocranial aspect of jugular foramen showing complete bilateral septation of the foramen (arrow).

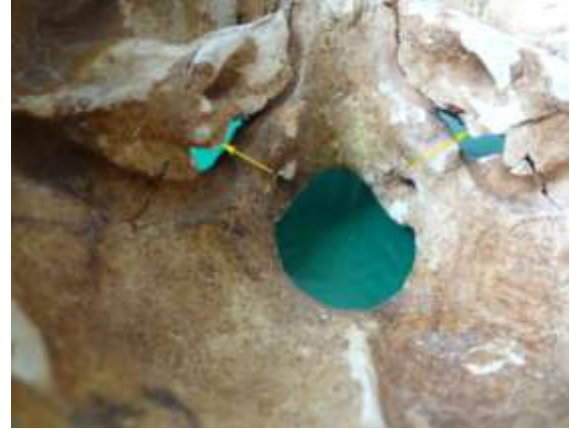

Fig (12) Photograph of endocranial aspect of jugular foramen showing incomplete bilateral septation of both foramina (arrow).

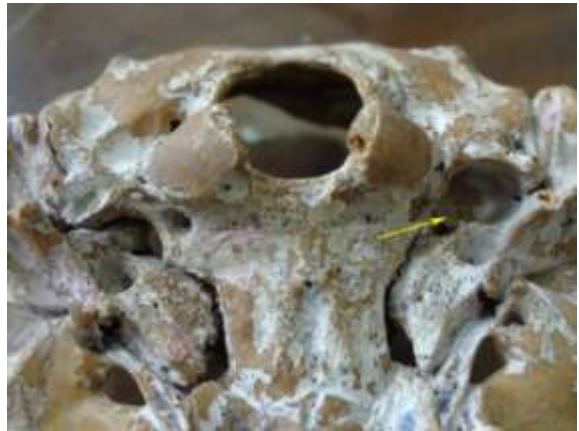

Fig (10): Photograph of exocranial aspect of jugular foramen showing complete unilateral septation of the foramen (arrow).

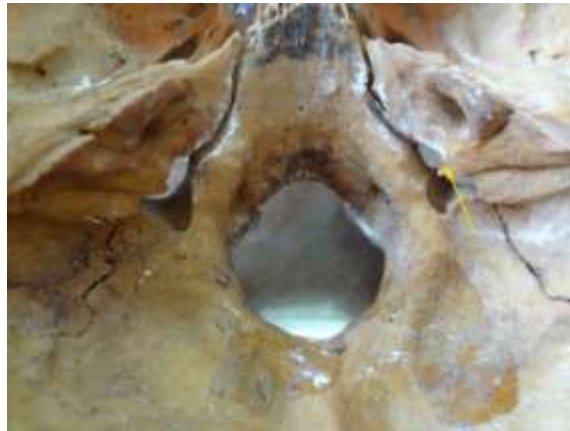

Fig (13): Photograph of endocranial aspect of jugular foramen showing unilateral septum (arrow).

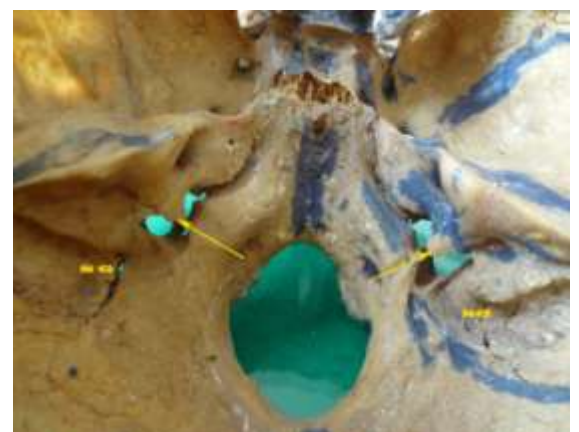

Fig (11) Photograph of endocranial aspect of jugular foramen showing complete bilateral septation of both foramina (arrow). The groove for sigmoid sinus is wider on RT side SG.

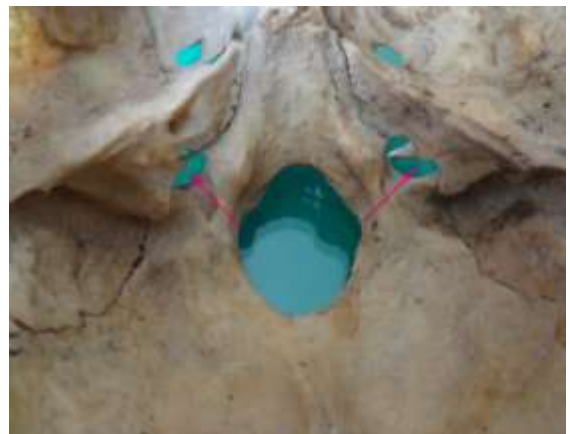

Fig (14): Photograph of endocranial aspect of jugular foramen showing no septation of both foramina (arrow).

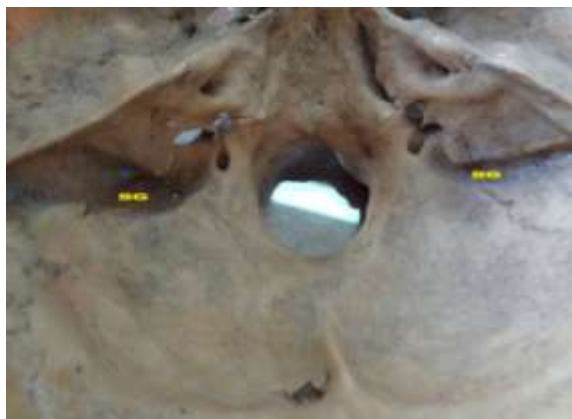

Fig (15) Photograph of endocrinal aspect of jugular foramen showing groove for sigmoid sinus wider in LT side (SG).

4. Discussion

The jugular foramen is like a canal, having separate endocrinal and exocranial openings. Mainly The exocranial opening is larger than the endocrinal opening due to presence of jugular bulb [12].

The jugular foramen is deep in position so it is difficult to understand and exposing. The jugular foramen present bilaterally left & right in all skulls studied as accepted [13]. The variant anatomy of the jugular foramen and variation of its size attract attention of neurosurgeons. Also the relationship of the structures which pass through the foramen is of medical and surgical interest [14]. The shape of the foramen is variable. The oval shaped foramens were common 70% and rounded is less common 30%. This differ with study done by This finding is Sakthivel et al who reported that the round shaped jugular foramen (58.6%) was more than the oval shaped jugular foramen (41.2%). [15]

The foramina show variation in presence of dome, septation, and dimensions in different population. These variations are of clinical importance [16].

In this study incidence of septation is 97%. variable from bilateral, unilateral, complete or partial. There are Bilateral complete in 25%, unilateral in 40% (26% RT, and 14% LT). Partial in 32%. No bilateral septation in 3%. These results agree with Vljaković et al. their results were complete bony bridges of the jugular foramen in 24% of examined skulls [17]. Also it is near to Patel and Singel who studied the Indian Saurashtra region and observed complete septation on the right side in 23.1%, on left side in 17.6%; partial septation on the right side in 49.5%, and on left side in 59.3% skulls [18].

This result differs from Singh et al. Their results reported that bilateral complete septation was only in 3.3% of the examined skulls, where as unilateral

complete septation was present in 8.3% skullson RT and in 5.0 % of skulls on LT [19]. And differ with Pereira et al who reported absence of septation in 83.8% of skulls [16].

The cause of variations of septation frequency may be of racial factor, genetic or developmental. The partial septation of foramina may be completed in the living by a fibrous septum [20].

Septation and compartmentalization may compress the structures passing through the foramen and cause clinical presentations like those of glomusjugulare tumor (glomusjugulare tumors are found in the tunica adventitia of jugular bulb in relation to the tympanic branches of glossopharyngeal and vagus nerves in the middle ear) [21]. Septation must be kept in mind during surgical approach to lesions within the foramen [22].

Another important anatomical feature of the jugular foramina is presence of dome. In this study the bilateral dome is present in 79%of cases. Unilateral dome in 21% of skull examined. These results are near to this by Singla et al. who reported bilateral dome in 66% of cases [11]. And also near to Pereira et al bilateral dome in 68.5% [16].

But there are great difference with study done by Patel and Singel who found the dome in only 21% of the skulls [18]. There is no case reported of bilateral absence of dome in this study in contrast to other studies as Khanday et al who found that 11% of skulls had no bilateral dome [22]. And with Singla et al. who found that in total, 12% of cases showed the absence of dome [11].

In studies by Das et al reported that there are no bilateral absence of dome as reported in this study [21].

The presence of dome indicates the presence of well-expressed superior bulb of internal jugular vein. The bulb should not be mistaken for tumor or a mass during radiography [23]. When the dome is so high it can reach above the internal acoustic meatus. This must be considered during preoperative planning for inner ear surgeries to avoid injury of the bulb [24].

In this study the right foramen dimensions are larger than the left dimensions in 80% of cases. The left foramen is larger in 17% of case and 3% of cases are nearly equal. These results area greed with Ramos-Junior et al. who indicated RT is larger in 84% [25].

And agree with Shruti et al. who showed that in 71.2% of cases the right jugular foramina were larger than the left. The left foramina were larger than right in 20.8% of cases. In 8% of cases they were equal in size on both sides [26].

Other studies done by several authors in variable countries show results near to this study in Egypt. Singh et al. study the morphometric variations of jugular foramen in South India and the right was larger

in 88.3% of skulls as compared to 3.3% of skulls on the left. The remaining 8.3% of skulls, it was equal [19]. Akram (from Bangladesh) also found that the right foramen is larger in 58.2%, larger foramen in left side in 21.8% and two foramen are equal in 20% of cases [27]. Also old studies show the same results as Hatiboglu & Anil who did their studies on 300 Anatolian skulls from the 17th & 18th centuries and they found that in 61.6% the foramen was larger on the right side and 26% it was larger on the left side [28].

Detecting of the size of the jugular foramina is depending on measuring the diameters of the foramina. Evaluation of these diameters indicating that there is frequent asymmetry [19].

In this study the AP dimension was greater for the right JF than the left JF. It varies from (10 mm) to (3 mm) in RT and from (8mm to 3mm) in LT. The mean AP diameter is (6.8 ± 2.39) in RT and (5.4 ± 1.58) in LT side. But this difference is insignificant.

These results agree with by Sundika et al which results were (6.43) in RT and in left were (5.39) [29]. Also it is near to studies by Saheb et al who reported mean AP diameters were (7.83 ± 1.36) in RT (6.83 ± 1.6) in LT [30].

The results of Pereira et al were higher than our results who reported significant difference between sides. Mean AP diameter was to be (9.21 ± 1.95) in RT and (8.65 ± 1.57) in LT. Their study was in Southern Brazilian population [16].

Also results of AP diameter was lower than that reported by Idowu, whose results were the mean AP diameter to be (10.22 ± 2.67) in RT and (9.57 ± 1.84) in LT [31].

AP diameter was larger on right side which explained by relation to prominent superior bulb of internal jugular vein [31].

Medio -lateral (ML) diameter was reported in this study range from (24 mm to 9 mm) in right side. And from (17 mm to 10 mm) in left side. Its mean was is (17.2 ± 4.6) in RT and (14.6 ± 2.07) in LT side. This difference is highly significant.

These results disagree with studies done by Pereira et al who found mean ML diameter to be (15.82 ± 2.67) in RT and (15.86 ± 2.64) in LT. [16] and show no significant difference between two sides.

This study is near to that done by Osunwoke et al who reported mean ML was in RT ($15(76 \pm 2.36)$) and (13.39 ± 2.5) in LT [32].

The results are lower than studies done on Shabe et al who reported RT is (23.62 ± 2.29) and LT is (22.86 ± 3.13) [30]. And are higher than reported by Singla et al. (8.99 ± 1.92) in RT and (7.54 ± 2.07) in LT [11].

Although these variations there is right sided dominance which observed in the dimensions of the

foramen and also reported by several authors [5,21,22].

The differences of dimensions may be due to racial differences.

The size and shape of the jugular foramen depends mainly on the internal jugular veins and if there is prominent superior bulb. The large superior sagittal sinus is draining into RT transverse sinus to right sigmoid sinus, and right internal jugular vein. The smaller inferior sagittal sinus is draining into straight sinus then the left transverse sinus, left sigmoid sinus and into left internal jugular vein. So it is expected that RT foramen is mainly larger than LT [19].

But there are variation of anatomy of intracranial venous sinuses which lead to variations of the internal jugular veins and subsequent the size and shape of the jugular foramen [30].

Detecting the dimensions of the foramen may be important in the diagnosis of JF stenosis or widening. In this study there are few numbers of skulls showed narrow dimensions (slit like) especially on LT side. AP is 3 mm and ML is 9 mm. These results near to by Rastogi and Budhiraja. Who found AP and ML dimensions of 2.47 and 7.74 mm on LT side respectively [33].

This narrowing of foramen lead to (IX, X and XI) cranial nerves compression resulting in neurovascular symptoms which can be similar to the symptoms of jugular meningiomas, glomus jugular tumors [34]. The finding that right JF dimensions are greater than the left which suggest that right IJV 'dominance' in most of the study population. This gives an idea in selecting the IJV which ligate or catheterize. [35].

In the truth jugular foramen is very complex as the varieties of structures passing throw it. In this study, the oval shape is more common than the rounded shape. the presence of septation was more prevalent than its absence, the presence of dome was more than its absence and the dimensions parameters of the jugular foramen showed right side dominance.

This study expected to give a clear understanding of the jugular foramen anatomy and recorded reported morphometric variations of the JF. As knowledge of these variations is very important for neurosurgeons, radiologist. Also for anthropologist.

Conclusion

This study demonstrated that the right foramen is dominance in the parameters (AP & ML). Presence of septation and dome is more frequent. The oval shape foramen is common. Good preoperative imaging of the foramen is recommended to avoid injury of its contents due to foramen variability.

References

1. Shruthi B. N, Pavan P. Havaladar, Shaik Hussain Saheb 3. Study on morphological variations in structure of the jugular foramen. *International Journal of Anatomy and Research, Int J Anat Res* 2015, Vol 3(4):1533-35.
2. Wysocki J, Chmielik LP, Gacek W. Variability of magnitude of the human jugular foramen in relation condition of the venous outflow after ligation of the internal jugular vein. *J Otolaryngologia* 1999;53:173-77.
3. Navsa N, Kramer B. A quantitative assessment of the jugular foramen. *Anatomischer Anzeiger* 1998;180:269-273.
4. Albert L. Rhoton Jr. Jugular foramen, *Neurosurgery*, 2000;47(3).
5. Gupta C, Kurian P, Seva PN, Kalthur SG, D'souza AS. 2014. A morphological and morphometric study of jugular foramen in dry skulls with its clinical implications. *J Craniovertebr Junction Spine*. 5: 118-21.
6. Ramina R, Maniglia JJ, Fernandes YB, Paschoal JR, Pfeilsticker LN, Neto MC, et al. Jugular foramen tumors: Diagnosis and treatment. *Neurosurg Focus* 2004; 17(2):31-40.
7. Matsushima T, Kawashima M, Masuoka J, Mineta T, Inoue T. Transcondylar fossa (supracondylar transjugular tubercle) approach: Anatomic basis for the approach, surgical procedures and surgical experience. *Skull Base* 2010;20 (2)83-91.
8. Gjuric M, Bilic M. Transmastoid—infra-labyrinthine tailored surgery of jugular paragangliomas. *Skull Base* 2009;19(1):75-82.
9. Borba LA, Araujo JC, De Oliveira JG, Filho MG, Morso MS, Tirapelli LF, et al. Surgical management of glomus jugular tumors: A proposal for approach selection based on tumor relationships with the facial nerve. *J Neurosurg* 2010;112(1)88-98.
10. Ladzinski P, Maliszewski M, Kaspera W, Szczygiel M, Tymowski M. Approach to the jugular foramen and related structures—an analysis of the surgical technique based on cadaver simulation. *Neurol Neurochir Pol* 2011;45(3):260-74.
11. Singla A, Sahni D, Aggarwal A, Gupta T, Kaur H. Morphometric study of the jugular foramen in Northwest Indian population. *J Postgrad Med Educ. Res* 2012;46:165-71.
12. Rhoton AL (2000) Jugular foramen. *Neurosurg* 47:267-285 Cross Ref Google Scholar.
13. Standring S.S.P. *Gray's Anatomy: The Anatomical Basis of Clinical Practice, Expert Consult- Online and Print, 40th edition.* ed. Churchill Livingstone, Edinburgh. 2008. p. 415, p. 424.
14. Kumar A., Akhtar J., Kumar A.: Variations in jugular foramen of human skull. *Asian Journal of Medical Sciences*. 2015; 6 (2): 95-98.
15. Sakthivel KM, Balaji TK, Moni AS, Narayanan G, Kumar KS. 2014. Study of Jugular Foramen – A Case Report. *Journal of Dental and Medical Sciences*. 13: 63-67.
16. Pereira G.A.M., Lopes P.T.C., Santos A.M.P.V., Krebs W.D.: Morphometric aspects of the jugular foramen in dry skulls of adult individuals in Southern Brazil. *J Morphol Sci*. 2010; 27 (1): 3-5.
17. Vljaković S., Vasović L., Daković-Bjelaković M., Stanković S., Popović J., Čukuranović R.: Human bony jugular foramen: Some additional morphological and morphometric features. *Med Sci Monit*. 2010; 16 (5): 140-146.
18. Patel MM, Singel TC. Variations in the structure of the jugular foramen of the human skull in Saurashtra region. *J Anat Soc India* 2007;56(2):34-37.
19. Singh S., Suman P., Panigrahi A.K.: Morphometric variation of jugular foramen in dry adult skull of South Indian population and its clinical implications. *IJHSR* 2015; 5 (9): 215-219.
20. Tubbs R.C.G. Dural septation on the inner surface of the jugular foramen: An anatomical study. *J. Neurol. Surg. Part B Skull Base*. 2015; 76: 214-217.
21. Das SS, Saluja S, Vasudeva N. Complete morphometric analysis of jugular foramen and its clinical implications. *J Craniovertebr Junction Spine*. 2016; 7: 257-64.
22. Khanday S, Ramesh Kumar, Melani R., Ashfaq U., Sajad H. Morphological and morphometric study of jugular foramen in South Indian population. *Int. J. Anat. Res*. 2013;1:122-27.
23. Sasindran V., Abraham S., Hiremath S., Joseph A. High-riding jugular bulb: A rare entity. *Indian J. Otolaryngol*. 2014; 20:129.
24. Jovanović I., Ugrenović S., Stojanović V., Krstić M., Trandafilović M., Čukuranović J. Morphometric characteristics of jugular foramen and sigmoid sinus groove: their possible connections with high jugular bulb presence. *Facta Univ., Med. Biol*. 2014; 16: 12-17.
25. Ramos-Junior S.P., da Silva Gusmão S.N., Raso J.L., Nicolato A.A., Santos M., Caetano I.M.: Comparative morphometric study of the sigmoid sinus sulcus and the jugular foramen. *Arq Neuro-Psiquiatr*. 2014; 72 (9): 694-698.
26. Shruthi B.N., Havaladar P.P., Saheb S.H., Henjarappa K.S.: Morphometric study of jugular

- foramen. *Int JIntg Med Sci.* 2015; 2 (10): 164–166.
27. Akram Hossain SM, Moshadeq Hossain SM, Fakhrol Amin Mohammad Hasannul Banna: *Bangladesh Journal of Anatomy* july 2012, vol 10 No. 2 pp 45-49.
 28. Hatiboglu MT and Anil A. Structural variations in the jugular foramen of the human skull. *Journal of Anatomy*1992; 180: 191-196.
 29. Sundika I.P.P. Anosteometric evaluation of the jugular foramen. *Int. J. Morphol.*2014; 33: 251-254.
 30. Saheb S., Mavishetter G. F., Thomas S. T, Prasanna L.C., Muralidhar P. A morphometric study of the jugular foramen in human adult skulls of south India. *J Biomed Sci Res.* 2010; 2: 240-243.
 31. Idowu OE. The jugular foramen- a morphometric study. *Folia Morphol* 2004; 63:419-422.
 32. Osunwoke E.A, Oladipo G.S, Gwunireama I.U, Ngaokere J.O. Morphometric analysis of the foramen magnum and jugular foramen in adult skulls in southern Nigerian population. *Am. J. Sci. Ind. Res.* 2012; 3(6): 446-448.
 33. Rastogi R, Budhiraja V. Slit-like jugular foramen due to abnormal bone growth at jugular fossa—a case report. *IJAV* 2010; 3:74-75.
 34. Kawabe K, Sekine T, Murata K, Sato R, Aoyagi J, Kawase Y, et al. A case report of vernet syndrome with varicella zoster virus infection. *J Neurol Sci* 2008;270:209-10.
 35. Lichtenstein D, Saïfi R, Augarde R, Prin S, Schmitt JM, Page B, et al. The internal jugular veins are asymmetric. Usefulness of ultrasound before catheterization. *J Intensive Care Med.*2001; 27:301–305.

4/29/2019