

## Role of ERCP in Management of Biliary Complications after Cholecystectomy

Prof. Dr. Mahmoud Abd Allah Abd Elrazik<sup>1</sup>, Dr. Sameh Gabr Attia<sup>2</sup>, Dr. Kamal Abd El-Rahman Abo Sena<sup>1</sup>,  
Mostafa Mahmoud Ahmed Haggag<sup>1</sup>

<sup>1</sup>General Surgery Department, Faculty of Medicine for Girls, Al-Azhar University, Cairo, Egypt

<sup>2</sup>General Surgery Department, Faculty of Medicine for Boys, Al-Azhar University, Cairo, Egypt

E-mail: [mostafahaggag86@gmail.com](mailto:mostafahaggag86@gmail.com)

**Abstract: Background:** ERCP has assumed an important role because it facilitates evaluation and management of suspected biliary complications after cholecystectomy. **Aim of the Work:** the aim of this work is to evaluate the role ERCP in management of post-cholecystectomy (open-laparoscopic) biliary complications. **Patients and Methods:** these prospective study will be conducted in Al-Azhar University Hospitals (in a period from 9/2015 - 9/2018) evaluate ERCP in management of post-cholecystectomy biliary complications in about 30 cases who were subjected to cholecystectomy and suffering from biliary tree related complications such as external bile leak, localized bile collection, bile peritonitis, or obstructive jaundice, missed stone. **Results:** There were 30 patients, 19 female and 11 male, with a median age of 59 (range 18–85) years. A great majority of 20 patients (67%) had undergone surgery at an outside hospital and were referred to our department. Most of the retained stones were extracted. Cystic stump leak (9/30) or post removal CBD T-tube site leaks without distal obstruction in one patient (3.3%) were treated with ES. Biliary tract injuries as Transections or clips occluding the ducts at different levels were found in 4 (13.3%) patients. Accessory duct leakage was discovered in one patient (3.3%) and ercp and stenting was done. The success rate was high (90.9%) in all patients except in patients with larg stone that lithotripsy cannot done or anatomical variations as ampullary diverticulum. **Conclusion:** diagnostic and therapeutic endoscopic interventions may be indicated for numerous cholecystectomy complications. ES and stone extraction is the preferred therapy for retained or recurrent stones.

[Mahmoud Abd Allah Abd Elrazik, Sameh Gabr Attia, Kamal Abd El-Rahman Abo Sena, Mostafa Mahmoud Ahmed Haggag. **Role of ERCP in Management of Biliary Complications after Cholecystectomy.** *J Am Sci* 2019;15(2):91-100]. ISSN 1545-1003 (print); ISSN 2375-7264 (online). <http://www.jofamericanscience.org>. 12. doi:[10.7537/marsjas150219.12](https://doi.org/10.7537/marsjas150219.12).

**Keywords:** ERCP, Biliary Complications, Cholecystectomy

### 1. Introduction

Gallstone disease is common all over the world. Cholecystectomy is the treatment of choice for symptomatic gall stones<sup>(1)</sup>. *Langenbuch*<sup>(2)</sup> performed the first open cholecystectomy (OC) in 1882, and it remained the gold standard for the treatment of cholelithiasis. The first laparoscopic cholecystectomy (LC) was performed by eric mühe in Germany in 1985<sup>(3)</sup>. Laparoscopic cholecystectomy accounts for 85% of the more than 750,000 cholecystectomies performed annually in the United States<sup>(4)</sup>. The laparoscopic approach is preferred because it results in less postoperative pain, a shorter hospital stay, and a faster return to normal activity<sup>(5)</sup>. Open cholecystectomy (OC) has been associated historically with 0.2% to 0.5% risk of postoperative biliary injury<sup>(6)</sup>. LC, on the other hand, has been associated with a 2.5-fold to 4 fold increase in the incidence of postoperative bile duct injury<sup>(7, 8)</sup>. Evidence also suggests that the rate of bile duct injury after LC has remained constant even though most surgeons are beyond the “learning curve” phase<sup>(9)</sup>. This was illustrated in a report from a high-volume tertiary referral center, in which the frequency and distribution

of bile duct injuries detected by endoscopic retrograde cholangiopancreatography (ERCP) remained unchanged over a 9-year period (1994-2003)<sup>(10)</sup>.

Minor bile duct injuries can be well treated by endoscopic techniques<sup>(11)</sup>.

As a result, the biliary endoscopist is likely to be confronted with significant and difficult problems following cholecystectomy, regardless of how it is performed. An important sequel to this trend is the possibility that more complex cases of gallstone-associated illnesses the biliary endoscopist is likely to be confronted with significant are shunted to open surgical techniques<sup>(12)</sup>.

ERCP has assumed an important role because it facilitates evaluation and management of suspected biliary complications after cholecystectomy. However, routine preoperative ERCP is not cost-effective and is best reserved for patients with high likelihood of choledocholithiasis. Noninvasive techniques such as magnetic resonance cholangiopancreatography (MRCP) and endosonography are very helpful in evaluating patients with low probability of bile duct pathology before cholecystectomy. The spectrum of

complications that biliary endoscopist can expect to see after cholecystectomy is varied and includes retained calculi in the biliary tree (including the cystic duct remnant), iatrogenic bile duct injuries leading to postoperative biliary strictures, bile leak, and biliary enteric fistulae. The most serious complication is transection or inadvertent complete clipping of the bile duct <sup>(13)</sup>.

### Aim of the work

The aim of this work is to evaluate the role ERCP in management of post-cholecystectomy (open-laparoscopic) biliary complications.

## 2. Patients and Methods

These prospective study will be conducted in Al-Azhar University Hospitals (in a period from 9/2015 - 9/2018) evaluate ERCP in management of post-cholecystectomy biliary complications in about 30 cases who were subjected to cholecystectomy and suffering from biliary tree related complications such as external bile leak, localized bile collection, bile peritonitis, or obstructive jaundice, missed stone.

### All 30 patients will be subjected to the following:

- Full history (including age, sex) and clinical diagnosis (symptoms and signs such as pain, nausea, vomiting, fever, gundice, change of the colour of urine and stool, tenderness and rigidity, discharge of bile from the wound or from the drain).
- Laboratory investigations (ALT-AST-BILIRUBIN-ALK PH-G GT-PT-PC-INR-UREA-CREAT-CBC).
- Cardiopulmonary evaluation include X- ray chest, ECG, and or Echo if indicated.
- Abdomenopelvic ultrasound to all patients to document of the following:
  - Dilatation in biliary tree, localized bile collection, diffuse free peritoneal fluid and or calcular shadow in the CBD.
- CT in 3 cases, MRCP in 8 cases.
- PTC and PTD in selected one case as a drain before ERCP intervention.
- ERCP to all patients after preparation.

Patients who harbour any of the above finding will be subsequently subjected to ERCP to confirm the diagnosis of the presence of biliary complication and the use of the potential therapeutic options for these procedure of ERCP such as endoscopic sphincterotomy, dilataion, stone extraction, stenting of biliary tree.

Preparation of the patients include fasting before ERCP 6 hour, and routine preop labs and imaging studies if needed.

Patients were sedated with intravenous midazolam and meperidine, and duodenal relaxation was induced with hyoscine N-butyl bromide. ERCP was performed with the patient in the prone position, Sphincterotomy was performed in a standard manner using avariety of papillotomes. Stones were extracted with balloons or Dormia baskets following mechanical lithotripsy when necessary. If stenting was performed, apine tree (Soehandra Tannenbaum) catheter was used. We usually performed a small sphincterotomy as part of the stenting procedure. Papillary stenosis was diagnosed on the basis of clinical history, biochemical profile, and suggestive endoscopic findings.

Patients who underwent ERCP observed for a minimum of 1 hour and discharged from the unit if there was no evidence of pain, fever, unstable vital signs, or prolonged sedation.

Patients and their escorts were told to contact us if any symptoms developed. Follow-up evaluation results were obtained by review of the patient's medical records at Al-Azher university hospitals and/or by personal telephone interviews with referring doctors.

Stent removal is done after 2-3, months after insertin in non stricture complicated cases, removal and insertion of another stent is done in stricture diagnosed cases.

Follow up was every one week in the first month and every 3 months for in the first year, follow up labs and imaging study is ordered on selected cases to asses the efficacy of the ERCP.

### Statistical analysis

Descriptive data are expressed as mean, or ranges for continuous variables, and proportions for categorical variables. Because of the nature of the study design and the potential lack of comparability of the different groups, no inferential statistics were carried out. All data are shown solely for descriptive purposes.

## 3. Results

There were 30 patients, 19 female and 11 male, with a median age of 59 (range 18–85) years. A great majority of 20 patients (67%) had undergone surgery at an outside hospital and were referred to our department. The interval from surgery to referral to us ranged from 2 days to 48 months with a mean of 1.7 months for all patients (**Table 1**).

Table (1): Patients gender and age:

Patients characteristics	Total patients=30
<b>Gender</b>	
Male	11(36.7%)
Female	19 (63.30%)
<b>Age</b>	
Meane	43.75 ± 8.95
Median (IQR)	30 (15 - 45)
Range	18 – 74

The primary operation was listed in (Table 2).

Table (2): Previous surgeries:

Primary procedures	N	%
Laparoscopic cholecystectomy	18	(60)
Cholecystectomy + Common bile duct exploration +T-tube drainage	1	(3.3)
Open cholecystectomy	11	(36.7)
<b>Total</b>	<b>30</b>	<b>100</b>

The clinical presentations (symptoms and sings) was listed in (Table 3).

Table (3): Clinical presentations:

Presentations	Number of patients	percentage
-Change in colour of urin and stool	18	60%
-Nausea, vomiting	10	33.3%
-fever	5	16.6%
-Abdominal pain	16	53.3%
-Increasing amount of bile through a drain leake (early post operative)	3	10%
- Persistent bile leakage	1	3.3%
- Itching	5	16.6%

Abnormal Laboratory findings was listed in (Table 4).

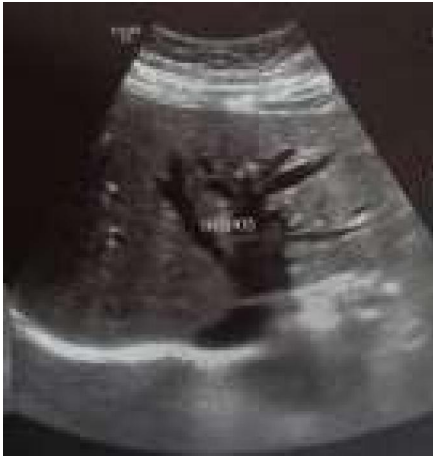Table (4): Abnormal laboratory findings:

Abnormal laboratory findings	No.	Percentage
Elevated ALT, AST	25	83.3%
Elevated ALK PH	24	80%
Elevated GAMMA GT	24	80%
Elevated BILIRUBIN TOTAL –DIRECT	23	76.6%
Elevated TLC	15	50%
Elevated UREA CREAT	11	36.6%

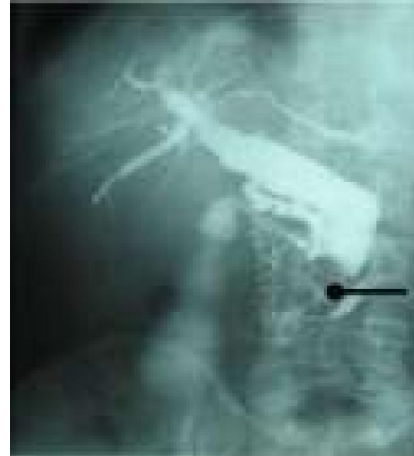
As regard Radiological findings was listed in (Table 5), (Fig. 1, 2, 3, 4, 5, 6).

Table (5): Radiological findings:

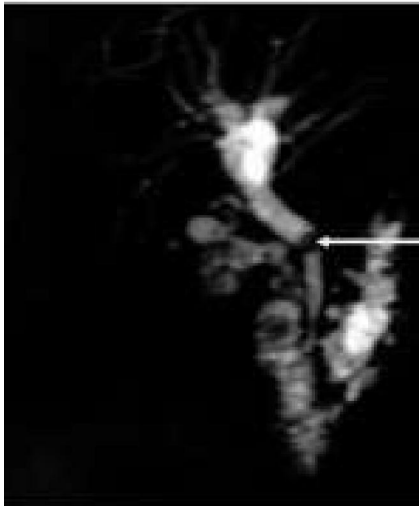
Radiological tool	No.	Abnormal finding	No
u/s	30	biliary dilatation with distal obstruction	20
		Abdominal collection	4
PTC	1	Dilated biliary tree with distal calcular shadow	1
MRCP	8	Dilated biliary tree with stone distally	6
		Dilated biliary tree without stone (stricture)	2
T-tube cholangiography	1	No flow to duodenum	1
CT (pelvi abdominal)	3	Abdominal collection	2
		Dilated IHBRD	1



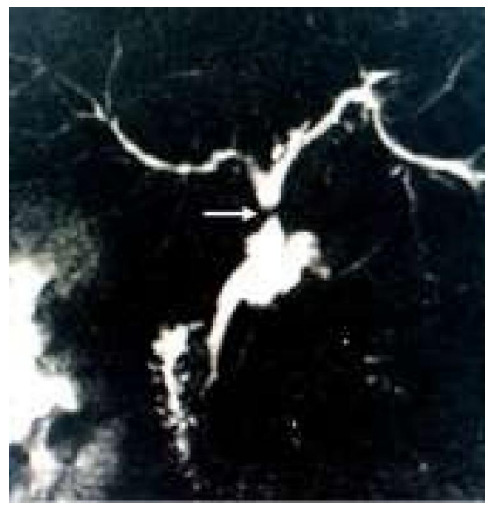**Fig. (1):** U/S show intrahepatic biliary radicles dilatation



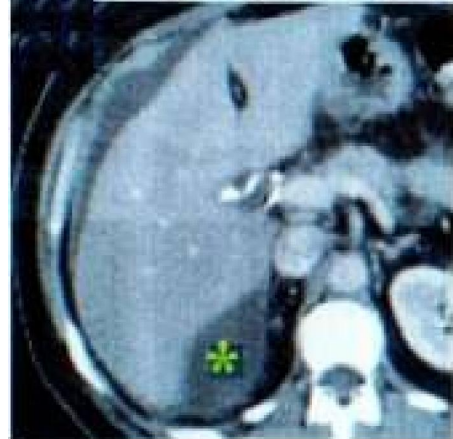
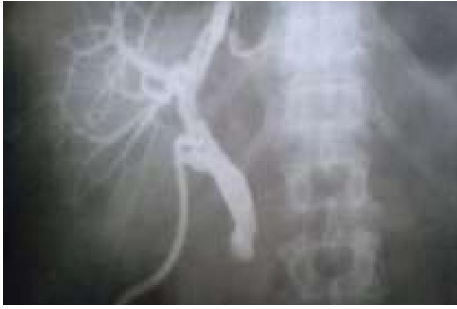**Fig. (2):** PTC show CBD dilataion and distal large CBD stone, IHBRD



**Fig. (3):** MRCP show dilated proximal biliary system with calc shadow.



**Fig. (4):** MRCP show stricture in CHD arrow site.



**Fig. (5):** T-tube cholangiography-revealing no flow into the duodenum **Fig. (6):** CT was done for patient with complete CBD transection coronal section show \* perihepatic collection.

Endoscopic findings and interventions are listed in *(Table 6)* (*Fig. 7,8,9,10,11,12,13*). When it was appropriate, all patients were managed endoscopically as shown in *(Table 6)*.

Table (6): Endoscopic findings and interventions:

Endoscopic findings	Laparoscopic cholecystectomy (n=18)	Choledocholithotomy + T-tube (n = 1)	Open cholecystectomy (n = 11)
Retained stone	Stone extraction, ES (8)	-	Stone extraction, ES (3)
Major CBD injury	Cholangiography (2)	-	Cholangiography (2)
Minor HD injury	ES, stent (1)	-	-
CBD stricture	Cholangiography, ballon dilatation, ES, stent (1)	-	-
Hepatic duct stricture	—	-	ES, stent (1)
Cystic stump leak	Stone extraction, ES, stent (5)	—	Stone extraction, ES (4)
T-tube leak	—	Stone extraction, ES, stenting (1)	—
Accessory duct leak	ES (1)	—	—
Failed cannulation	1	-	-

ES, Endoscopic sphincterotomy; CBD, Common bile duct  
Major CBD injury means injury over 50% duct circumference (including ligation, transection)

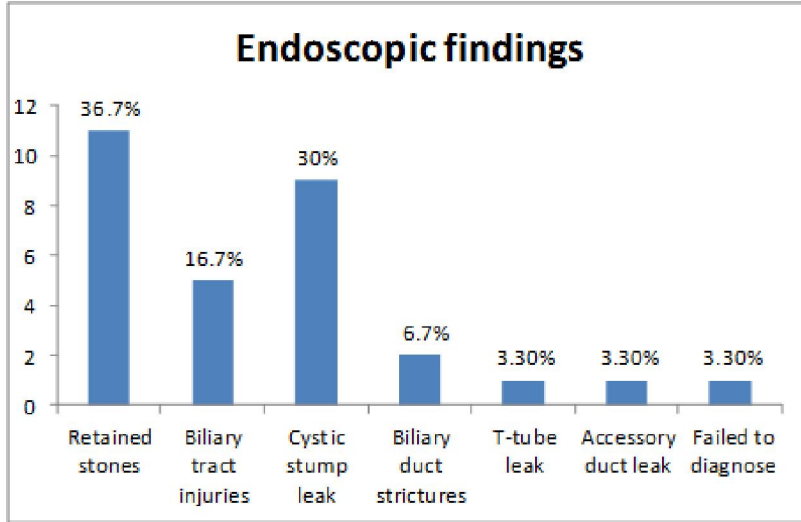


Fig. (7): Endoscopic findings.

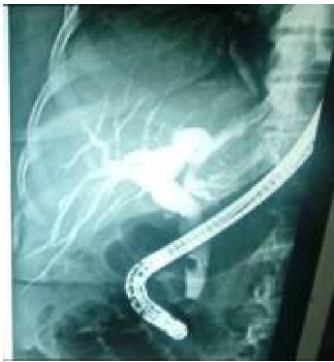

Fig. (8): Retained stones

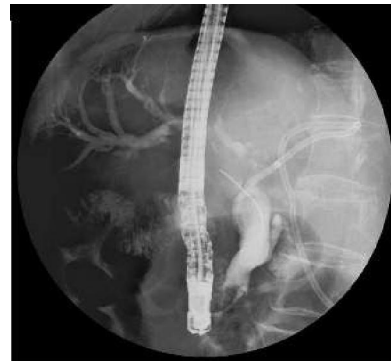

Fig. (9): PTC was done and ERCP failed to remove the large stone.

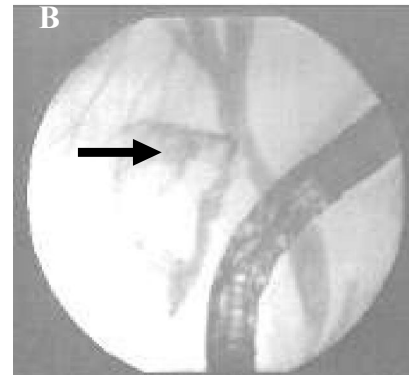
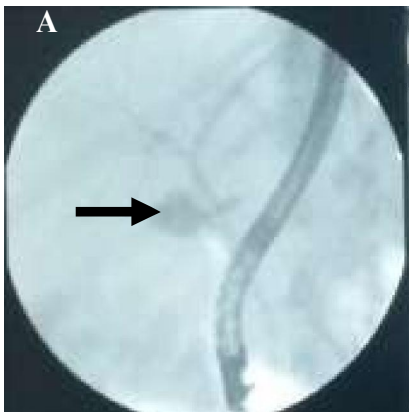
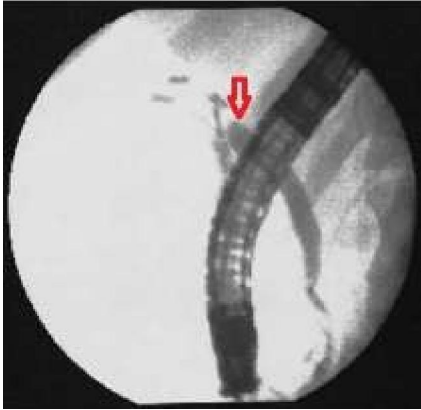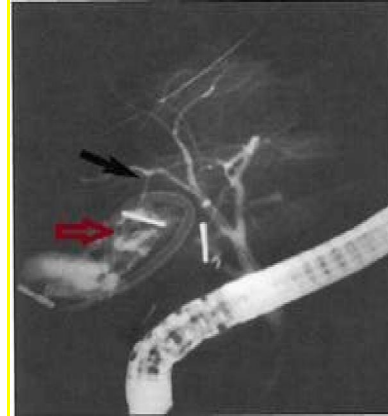


Fig. (10): A) Cystic stump leak and B) Extravasation of contrast into the subhepatic region from the side of a common bile duct following removal of the T-tube.



**Fig. (11):** ERCP show CBD transection, red arrow show arrested dye.



**Fig. (12):** Black arrow show accessory duct and red arrow show collection and Pigtail drainage tube.

Eight patients (26.6%) experienced transient abdominal pain with normal serum amylase level. 2 patients (6.6%) had raised levels of serum amylase indicating acute pancreatitis, and they all recovered with conservative therapy. Bleeding after sphincterotomy was observed in 2 (6.6%) patients. One of them responded neither to adrenalin injection nor to balloon tamponade and required duodenotomy for suturing of the bleeding site. Cholangitis occurred in one patient (3.3%) patients. The mean duration of hospital stay for all patients with ERCP-related complications was 13.8 days (range 2 to 20 days). The overall morbidity rate was 13.6%. No one died as a direct consequence of ERCP.

#### 4. Discussion

In our study ERCP has a high benefit role in management of post cholecystectomy complications whether early and late with success rate variable according to several factors and have a diagnostic sensitivity and therapeutic role in major of conditions with high success rate, less morbidity and mortality especially if done in tertiary well equipped hospitals by endoscopic expert.

ERCP is considered the gold standard in CBD imaging but should be reserved for patients with high probability of therapeutic intervention. The recognized complications of ERCP are post ERCP pancreatitis (5%), gastrointestinal hemorrhage, cholangitis, duodenal perforation and miscellaneous including cardio-respiratory. The overall procedure related mortality is less than 1%<sup>(14)</sup>.

In our review, 36.7% (11 patients) of postoperative ERCPs revealed CBD stones. Surprisingly, retained stones most commonly occurred in those patients who had laparoscopic cholecystectomy.

One patient suffered from retained stone after open CBD exploration. However, we could not explain why this patient with retained stones even after open CBD exploration. The success rate was high (90.9%) in all patients except in patients with large stone that lithotripsy cannot be done or anatomical variations as ampullary diverticulum.

With the advent of laparoscopic cholecystectomy, ES and stone extraction has become the usual procedure for treating common duct stones. As an alternative approach, laparoscopic CBD exploration is gradually gaining acceptance. A number of surgeons have reported success with laparoscopic duct exploration and stone extraction<sup>(15, 16)</sup>.

However, a limited number of surgeons have the necessary equipment or experience of laparoscopic duct exploration. Therefore, reliance on ERCP is more feasible in most centers. Cholecystectomy without cholangiography is commonly performed in the expectation that ERCP and sphincterotomy will be effective in dealing with retained CBD stones.

Surgeons must put in mind risk factors for development of CBD stone after laparoscopic cholecystectomy which suggested in acute cholecystitis, peri ampullary diverticulum, and the presence of GB stones sized less than 0.55 cm could be independent risk factors for the development of CBD stones at least 6 months after LC and detected consistently. Therefore, the surgeon should inform the possibility of the development of CBD stones after LC to the patients who have these risk factors even for long term after the operation<sup>(17)</sup>.

In cases of bile duct injury ERCP show a diagnostic importance more than therapeutic role and have a sensitivity in diagnosis superior to traditionally other tools.

CT scan and sonography are sensitive but nonspecific, but ERCP gives the opportunity to be sensitive, specific, and therapeutic and will rule out a major bile duct injury<sup>(18)</sup>.

In our study ERCP show atherapeutic role in minor duct injury which shown in our one patient which improved completely after stenting which the same in other studies.

**Abdallah**<sup>(11)</sup>, minor bile duct injuries can be well treated by endoscopic techniques.

**Siegel and Cohen**<sup>(19)</sup>, in minor ductal injuries, early use of ERCP facilitates closure of the leak by means of ES or stent insertion.

In major CBD injury ERCP show only a diagnostic tool and temporary therapeutic in selected preserved continuity biliary duct in which stenting can temporary improve condition but in general ERCP remain a diagnostic tool in such cases.

In our study of suspected bile leaks after cholecystectomy the commonest site of the leak was at the cystic duct stump, with a few cases in which the CBD and the common hepatic duct were damaged, which was in keeping with previously published studies<sup>(20)</sup>.

We found in our study that ERCP diagnosis of the leak site was straight forward and endoscopic management of the leak was successful with simple measures in all cases except where damage had arisen to the CBD, In cases biliary leakage due to cystic stump, t-tube, accessory duct leak, gall bladder bed collection ERCP has upper hand in diagnosis and treating these conditions with high success rate, which exactly reported in another studies.

**Lillemoe**<sup>(21)</sup> Endoscopic cholangiography is generally the first choice and may be all that is necessary for bile leaks that originate from lateral injuries, the cystic duct stump, or the gallbladder fossa.

It is important to recognize that not all bile leaks need to be treated; some heal spontaneously. In our series, one patient with minor ductal injuries underwent endoscopic stenting and responding well with no complications.

On the other hand, all major injuries required surgical reconstruction. Actually there is no place for definitive endoscopic therapy in such injuries<sup>(22)</sup>.

If ductal continuity is intact, stenting may play a role in closing leaks. This may give the opportunity to improve the timing of surgery or even avoid it entirely. However, in these cases, development of bile duct strictures is common. Endoscopy plays a major role in the diagnosis and treatment of patients with benign biliary strictures. Although operative treatment has better results, some late stenosis may be treated initially by balloon dilatation and/or long-term stenting. Endoscopic dilatation of biliary strictures has

been performed increasingly for strictures not amenable to operative correction and in high-risk patients. Resistant benign strictures may require insertion of a stent to maintain patency<sup>(23)</sup>.

This study included 2 patients with benign ductal strictures underwent ERCP dilatation, stenting. Although one of them underwent surgical reconstruction after repeated attacks of cholangitis persistent subclinical jaundice and vague abdominal pain, the second were managed by endoscopic stenting and still have no any problems till now with normalization of LFTS.

Nonoperative dilation of benign biliary strictures via endoscopic or percutaneous transhepatic access is an alternative to surgery that may be appropriate for some patients. Repeated dilations are often required, but overall success rates of 70%–80% at 2 to 3 years of follow-up have been reported. Success has generally been somewhat higher in patients with primary ductal strictures than in those with strictures of biliary-enteric anastomoses<sup>(24)</sup>.

Comparison between balloon dilation and surgery has demonstrated better long-term results (approximate mean follow-up at 5 years) with surgery, but no difference in overall morbidity, hospitalization, or cost between the two therapies. It cannot be ensured that the treatment groups are comparable, however. Nonoperative dilation of biliary strictures may be appropriate as initial treatment of a strictured biliary anastomosis or for patients in whom surgical repair is deemed excessively difficult or dangerous. The decision about how a biliary stricture is initially treated and when nonoperative maneuvers are abandoned in favor of surgery should be made in consultation with a skilled endoscopist, an interventional radiologist, and an experienced hepatobiliary surgeon<sup>(25)</sup>.

As regard of complications of ERCP in our hospitals in comparison with other studies are accepted with less morbidity, mortality.

Pancreatitis occurs as a complication of ERCP in approximately 5% of cases<sup>(26)</sup>. This ratio is similar to what we have experienced in our study as an ERCP-related pancreatitis (5.0%).

Limited cuts with ES reported to be associated with late stenosis **Jacobsen and Matzen**<sup>(27)</sup> reported a 30% decrease in diameter of the sphincterotomy opening during the second year. In the literature, late biliary complications after ES have occurred in 6–18% of patients during a mean follow-up of 10 years<sup>(28)</sup>.

Unfortunately, we could not figure out the late complication rate of procedures, since most of the patients were refused and/or lost to follow-up.



## Conclusion

Diagnostic and therapeutic endoscopic interventions may be indicated for numerous cholecystectomy complications. ES and stone extraction is the preferred therapy for retained or recurrent stones. Major biliary injuries generally require formal surgical reconstruction, but ERCP may afford the opportunity to delay surgery. ERCP is highly effective in resolving isolated bile leaks, whereas biliary strictures more often require surgery after an endoscopic palliation. Finally we recommend that ERCP as available in a district general hospital to investigate and treat biliary complications arising after cholecystectomy.

## References

1. Kapoor VK (2009): Management of bile duct injuries: a practical approach. *Am Surg.*, 75(1 2): 1157-60.
2. Langenbuch CIA (1882): Em fall von extirpation gallenblase wegen chroiscer cholelithiasis; heilung. *Ben Klin Wochenschr.*, 19:725-27.
3. Reynolds W (2001): The first laparoscopic cholecystectomy. *JSL.S.*, 2001; 5 (1): 89- 94.
4. Sawyer JL (1996): Current Status of conventional (open) cholecystectomy versus laparoscopic cholecystectomy. *Ann Surg.*, 1:1-3.
5. McMahon AT, Russell IT, Baxter JN *et al.* (1994): Laparoscopic versus minilaparotomy c. holecystectomy: a randomized trial. *Lancet*, 343:13S-138.
6. Peters JI, Ellison BC, Innes JT *et al.* (1991): Safety and efficacy of laparoscopic cholecystectomy. *Ann Surg.*, 213(1):3-12.
7. Deziel DJ, Millikan KW, Economoc SG *et al.* (1993): Complications of laparoscopic cholecystectomy: a national survey of 4,292 hospitals and an analysis of 77,604 cases. *Am J Surg.*, 165:9-14.
8. MacFadyen BV, Vecchio R, Ricardo AE *et al.* (1998): Bile duct injury after laparoscopic cholecystectomy. The United States experience. *Surg Endosc.*, 12: 3 15-321.
9. McMahan A, Baxter J, O'Dwyer P (1993): Preventing complications of laparoscopy. *Bij Surg.*, 80:1593-1594.
10. Khan MH, Howard TJ, Fogel EL *et al.* (2007): Frequency of biliary complications after laparoscopic cholecystectomy detected by ERCP: experience at a large tertiary referral center. *Gastrointest Endosc.*, 65:247=252.
11. Abdallah M (2011): Bile duct injuries associated with laparoscopic and open cholecystectomy: single center experience. *Egyptian Journal of Surgery*, 30(3): 48- 54.
12. Gholson CF, Dungan C, Neff G *et al.* (1997): Suspected biliary complications after laparoscopic and open cholecystectomy leading to endoscopic cholangiography. A retrospective comparison. *Dig Dis Sci.*, 43:534-539.
13. Pawa S, Al-Kawas FH (2009): ERCP in the management of biliary complications after cholecystectomy, 11(2):160-6.
14. Maurice E. Arregui (2006): in *Laparoscopic Cholecystectomy: Ultrasound for choledocholithiasis at The SAGES Manual Fundamentals of Laparoscopy, Thoracoscopy, and GI Endoscopy, Second Edition*, Carol E.H. Scott-Conner, MD.
15. Petelin JB (1993): Laparoscopic approach to common duct pathology. *Am J Surg.*, 165: 487-491.
16. Philips EH, Rosenthal RJ, Carroll BJ, Fallas MJ (1994): Laparoscopic transcystic duct common bile duct exploration. *Surg Endosc.*, 8: 1389-1394.
17. Yoo Shin Choi, Jae Hyuk Do, Suk Won Suh, Seung Eun Lee, Hyun Kang, Hyun Jeong Park (2017): Risk factors for the late development of common bile duct stones after laparoscopic cholecystectomy *Surg Endosc.*, 31:4857-4862.
18. Wise Unger S, Glick GL, Landeros M (1996): Cystic duct leak after laparoscopic cholecystectomy, a multi-institutional study. *Surg Endosc.*, 10: 1189-1193.
19. Siegel JH, Cohen SA (1994) Endoscopic treatment of laparoscopic bile duct injuries. *Gastroenterologist*, 2: 5-13.
20. Sharma H and Bird G (2011): Endoscopic Management of Postcholecystectomy Biliary Leaks Disclosures. *Frontline Gastroenterol.*, 2(4):230-233.
21. Lillemoe KD, Melton GB, Cameron JL, Pitt HA, Campbell KA, Talamini MA *et al.* (2000): Postoperative bile duct strictures: management and outcome in the 1990 s. *Ann Surg.*, 232(3):430-441.
22. Kozarek RA (1994): Endoscopic techniques in management of biliary tract injuries. *Surg Clin North Am.*, 74: 883-893.
23. Bilbao MK, Dotter CT, Lee TG, Katon RM (1976): Complications of endoscopic retrograde cholangi-opancreatography (ERCP) *Gastroenterology*, 70: 314-320.
24. Chari RS and Shah SA (2008): Biliary system. In: Townsend CM, Beauchamp RD, Evers BM, *et al.*, eds. *Sabiston Textbook of Surgery: The Biological Basis of Modern Surgical Practice*. 18th ed. Philadelphia: WB Saunders.
25. Mullholland MW, Lillemoe KD, Doherty GM *et al.* (2006): *Greenfield's Surgery: Scientific*

- Principles and Practice, Hepatobiliary and Portal Venous System Section. 4th ed. Philadelphia: Lippincott Williams & Wilkins; 2006.
26. Sherman S, Lehman GA (1991) ERCP- and endoscopic sphincterotomy-induced pancreatitis. *Pancreas*, 6: 350–367.
  27. Jacobsen O, Matzen P (1987): Long-term follow-up study of patients after endoscopic sphincterotomy for choledocholithiasis. *Scand J Gastroenterol.*, 22: 903–906.
  28. Sugiyama M, Atomi Y (1998): Follow-up of more than 10 years after endoscopic sphincterotomy for choledocholithiasis in young patients. *Br J Surg.*, 85: 917–921.

2/25/2019