

Can Apocynin protect the kidney from the harmful effect of Cadmium in rats?

Naglaa A.S. Sarg, Samia M. Manawy and Kamal M. Kamal

Anatomy and Embryology Department, Faculty of Medicine, Benha University, Egypt.
drsamiamanawy@yahoo.com

Abstract: Background: Cadmium (Cd) is an environmental and industrial pollutant with high toxicity and carcinogenic activity. Cd are used mainly in the manufacturing of pigments, plastics, batteries and coatings. It may accumulate in many organs. However, the main victim of Cd is considered the kidney. The mode of action of Cd to induce toxic effect through the diminution of protein-bound sulfhydryl groups and glutathione which leads to augment the release of reactive oxygen species (ROS). Apocynin (APO) is a natural organic compound isolated from the roots of *Apocynumcannabinum* (Canadian hemp). It is the finest known antioxidant and an inhibitor of NADPH oxidase. Apocynin has a low toxicity and can be applied in the treatment of arthritis, asthma, neurological, and cardiovascular illness through the anti-inflammatory and antioxidant impacts. **Aim of the work:** This work aims at evaluation of the protective role of apocynin on albino rat kidney exposed to environmental Cd. **Materials and Methods:** Twenty adult albino rats were randomly segregated into equal four groups. Rats of group I received distald water Group II: Each rat had received apocynin20 mg/kg/day. Those of group III had received cadmium chloride (2 mg/kg/day). In group IV each rat had received cadmium chloride (2 mg/kg /per day in distilled water) plus apocynin20 mg/kg/day. All drugs given daily intraperitoneally for 4 weeks. Then blood samples were taken for assessment of serum creatinine and blood urea. kidneys were removed and prepared for histological examination after staining the tissues by Hematoxylin and eosin (H x & E) and Masson's trichrome. Also an Immunohistochemical study was done to detect caspas-3. The mean area percentage of Caspaseimmuno-expression was quantified in five images from five non-overlapping fields of each rat. Statistical analysis of the obtained results by using IBM SPSS software. **Results:** Evaluation of renal function revealed a highly significant increase in the mean values of serum urea and creatinine in cadmium treated group as compared to those in Apocynine and Apocynine & Cadmium chloride treated groups (P<0.01). On examination of the kidneys of rats from (group III) that received cadmium chloride the tubules were degenerated and their lumens were dilated and filled with inflammatory cells with cytoplasmic vacuolation. Glomeruli were atrophied and renal spaces were dilated. The proximal convoluted tubules exhibited necrosis in the epithelial cells of the tubules, which subsequently involved the Lumen. The kidneys of rats treated with cadmium and apocinin showed normal glomeruli and Renal tubules although some tubules were still affected and showed dilatation. By using Masson's Trichromestain, the diffuse interstitial fibrosis was much more in the kidneys of rats treated with cadmium when compared with those of the control group and apocynine group. Kidneys treated with cadmium and apocynin showed less interstitial fibrosis in comparison to the cadmium chloride treated kidneys. Also, an area percent of Caspaseimmuno- reactivity was significantly higher in cadmium treated group as compared to Apocinine and Apocinine & Cadmium treated groups (P<0.01). **Conclusion:** Potential beneficial effects of APO in reducing cadmium chloride induced renal damage. [Naglaa A. S. Sarg, Samia M. Manawy and Kamal M. Kamal. **Can Apocynin protect the kidney from the harmful effect of Cadmium in rats?** *J Am Sci* 2019;15(2):60-69]. ISSN 1545-1003 (print); ISSN 2375-7264 (online). <http://www.jofamericanscience.org>. 8.doi:[10.7537/marsjas150219.08](https://doi.org/10.7537/marsjas150219.08).

Keywords: Apocynin, Antioxidant, cadmium, kidney

1. Introduction

Cadmium (Cd) is an environmental and industrial pollutant with high toxicity and carcinogenic activity. Industrial uses of Cd include manufacturing of batteries, pigments, coatings, and plastics (Odabaei et al., 2004). Furthermore, the addition of Cd to phosphate fertilizers may lead to pollution with Cd residues of both soil and underground water. With continuous fertilization of the plants with phosphate fertilizers, the level of Cd increased steadily and accumulates in soil and different parts of crops, specially grains, tobacco and root vegetables. Moreover, some aquatic animals contains high levels

of Cd, particularly mollusks and seals, in addition to crustaceans as crabs and oysters (Murugavel and Pari, 2010).

Environmental Cd may accumulate in many organs, such as lungs, particularly in smokers (Lechand Sadlik 2017) and testes (Interdonato et al., 2015), harmfully interfering with their functions. However, the main victim of Cd is considered the kidney (Yang and Shu 2015), where it accumulates, owing to the absence of a specific mechanism for elimination (Fouad and Jresat 2011).

The omission of reactive oxygen species (ROS) are documented by many authors in toxicity with Cd,

in both cell culture systems (He et al., 2008) and in different ways of exposing to Cd in living animals (Amara et al., 2008).

It has been suggested that the mechanisms of acute Cd toxicity involve the depletion of glutathione and protein-bound sulfhydryl groups, resulting in enhanced production of ROS such as superoxide ion, hydrogen peroxide, and hydroxyl radicals (Liu and Jan, 2000).

Cd-increased ROS in turn produces lipid peroxidation, and results in DNA damage (Liu et al., 2008).

Apocynin (APO) (4-hydroxy-3-methoxy acetophenone or acetovanillone), is a natural organic compound isolated from the roots of *Apocynum cannabinum* (Canadian hemp). It is the finest known antioxidant and an inhibitor of NADPH oxidase, (White et al., 2009). Apocynin, has a low toxicity and may be a promising potential therapy for asthma, arthritis, neurological, and cardiovascular diseases via its antioxidant and anti-inflammatory effects (Ramazan et al., 2013).

The aim of this work is to evaluate the role of Apocynin in albino rat kidneys and to propose it as an antioxidant tool in the therapy of nephrotoxicity induced by the exposure to environmental Cd.

2. Materials and Methods:

I-Materials:

1-Animals:

Twenty adult albino rats of an initial body weight 200 ± 50 g were used in order to perform this interventional- experimental study. The rats were obtained from the Animal House of the Faculty of Veterinary Medicine, Benha University, Egypt. The animals were housed in conventional conditions at a temperature of $25 \pm 1^\circ\text{C}$, with a relative humidity of $50 \pm 10\%$ and were maintained on a 12-hour light/dark cycle. They were acclimatized for a week and provided with a standard diet with free access to tap water.

All the ethical protocols for animal treatment were followed and supervised by the Animal House Facility.

2- Drugs:

A -Cadmium chloride

It was obtained from Sigma – Aldrich Company in the form of white powder a solution of cadmium chloride concentration of which 1 mg / 1ml was prepared (rat weighted 250mg received 0.25mg/0.25ml). The dose of cadmium chloride was given as 2 mg/kg/ B.W./day This dose had been reported to induce nephrotoxicity in rats without lethality (Ojo et al. 2014).

B-Apocynin

APO was acquired from Sigma – Aldrich Company. a solution of Apocynin concentration of

which 10 mg / 1ml was prepared (rat weighted 250 gm received 5mg /0.5ml). The dose was given as 20mg/kg /B.W./day (Cagin et al., 2015).

II- Methods:

1- Experimental design:

The rats were randomly segregated into following four groups.

Group I (Control group): the animals received (0.5 ml) of distilled water daily intraperitoneally by insulin syringe for 4 weeks.

Group II: Each rat received apocynin 20 mg/kg/ day intraperitoneally (in one dose) for 4 weeks.

Group III: Each rat received cadmium chloride (2 mg/kg /per day in distilled water) intraperitoneally for 4 weeks.

Group IV: Each rat received cadmium chloride (2 mg/kg /per day in distilled water) intraperitoneally for 4 weeks plus apocynin 20 mg/kg/ day intraperitoneally for the same period.

2- Sample Preparation:

The rats in each group were anesthetized with ether and sacrificed by means of cervical decapitation one week after giving the last dose in each treatment protocol then the rats were fixed on the operating table, anterior abdominal wall were incised longitudinally, the intestine was displaced to expose the IVC and both kidneys. Blood samples were taken from IVC for assessment of serum creatinine and urea in the Clinical Pathology Department, Faculty of Medicine, Benha University. Kidneys were excised and prepared for light microscope. Each sample of blood was centrifuged at 3,500 r.p.m. for 10 minutes and the serum was separated. Blood urea was measured in mg/dL with the use of the urea enzymatic assay (Orsonneau et al., 1992) and serum creatinine was measured in mg /dL according to the Jaffe method. (Michael et al., 2010)

3- Histopathological studies:

The kidneys were removed then fixed in 4% paraformaldehyde in 0.2M Phosphate-Buffered Saline (PBS), dehydrated in graded ethanol, cleared in xylene, and embedded in paraffin and sliced at 5 μm thickness by a microtome. Then, sections were deparaffined, rehydrated and stained with Hematoxylin and eosin (Hx & E) [Bancroft and Gamble 2008] and Masson's trichrome (MT) [Leong 1996]. Masson's trichrome stain was used to quantify the extent of fibrosis.

4- Immunohistochemical studies:

Immunohistochemical study of active caspase-3 was recently recommended for detection of cell apoptosis. Caspase 3 Immunohistochemical staining performed on 4- μm , formalin-fixed, paraffin-embedded sections using caspase 3 antibodies at 1:50 dilution (DAKO, Carpinteria, CA). Antigen retrieval was performed in all cases by steam heating the slides

in a 1-mmol/L solution of EDTA 7 (pH 8.0) for 30 minutes. After blocking of endogenous biotin, staining was performed using an automated immunostainer (DAKO) followed by detection by using a streptavidin-biotin detection system (DAKO). Analysis of tissue sections was performed by light microscopy. (Salama et al.,2016).

5- Morphometric study:

The mean area percentage of Caspase immun-expression was quantified in five images from five non-overlapping fields of each rat using Image-Pro Plus program version 6.0 (Media Cybernetics Inc., Bethesda, Maryland, USA).

6- Statistical analysis

All the data collected from the experiment was recorded and analyzed using IBM SPSS Statistics software for Windows, Version 20 (IBM Corp., Armonk, NY, USA). One-way analysis of variance (ANOVA) with Post Hoc LSD test was used to compare differences among the groups. In each test, the data was expressed as the mean (M) value, standard deviation (SD) and differences were considered to be highly significant at $P < 0.01$, significant at $P < 0.05$ and non-significant at $P > 0.05$.

3. Results:

Evaluation of renal functioning

The mean values of serum urea and creatinine in mg/dl for all groups were represented in table (1) and histograms (1 & 2).

The mean values of serum urea and creatinine were insignificantly lower in Apocynine-treated group than in the control group ($P > 0.05$). The mean values of serum urea and creatinine were significantly higher ($P < 0.01$) in cadmium treated group matched with control one. Also, average values of serum urea and creatinine were significantly high in cadmium- treated group as compared to Apocynine and Apocynine & Cadmium chloride-treated groups ($P < 0.01$).

Histological results:

Hematoxylin and eosin stain:

Sections of the renal tissues from rats in the control group (group I) showed normal morphology and structure of both glomeruli (renal corpuscles) and tubules. Each glomerulus shows a dense rounded structure which was surrounded by narrow space called renal space (Bowman's space). The glomerulus composed of cluster of small capillaries covered by the Bowman's capsule.

The proximal convoluted tubules had narrow lumens and were lined by a single layer of columnar cells with rounded, basal, vesicular nuclei. The distal convoluted tubules had wide lumens and were lined by low cubical cells (Fig 1).

The kidney under effect of Apocynin only was more or less normal and showed no histological

changes on glomeruli or tubules. Glomeruli were surrounded by normal narrow Bowman's space and composed of tuft of small capillaries which was covered by the Bowman's capsule. Where, the tubules were of normal lumen and diameter. The proximal convoluted tubule lined with columnar epithelium and the distal tubules lined with cubical epithelium (Fig.2). Kidneys of rats from (group III) that received cadmium chloride showed different histological changes. Degeneration of the renal tubules and the lumen of tubule were dilated and packed with desquamated epithelial lining and cytoplasmic vacuolation. The glomeruli were atrophied and the renal space was dilated. The epithelial cells of the proximal convoluted tubules were necrosed, which mostly detached and accumulated into the lumen.

(Fig. 3).

Kidneys treated with Cadmium and Apocynin showed a nearly normal structure of the kidney architecture. The glomeruli consists of tuft of capillary surrounded by normal space. Most of tubules are normal lumen and diameter. Although some tubules were still affected and showed dilatation (Fig. 4).

Masson's Trichromestain:

Diffuse fibrosis was much more in the interstitial tissue in cadmium chloride -treated group (group III) (Fig.7) in compared to the control (group I) which has minimal fibrous tissue in a narrow interstitial space. (Fig.5), and when compared with apocynin- treated group (group II) (Fig.6). Group IV (Cadmium and Apocynin- treated group) showed less fibrosis in the space. (Fig. 8).

Caspase-3 immunostain:

The degree of nuclear apoptosis was evaluated by. Immunohistochemical staining of caspase-3. Positive caspase-3 immune reaction appears as brown cytoplasmic staining. The more positive the reaction, the more apoptosis is. Kidneys from control and apocynin groups showed a weak brown staining of Caspase 3 expression in the cytoplasm of renal epithelia (Figs 9,10). Kidneys treated with cadmium chloride (Fig 11) showed strong immunoreactions of many epithelial cell cytoplasm of renal tubules. Kidneys treated with cadmium and apocynin (Fig 12) showed a much lower expression of caspase-3.

Morphometric results:-

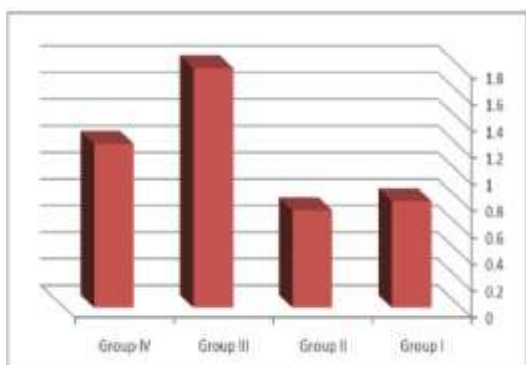
The mean area % of Caspase immun-expression for all groups was represented in Table (2) and Histogram (3). It was (6.35 ± 1.82) in group I, (11.77 ± 2.13) in group II, (38.81 ± 14.67) in group III and (16.51 ± 1.38) in Group IV. Caspase immun-expression was insignificantly higher ($P > 0.05$) in Apocynin (Fig10) and Apocynin & cadmium treated groups (Fig.12) as compared with the control group (Fig.9) The mean area % of Caspase immunoreactivity was significantly high increase in cadmium

chloride- treated group (Fig.11) as compared to the control group (P<0.01). Also, the mean area % of Caspaseimmuno- reactivity was significantly high in

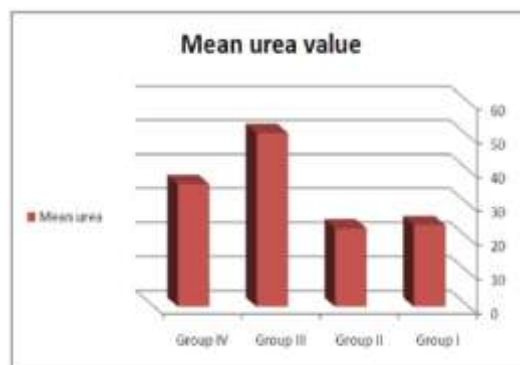
cadmium -treated group as compared to Apocynin and Apocynin & Cadmium- treated groups (P<0.01).

Table (1): showing mean values of urea & creatinine ± SD in the 4 groups

(mg/dl) Mean ± SD	Group I	Group II	Group III	Group IV	F test	P value
Urea	24.0 ± 1.0	23.0 ± 1.0	51.0 ± 1.0	36.0 ± 1.0	513.0	0.000
Creatinine	0.80 ± 0.10	0.73 ± 0.057	1.8 ± 0.10	1.23 ± 0.057	108.79	0.000
Significance ≤ 0.01	With groups III & IV	With groups III & IV	With groups I, II & IV	With groups I, II & III		



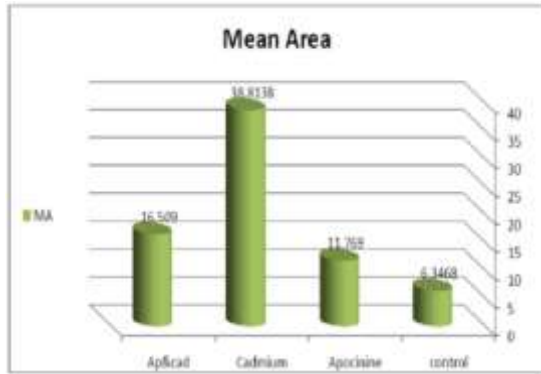
Histogram (1): Showing the mean value of creatinine in all groups



Histogram (2): Showing the mean value of urea in all groups

Table (2) : Showing the mean area % and SD of Caspaseimmuno-expression in groups I, II, III and IV with a comparison between all groups by Post Hoc LSD test.

Group	Mean±SD	Comparison	Sig	f	
Control	6.35±1.82	Control	Apocinine treated	0.327	14.45 8
			Cadmium treated	0.00**	
			Apocinine & Cadmium treated	0.079	
Apocinine treated	11.77±2.13	Apocinine treated	Control	0.527	
			Cadmium treated	0.00**	
			Apocinine & Cadmium treated	0.389	
Cadmium treated	38.81±14.67	Cadmium treated	Control	0.00**	
			Apocinine treated	0.00**	
			Apocinine & Cadmium treated	0.001*	
Apocinine & Cadmium treated	16.51±1.38	Apocinine & Cadmium treated	Control	0.079	
			Apocinine treated	0.389	
			Cadmium treated	0.001*	



Histogram (3): Showing the mean area % of Caspase-immuno-expression in all groups

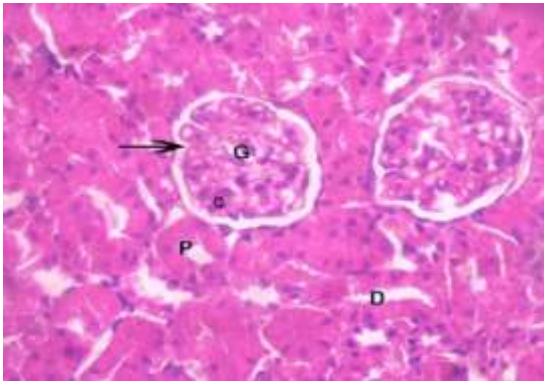


Fig. (1): A Photomicrograph of rat kidney from group I (control group) showing a normal tissue with normal, glomeruli (G), capillary tuft (c) and renal space (arrow). Normal tubules, proximal tubule (P), and distal tubule (D). (H & Ex400)

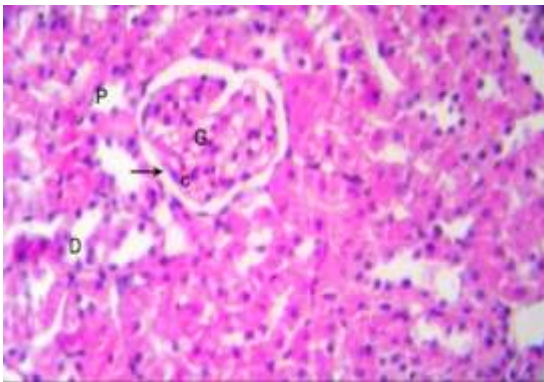


Fig (2): A Photomicrograph of kidney from group II which received apocynin only showing: Normal features of glomeruli (G), renal space (arrow) and capillary tuft (c). Normal tubules, proximal (P) and distal (D). (H & Ex400)

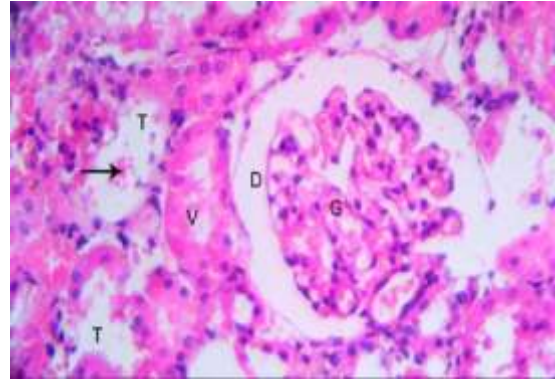


Fig (3): A Photomicrograph of kidney from group III which received cadmium chloride showing: Dilatation of tubules (T), dilatation of glomeruli (D), the glomerulus is segmented (G). The tubules have vacuation (V), the lumen of some tubules contains eosinophilic material (arrow). (H & E x400).

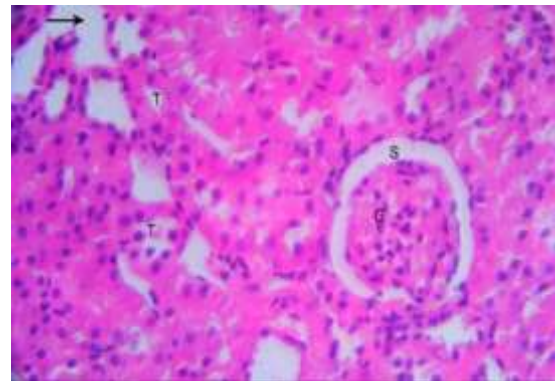


Fig (4): A Photomicrograph of kidney from group IV which received apocynin and cadmium chloride showing: The glomeruli (G) are more or less normally formed of capillary tuft surrounded by narrow normal renal space (S). Most of tubules are of normal lumen (T), but some of them were still affected & dilated (arrow). (H & Ex400)

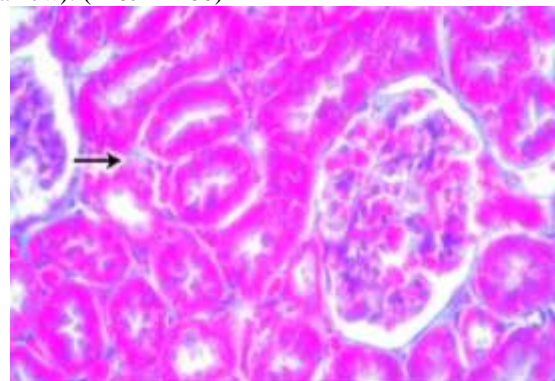


Fig. (5): A Photomicrograph of rat kidney from control group I showing: The interstitium has a narrow space with minimal connective tissue (arrow). (Massontrichromex400)

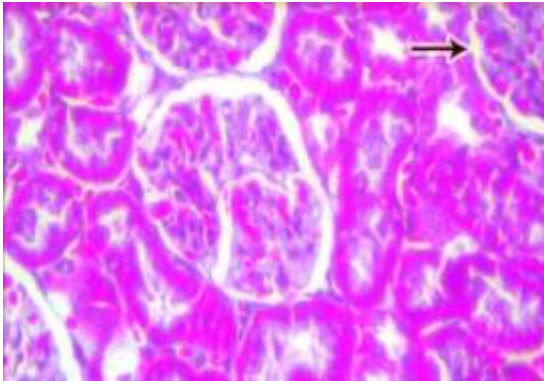


Fig (6):) A Photomicrograph of rat kidney from group II which received apocynin only showing: The interstitium has a narrow space with minimal connective tissue (arrow). (Massontrichromex400)

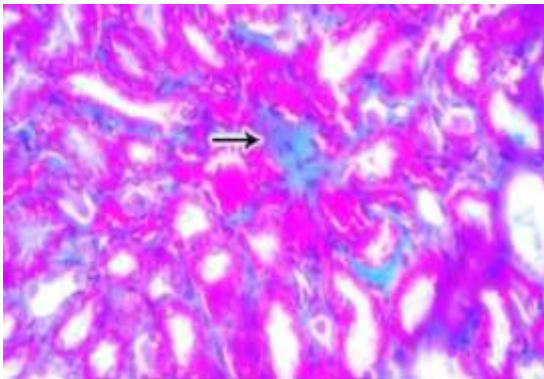


Fig. (7):) A Photomicrograph of rat kidney from group III which received cadmium chloride showing: Diffuse fibrosis in interstitium, fibrotic area is stained in blue (arrow). (Masson trichrome x400)

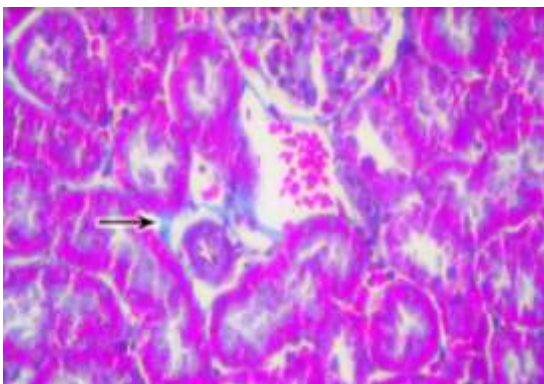


Fig (8):: A Photomicrograph of kidney of rat from group IV which received cadmium chloride and Apocynin showing: Less fibrosis in interstitium (arrow). Note: The interstitial hemorrhage in between the tubules. (Masson trichromex400)

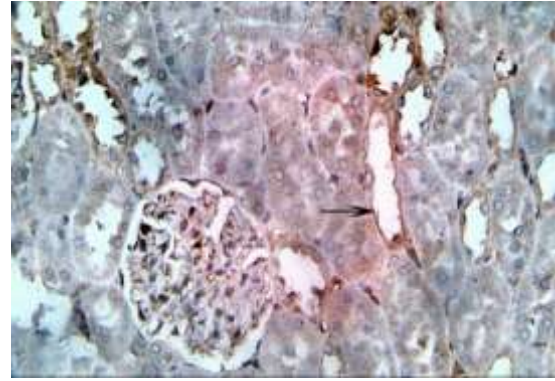


Fig (9): A photomicrograph of rat kidney from control (group I) showing weak expression of caspase-3 in the epithelia of few renal tubules (arrow) (caspase-3 x400)

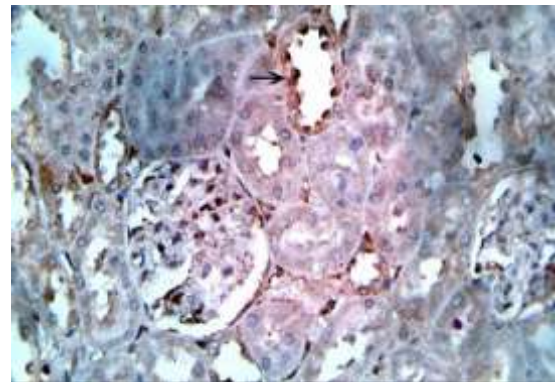


Fig. (10): A photomicrograph of rat kidney from group II which received Apocynin showing: A weak expression of caspase-3 in the epithelia of few renal tubules (arrow). (caspase-3x400)

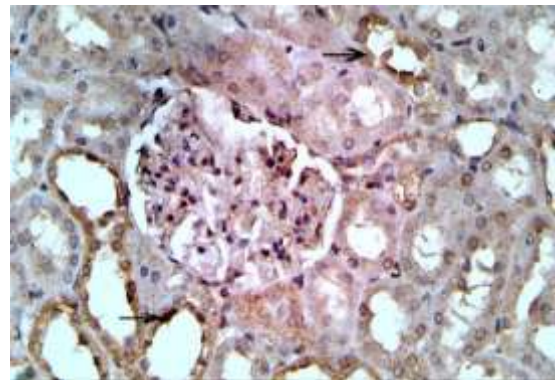


Fig (11): A photomicrograph of rat kidney from (group III) which received cadmium chloride showing positive expression of caspase-3 in the epithelia of renal tubules (arrow). (caspase-3x400).

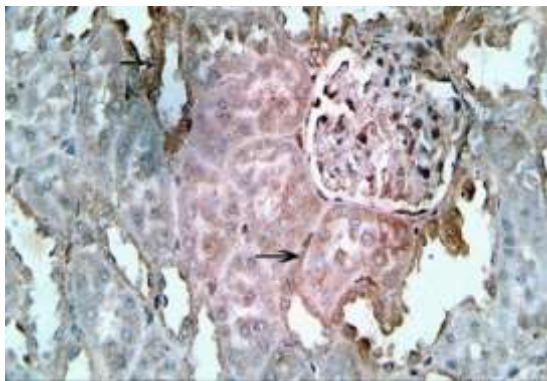


Fig. (12): A photomicrograph of kidney from group IV which received cadmium & Apocynin showing: A weak expression of caspase-3 in the epithelia of renal tubules (arrow).(caspase-3x400)

4. Discussion:

The adverse influence of cadmium pollution on the environment and its surroundings including human and animals is due to its ability to accumulate in the tissues, which leading to metabolic disorders and histopathological alterations.. The purpose from the present work is to study the protecting impact of Apocyninon Cd-toxicity in kidney due to oxidative stress. Many investigators found that antioxidant enzyme activities are altered after Cd intoxication which may be returned to oxidative stress (ROS) from Cd (Liu et al.,2008). The antioxidant enzymes play an important role in counteracting from ROS adverse effects, the most antioxidant enzymes are SOD, GPx and catalase enzymes. Cd pollution leads to lipid peroxidation which adversely affectson the integrity of cell membranes and causes itsdamage.

Kidneys dysfunction may be occur due to sever exposure to the toxicants and elevated levels of excreted substances via the epithelia of renal tubules. **Thevenod, 2003**, reported that the chronic accumulation of Cd in the renal tissues of rat resulted in obvious deterioration in the oxidative enzymes activities and more than 50% of total Cd stored in the body are accumulated in the renaltissues.

In this work, rats had received cadmium chloride (2 mg/kg /per day in distilled water) intraperitoneally for 4 weeks and by histopathological examination, the tubules were degenerated, their lumens were dilated and filled with desquamated epithelial cells and cytoplasmic vacuoles. Glomeruli were atrophied with dilated renal space. The proximal convoluted tubules of the kidney showed necrosis in the epithelial cells of the tubules which may extend to the Lumina. Also, there were a diffuse interstitial fibrosis was observed. Also, many alterations may occur due to Cd intoxication such as tubular damage (**Aoyagi et al., 2003**), and glomerular shrinkage and tubular damage

(**Jemai et al., 2010; El-Refaiy and Eissa, 2013 and Akomolafe et al., 2016**). Others, found that Cd induced toxicity in the epithelial cells of renal tubules mainly and in the glomeruli partially (**Brzoska et al., 2004**).

El-Refaiy and Eissa, 2013found that nephrotoxicity especially degeneration and shrinking of the glomeruli and tubular pyknosis with vacuolated cytoplasm were showed post exposure to cadmium. Results of this study were in agreement with the results of **Jemai et al., (2010)**, they recorded that the capillaries in the glomeruli were affected from Cd intoxication particularly of Bowman's space, in addition to atrophy of someglomeruli.

Coccini et al., 2015 and Chen et al., 2016 found that exposure to cadmium for 1,or 1.5 or 3 months resulted in different degrees of deposition of collagen fibers in the kidney, which increased around blood vessels and within the renal tubules .

In the present study, the epithelia of renal tubules showed a positive expression of caspase-3, which indicate apoptosis. This result was similar to that of **Hagar and Al Malki (2014)** who said that the Caspase-3 activity was increased in kidney tissues of rats treated with cadmium, as an indicator for DNA damage. **Guiping et al., (2014)** found that, the caspase-3 protein expression had been increased in rats exposed to Cadmium. These changes had resulted in an increased number of apoptotic cells around renal tubular epithelial cells in kidneys of the exposed rats. **Green, 2000**, suggested that an oxidative injury might arise in mitochondria which are responsible for the discharge of proapoptotic proteins into the cytosol, which lead finally in cellular apoptosis. Explanation of the ability of Cd to induce apoptosis is via reduction in the expression of miRNA 125-a, and 125-b which enhances the apoptotic processes (**Sarah and Christy, 2017**).

In the present study, administration of Apocyninto Cd-treated rats resulted in an improvement in the tubular structure and the glomeruli appeared more or less normal with normal capsular space. **Ramazan et al (2013)** found that although mild tubular changes, such as tubular atrophy and desquamation, were present, the glomeruli were intact in the rats received apocynin and its administration decreased the expression of apoptotic cells. The coloring density and the number of caspase-3-stained tubular cells werelow.

Abdelrahman, 2017, proposed that the nephrotoxic effect and oxidative damage caused by GNT can be overcome by treatment with APO through improvement in the tissue morphology.

These results were in line with the previous results which suggested that Apocynin inhibited free

radical generation and increased antioxidant defense in testicular tissues against I/R (**Sener et al., 2015**). The mechanism by which Apocynin could decrease the tissue oxidative damage may be due to its direct antioxidant effect (**Petronio et al., 2013**).

An increase in the SOD /GPx activity ratio in the renal tissues due to Cd exposure is an indicator for high release of free radicals like H₂O₂. **Asagaet. Al. (2008)** explained that, Apocynin increased GPX which is important component of the protective mechanism of the cell against lipid peroxidation and oxidative stress. Also, GPX convert hydrogen peroxide to water, thus they prevent the formation of more reactive-free radicals. **Nazima et al., (2015)** found that CdCl₂-treated rats showed an increased expression of Inducible Nitric Oxide Synthase (iNOS) in renal tissue, which could be related to the generation of ROS secondary to the structural lesions of tubular epithelial cells. Apocynin acts as a NOX inhibitor and is widely Investigated as anti-oxidative and anti-inflammatory agent, which alleviates oxidative stress (**Liu et.al.,2016**). Also, it was suggested that Apocynin prevented the enhancement of NOX gene and protein expression (**Castro et al.,2012**).

In the present study, the concentrations of creatinine and urea in the plasma of rats were estimated as biomarker for renal function. In the present study, a significant elevation in the levels of creatinine and urea in the serum in rats exposed to Cd chloride in comparison with the control group, which revealed to impairment and dysfunction in kidney. Many researchers found that Cd induced an elevation in urea and creatinine levels. Increased urea and creatinine may be due to increase oxidative stress and free radicals which may progress to tissue damage and apoptosis [**El-Morsy et al., 2015 & El-Boshy et al., 2015**].

The elevation in the levels of urea and creatinine in the current work may be returned to the combination of Cd to metallothionin in the hepatic tissues, then discharged in the plasma, at that time cleaned in the glomeruli and reabsorbed by the renal proximal convoluted tubules which leading to its damage (**Thévenod,2003**).

Though, this study found a significant drop in creatinine and urea concentration in Cd and the Apocynin co-treated group versus Cd-treated group.

Sahna et al. (2006) stated that, Apocynin improved the elevation of serum levels of BUN and Cr is caused by impairment of glomerular function.

These finding are also supported by those found by(**Yayi et al., 2016**) who stated that, Apocynin has beneficial effect on renal function and improved the kidney damage may be due to reduction of oxidative stress and reduced lipid peroxidation and may prevent apoptosis.

the nephrotoxic effect and oxidative damage caused by GNT can be ameliorated by the treatment with APO and significantly decreasing serum Cr and BUN (**Abdelrahman,2017**).

Conclusion:

The present study suggests that apocynin was able to significantly reduce CdCl₂-induced oxidative damage secondary to ROS generation in the kidney. Apocynin reduced morphological changes of glomeruli and proximal tubules, which are known as key renal targets for Cd. That might occur though attenuation of oxidativestress.

References:

1. Abdelrahman RS (2017): Protective effect of apocynin against gentamicin-induced nephrotoxicity in rats. *J Of Human And Experimental Toxcology*; 37 (1), page (s):27-37.
2. Akomolafe RO, Imafi don CE, Olukiran OS et al (2016): Livolin forte ameliorates cadmium-induced kidney injury in Wistar rats. *Ser J Exp ClinRes*;17(2):107–116.
3. Amara S, Abdelmelek H, Garrel C, Guiraud P, Douki T, Ravanat JL, Favier A, Sakly M, Ben Rhouma K. (2008): Preventive effect of zinc against cadmium-induced oxidative stress in the rat testis. *J Reprod Dev.*;54:129–134.
4. Aoyagi T, Hayakawa K, Miyaji K et al (2003): Cadmium nephrotoxicity and evacuation from the body in a rat modeled subchronic intoxication. *Int J Urol*;10:332–338.
5. Asaga T, Ueki M, Chujo K and Taie S (2008): JTE607, an inflammatory cytokine synthesis inhibitor, attenuates ischemia/ reperfusion-induced renal injury by reducing neutrophil activation in rats. *J Biosci Bioeng*;106:22-26.
6. Bancroft J. D. and Gamble M. (2008): Theory and practice of histological techniques. 6th ed. Churchill Livingstone. London, New York & Sydney, PP.121-132.
7. Brzoska MM, Kaminski M, Dziki M et al (2004): Changes in the structure and function of the kidney of rats chronically exposed to cadmium. II. Histoenzymatic studies. *Arch Toxicol*; 78(4):226–231.
8. Cagin YF, Erdogan M, Sahin N, Parlakpınar H, Atayan Y et al. (2015): Protective effects of apocynin on cisplatin-induced hepatotoxicity in rats. *Arch MedRes.*;46(7):517-526.
9. Castro M. C., Francini F., Schinella G., Caldiz C. I., Zubiría M. G., Gagliardino J. J., et al. (2012): Apocynin administration prevents the changes induced by a fructose-rich diet on rat liver metabolism and the antioxidant system. *Clin. Sci. (Lond)*; 123 (12):681-92.

10. Chen J, Du L, Li J et al (2016): Epigallocatechin-3-gallate attenuates cadmium-induced chronic renal injury and fibrosis. *Food Chem Toxicol*;96:70–78.
11. Coccini T, Barni S, Mustarelli P et al (2015): One-month persistence of inflammation and alteration of fibrotic marker and cytoskeletal proteins in rat kidney after Cd-doped silica nanoparticle instillation. *Toxicol Lett*;232:449–457.
12. El-Boshy M. E., Risha E. F., Abdelhamid F. M., Mubarak M. S., Hadda T. B. (2015): Protective effects of selenium against Cd induced hematological disturbances, immunosuppressive, oxidative stress and hepatorenal damage in rats. *J. Trace Elem. Med. Biol*; 29, 104.
13. El-Morsy A. M., Sakr S. A., Bayomy M. F. (2015): Ameliorative effect of aqueous leaves extract of *Rosmarinus officinalis* on Cd induced kidney injury in albino Rats. *J Biosci Appl Res*; 1 (1),10.
14. El-Refaiy A. and Eissa FI (2013): Histopathology and cytotoxicity as biomarkers in treated rats with cadmium and some therapeutic agents. *Saudi J Biol Sci*;20(3):265–280.
15. Fouad A. A. and Jresat I., (2011): “Protective effect of telmisartan against cadmium-induced nephrotoxicity in mice,” *Life Sciences*; vol. 89, no. 1-2, pp.29–35.
16. Green DR. (2000): Apoptotic pathways: paper wraps stone blunts scissors. *Cell*;102:1–4. 87. 91, 169–200.
17. Guiping Yuan, Shujun Dai, Zhongqiong Yin, Hongke Lu, Renyong Jia, Jiao Xu, Xu et al., (2014): Sub-chronic lead and cadmium co-induce apoptosis protein expression in liver and kidney of rats. *Int J Clin Exp Pathol*; 2014; 7(6): 2905–2914.
18. Hagar H. and Al Malki W. (2014): “Betaine supplementation protects against renal injury induced by cadmium intoxication in rats: role of oxidative stress and caspase-3,” *Environmental Toxicology and Pharmacology*; vol. 37, no. 2, pp. 803–811.
19. He X, Chen MG, Ma Q. (2008): Activation of Nrf2 in defense against cadmium-induced oxidative stress. *Chem Res Toxicol.*; 21:1375–1383.
20. Interdonato, M. Pizzino, G. Bitto A. et al., (2015): “Cadmium delays puberty onset and testis growth in adolescents,” *Clinical Endocrinology*; vol. 83, no. 3, pp.357–362.
21. Jemai, H., Lachkar, H. A., Messaoudi, I., Kerkeni, A., (2010): Effect of zinc pre-treatment on blood glutathione, serum zinc and kidney histological organization in male rats exposed to cadmium. *Journal of Trace Elements in Medicine and Biology*; 24 (4), 277–288.
22. Lech T. and Sadlik J. K., (2017): “Cadmium concentration in human autopsy tissues,” *Biological Trace Element Research*; vol. 179, no. 2, pp.172–177.
23. Leong, A. S. (1996): Principles and practice of medical laboratory science. Volume 1: Basic Histotechnology. 1st ed., Philadelphia, Saunders Company. P.171.
24. Liu F, Jan KY. (2000): DNA damage in arsenite- and cadmium-treated bovine aortic endothelial cells. *Free Radic Biol Med.*;28:55–63.
25. Liu J, Qian SY, Guo Q, Jiang J, Waalkes MP, Mason RP, Kadiiska KB. (2008): Cadmium generates reactive oxygen- and carbon-centered radical species in rats: Insights from in vivo spin-trapping studies. *Free Radic Biol Med.*; 45:475–481.
26. Liu W, Feng GH, Ou Y, Xu J, Zhang ZJ et al. (2016): Neuroprotective effect of apocynin in oxygen glucose deprivation-treated SH-SY5Y cells and rats with ischemic stroke. *Tropical Journal of Pharmaceutical Research*; 15(8):1681-1689.
27. Michael L., Edward P. and Larry E. (2010): *Clinical Chemistry Techniques, Principles, Correlations*. 6th ed., Wolters Kluwer Health, Lippincott. Williams & Wilkins. New York P.564-67.
28. Murugavel P. and Pari L. (2010): Effect of diallyltetrasulfide on cadmium induced oxidative damage in the liver of rats. *Hum. Exp. Toxicol*; 26:527–534.
29. Nazima, B. Manoharan V., and Miltonprabu S., (2015): “Grape seed proanthocyanidins ameliorates cadmium-induced renal injury and oxidative stress in experimental rats through the upregulation of nuclear related factor 2 and antioxidant responsive elements,” *Biochemistry and Cell Biology*; vol. 93, no. 3, pp.210–226.
30. Odabaei, G.; Chatterjee, D.; Jazirehi, A. R.; Goodglick, L.; Yeung, K.; Bonavida, B. (2004): Raf-1 kinase inhibitor protein: Structure, function, regulation of cell signaling, and pivotal role in apoptosis. *Adv. Cancer Res.*;91:169-200.
31. Ojo OA, Ajiboye BO, Oyinloye BE, Ojo AB, Olarewaju OI. (2014): Protective effect of Irvingia gabonensis stem bark extract on cadmium-induced nephrotoxicity in rats. *Interdiscip Toxicol*; 7:208-214.
32. Orsonneau JL, Massoubre C, Cabanes M, et al. (1992): Simple and sensitive determination of urea in serum and urine. *Clin Chem*;38:619–23.
33. Petronio M. S., Zeraik M. L., Fonseca L. M and Ximenes V. F (2013): Apocynin: Chemical and

- biophysical properties of a NADPH oxidase inhibitor. *Molecules*; 18 (3): 2821-39.
34. Ramazan Altintas,, Alaadin Polat, Nigar Vardi, Fatih Oguz, Ali Beytur, Mustafa Sagir, Azibe Yildiz, and Hakan Parlakpinar. (2013): The Protective Effects of Apocynin on Kidney Damage Caused by Renal Ischemia/Reperfusion *Journal Of Endourology*;27 (5), Pp. 617–624.
 35. Sahna E, Parlakpinar H, Cihan OF, Turkoz Y and Acet A. (2006): Effects of aminoguanidine against renal ischemia-reperfusion injury in rats. *Cell Biochem Funct.*;24:137–141.
 36. Salama AAA, Mostafa RE, Omara EA. (2016): Ameliorative effects of phosphodiesterase (PDE) inhibitors in potassium dichromate-induced acute renal failure in rats. *Int J Pharm Sci Rev Res.*; 36(2):40-6.
 37. Sarah E. Orr and Christy C. Bridges (2017): Chronic Kidney Disease and Exposure to Nephrotoxic Metals. *Int. J. Mol. Sci.*; 18,1039.
 38. Sener T. E., Yuksel M., Ozyilmaz-Yay N., Ercan F., Akbal C., Sim, Sek F., et al. (2015): Apocynin attenuates testicular ischemia-reperfusion injury in rats. *J. Pediatr. Surg.*, 50 (8):1382-7.
 39. Thevenod, F. (2003): Nephrotoxicity and the proximal tubule. *Insights from cadmium. Nephron Physiol.*, 93,87–93.
 40. White CN, Figtree GA, Liu CC, Garcia A, Hamilton EJ, Chia KK and Rasmussen HH (2009): Angiotensin II inhibits the Na+K+ pump via PKC dependent activation of NADPH oxidase. *Am J Physiol Cell Physiol*; 296: C693C700.
 41. Yang H. and Shu Y., (2015): “Cadmium transporters in the kidney and cadmium-induced nephrotoxicity,” *International Journal of Molecular Sciences*; vol. 16, no. 1, pp. 1484–1494.
 42. Yayi H, Yeda X, Huaxin W, Yang W ,Qian S et al (2016): Toll- like receptor 7 involve the injury in acute kidney ischemia /reperfusion of STZ-induced diabetic rats. *Acta Cir.Bras*;31(7):488-55

25/2/2019