

The efficacy and safety of Endovascular embolization for treatment of cervicofacial arteriovenous malformation in children

Ahmed Gaber Hassanein^{1,2}, Mohammed Hasan Osman³ and Fahd Nasser Al Qahtani⁴

¹Maxillofacial Surgery Unit, General Surgery Department, Sohag Faculty of Medicine, Sohag University, Egypt.

²Maxillofacial Surgery Department, Faculty of Dentistry, Al-Baha University, Kingdom of Saudi Arabia

³Maxillofacial Surgery Unit, General Surgery Department, Assiut University Hospital, Assiut, Egypt

⁴Radiology Department, Faculty of Medicine, Al-Baha University, Kingdom of Saudi Arabia

E-mail: ahmedgaber_74@yahoo.com

Abstract: Introduction: The arteriovenous malformations are uncommon in the maxillofacial region. Their management is complex and thus multidisciplinary approach gives the best outcomes. Endovascular techniques are considered the treatment of choice and are often combined with the surgical resection of the lesion. The aim of this work is to present the outcome achieved with endovascular embolization in the treatment of large cervicofacial arteriovenous malformations in a group of selected patients. **Patients and methods:** children with arteriovenous malformations of the cervicofacial region were treated by endovascular embolization and were followed up clinically and radiologically to evaluate the outcome and detect the complications **Results:** This study included 8 patients with cervicofacial AVMs. They were 3 males and 5 females with age range from one month to 10 years. The presenting symptoms were cosmetic deformity in 7 cases, bleeding attacks in 5 cases, functional impairment in 4 cases in the form of chewing problems in two patients, breathing problem in one patient, and tinnitus in another one. pain was present in two cases. Their AVMs had different locations in the cervicofacial region. Six cases were treated in multiple staged embolization sessions while two patients were treated by a single session. The endovascular embolization caused the complete regression of the lesion in most cases with improvement of the cosmetic and functional problems in all cases. **Conclusion:** Endovascular embolization is safe and efficient treatment option for the management of cervicofacial AVMs in children and should be considered as priority choice for treatment.

[Ahmed Gaber Hassanein, Mohammed Hasan Osman and Fahd Nasser Al Qahtani. **The efficacy and safety of Endovascular embolization for treatment of cervicofacial arteriovenous malformation in children.** *J Am Sci* 2018;14(8):21-26]. ISSN 1545-1003 (print); ISSN 2375-7264 (online). <http://www.jofamericanscience.org>. 3. doi:[10.7537/marsjas140818.03](https://doi.org/10.7537/marsjas140818.03).

Key words: Endovascular embolization, arteriovenous malformations (AVMs), mandible, check, Onyx

1. Introduction

Vascular malformations are uncommon lesions in the cervicofacial region with incidence rate about 0.3 % of live births. 90 % of patients are clinically diagnosed during the first months of life.(1, 2) The vascular malformations are classified into low-flow (capillary, venous or lymphatic) and high-flow malformations (arterial malformation and arteriovenous fistula)(3, 4).

Arteriovenous malformations (AVMs) represent only 1.5% of all vascular anomalies. However, 50% of these occur in the cervicofacial region. The oral mucosa and lips are the most frequently affected areas(5). These lesions usually increase in size during adolescence and adulthood. Their spontaneous regression is very rare. Pain, tissue expansion, ulceration and bleeding may complicate when the malformation reaches a large size(6).

The clinical presentation often related to the type of vascular anomaly.(7) Symptoms of cervicofacial AVMs vary and range from asymptomatic lesions to cosmetic morbidities and severe clinical

manifestations such as pain, ulceration, life threatening bleeding, and neuropathy. Moreover, they can complicate phonation, respiration and swallowing. Frequently, the patients have a long medical history and a psychosocial problems.(8, 9)

The management of AVMs is complicated. It includes observation, (10) medical management, surgical resection, endovascular embolization, or ablation, and often, a combination of several approaches (11, 12). Multidisciplinary approach gives better results.(13, 14). Endovascular techniques are considered the treatment of choice, and are often combined with surgery(15).

The aim of this work is to present the outcome achieved with endovascular embolization in the treatment of large cervicofacial AVMs in a group of selected patients.

2. Patients and Methods

This is a retrospective study performed in the maxillofacial surgery units at, Sohag University Hospital, Sohag, Egypt and Assiut University

Hospital, Assiut, Egypt during the period from October 2013 to July 2018 after approval by the institutional human research and ethics committee and the parents or legal guardians of the patients signed an informed consent. We reviewed the medical files of the children with AVMs who were treated endovascularly. Clinical data were collected from the patients' medical records regarding presenting symptoms, signs, and pretreatment imaging studies. These patients received endovascular embolization treatment. The embolization procedures were performed through transfemoral approach under general anesthesia on a biplane C-arm angiography system. Onyx was used as a liquid embolic agent. All the patients were followed up clinically and radiologically to evaluate the outcome regarding:

1. Control of bleeding if present.
2. Functional outcome: improvement of the impaired function as chewing, breathing, hear in.
3. The cosmetic outcome was assessed using a prefabricated0 to 10 score scale, the esthetics was divided into good (8–10 score), fair (5–7 score), and poor (0–5 score).
4. Evaluation of patient or family satisfaction: using visual analogue scale.
5. Angiographic obliteration on follow up evaluation.
6. Detection of complications.

3. Results

This study included 8 patients with cervicofacial AVMs presented to our departments and managed by endovascular embolization during the period from October 2013 to July 2018. They were 3 males and 5 females with age range from one month to 10 years. The presenting symptoms were cosmetic deformity in 7 cases, bleeding attacks in 5 cases, functional impairment in 4 cases in the form of chewing problems in two patients, breathing problem in one patient, and tinnitus in another one. pain was present

in two cases. Their AVMs had different locations in the cervicofacial region. Six cases were treated in multiple staged embolization sessions while two patients were treated by a single session.

Regards the Outcome:

a. Control of bleeding was achieved after the first session of embolization in all cases that had bleeding attacks.

b. Functional outcome: all cases showed improvement of the impaired function as chewing, breathing, hearing.

c. The cosmetic outcome was good in six cases, fair in two cases, and poor.

d. Patients' or family satisfaction: in all cases the total outcome was satisfactory. The level of all satisfaction ranged from 87% to 98% with a mean of 94.7%.

e. Angiographic obliteration on follow up evaluation: five cases had complete obliteration of the lesions, two cases had more than 90% obliteration and one patient had more than 50% obliteration.

f. The follow-up period ranged from 10 to 38 months with a mean of 24.9 months. No clinical or radiological recurrence was detected in cases.

The data of the patients were presented in table (1). The details of Three case will be illustrated.

Case 1:

A5-yeargirlwas admitted due to severe epistaxis. She had redness and swelling of the upper lip and nose. Digital Subtraction Angiography (DSA) of the head and neck arteries showed a high-flow AVM of the nose and upper lip. Trans-arterial super-selective microcatheter embolization of the AVM was done with Onyx that resulted in a significant reduction of the shunt and control of epistaxis (figure 1). A second session of endovascular embolization was done after one month led to complete angiographic obliteration of the AVM. At the follow up, the child had no attacks of epistaxis and the facial cosmetic deformities disappeared.

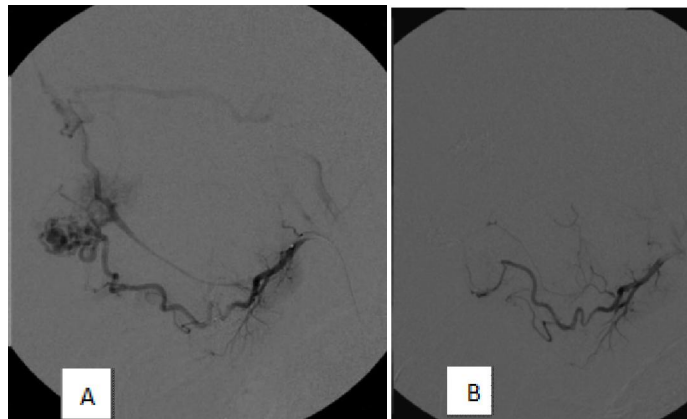


Figure (1): A 5-years girl presented with severe epistaxis:

- (A) Pre-embolization lateral view of facial artery angiogram showing AVM with the feeding arteries, the AVM nidus, and the early draining vein.
- (B) Post-embolization lateral view of a facial artery injection showing complete occlusion of the AVM.

Case 2:

A 9 years old girl presented with disfiguring painful swelling and redness of the right cheek and functional restriction in chewing. Past-history revealed a surgical intervention but without satisfactory results. MRI and DSA revealed a high-flow AVM of the left check with feeding arteries arising from the facial

artery, maxillary artery, and superficial temporal artery. multiple trans-arterial super-selective embolizations with Onyx through 3 years resulted in a complete angiographic occlusion of the AVM (figure 2). After endovascular treatment the patient became free of pain and here mastication improved. Also, disfigurement of the face disappeared.

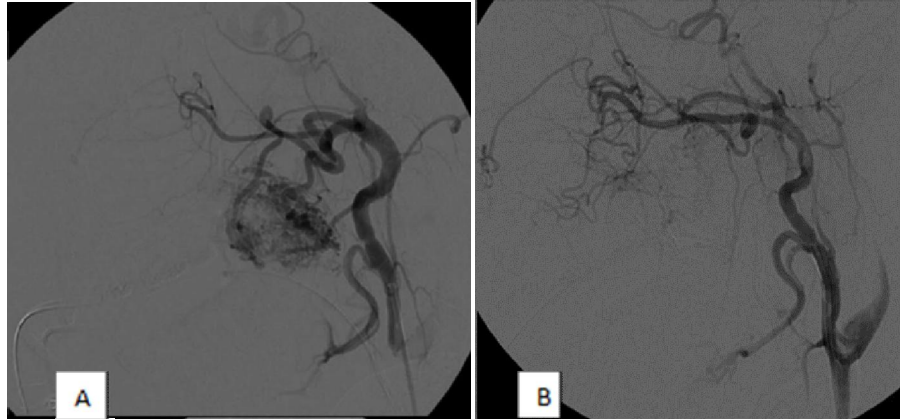


Figure (2): A 9-years old girl presented with disfiguring painful swelling and redness of the right cheek and functional impaired chewing:

- (A) Initial digital subtraction angiogram, lateral view of a left external carotid artery injection demonstrating the buccal AVM.
- (B) Normal external carotid artery angiogram in lateral after several trans-arterial embolization of the AVM.

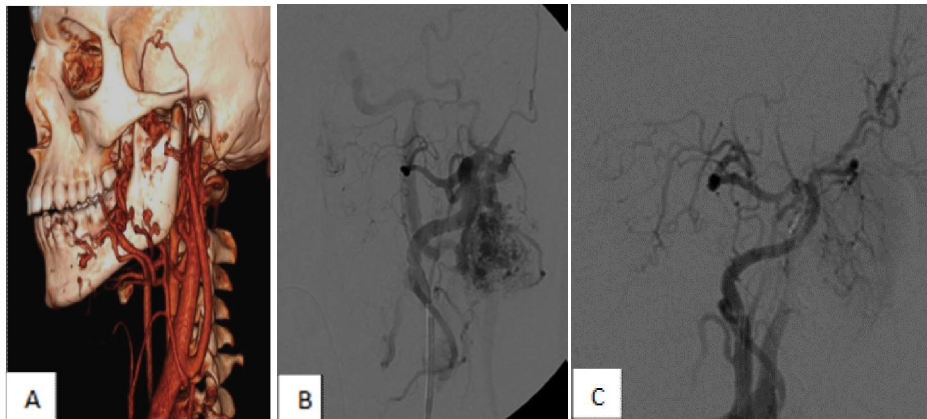


Figure (3): A 10 years old female presented with left sided lower spontaneous gum bleeding

- (A) 3D CT image of the arteriovenous malformation extending from the right mandibular body to the pterygoid region and infratemporal fossa.
- (B) Initial digital subtraction angiogram, lateral view of a left external carotid artery injection demonstrating the buccal AVM.
- (C) Normal external carotid artery angiogram in lateral after several trans-arterial embolization of the AVM.

Case 3:

A 10 years old female presented with a recent history of left sided lower spontaneous gum bleeding of one-week duration with no history of trauma or

bleeding disorders. Clinical examination showed a gum swelling, bleeding and mobility of the left mandibular first and second molars. Panorama x-ray showed radiolucent periapical lesion consistent with a

small cyst of dental origin. Head and neck CT scan detected a large high-flow intraosseous arteriovenous malformation involving the left mandibular body, angle, ramus and extending to the infratemporal fossa. Selective angiography and MRI of head and neck identified the extent of the malformation, the feeding

vessel and a large drainage vein. Embolization of drainage vein and the selective embolization of the main feeding arterial vessels was done. Postoperative MRI showed complete regression of the lesion. Two years later angiography and MRI did not detect any signs of recurrence.

Table (1): data of the patients:

Case no.	Age and sex	Location of the AVM	Presenting symptoms	Embolization sessions	Angiographic obliteration	Follow up period
1	5 years female	upper lip and nose	Pain Bleeding Cosmetic deformities	2	100%	22 months
2	9 years female	right cheek	Chewing problems Cosmetic deformities	3	100%	28 months
3	10 years female	Left side of mandible and cheek	Bleeding	1	100%	36 months
4	1 month male	Forehead	Bleeding Cosmetic deformities	3	> 90%	38 months
5	2 years female	Nose, right eyelid	Bleeding Breathing problems Cosmetic deformities	2	100%	18 months
6	8 years male	Maxilla, palate, cheek	Bleeding Chewing problems Cosmetic deformities	4	> 90%	15 months
7	6 years male	Lower lip, mandible, neck	Pain Cosmetic deformities	2	> 50%	32 months
8	9 years female	Right auricular	Tinnitus Cosmetic deformities	1	100%	10 months

4. Discussion

The management of cervicofacial AVMs is challenging. There are multiple treatment modalities for AVMs including surgical excision, laser therapy, endovascular embolization, or a combination of these procedures. Complete surgical excision is only rarely achieved. The multi-disciplinary approach and use of interventional radiology techniques revolutionized the treatment of such lesions and reduced the morbidity related to surgical management (16).

The aim of treatment of cervicofacial AVMs should always be the closure of the whole nidus, ideally both the inflow and outflow zones. The endovascular procedure of our choice is primarily a trans-arterial super-selective microcatheter-based approach followed by embolization using liquid embolic agents with different viscosities to achieve a casting of the whole nidus.(17)In this study, we used Onyx as an embolic agent. The safety and clinical efficacy of Onyx for embolization of extracranial vascular anomalies has recently been proven.(18) Onyx injection requires increased fluoroscopy and procedure time,(19)which might lead to an increased radiation dose for the eye. Superficial Onyx

embolization is assumed to cause darkish skin discoloration due to the suspended micronized tantalum powder. However, in our study we did not note marked cutaneous discoloration.(20)We also noted that prolonged and repeated Onyx injections within the same AVM pedicle are possible and allow it to be pushed more distally toward and within the nidus.

In this study, we presented 8 cases of AVM in the cervicofacial region using the endovascular approach for the embolization of the main supplying arteries and drainage vein. Most of the cervico facial AVM are usually treated with the selective embolization of the main arteries(18, 21). In our series, surgery was not preferred because we thought that the abundant collateral circulation formed by the malformation and the extension of the lesion would not allow a surgery with clean margins. Also, with the complex anatomy of cervicofacial region, extensive resection, massive bleeding and functional and cosmetic morbidity may result. The embolization technique achieved a complete reduction of the AVM and avoided a disastrous surgery.

The main goal of endovascular embolization is never just the occlusion of a vessel or the reduction of flow, but rather the reduction of AVM-related risks and symptoms such as bleeding, pain, and necrosis.(22)In this study, complete disappearance of the swelling, facial cosmetic deformity and functional disability were achieved with no morbidity. Multiple treatment sessions are nearly always required to get complete ‘cure’ of this lesion.(23)In our study, multiple treatment sessions were required in six cases to achieve complete cure while only two cases responded after a single session treatment.

In accordance with other studies, we believe that endovascular embolization of cervicofacial AVMs is a safe and effective treatment modality and can be performed either as the main treatment or as preoperative embolization prior to surgical procedures or laser therapy (23).

In our opinion, a multidisciplinary approach is essential. A careful clinical and radiological evaluation of the lesion is necessary for appropriate treatment. The choice of treatment modality depends on the age of the patient, the size and the location of the lesion. Also, the expertise and availability of endovascular management.

Conclusion

Endovascular embolization is safe and efficient treatment option for the management of cervicofacial AVMs in children and should be considered as priority choice for treatment.

Disclosure:

Fund: no fund was obtained for this work.

Conflicts of Interest: no conflict of interest.

The study was approved by the institutional ethics and research committee.

The patients or their legal guardians signed informed consent before being included in this report.

Correspondence:

Dr. Ahmed Gaber Hassanein

Address: General Surgery Department, Sohag Faculty of Medicine, Sohag, Egypt.

Telephone no. 00201157651422 - 00966554055181

E-mail: ahmedgaber_74@yahoo.com

References

- Garzon MC, Huang JT, Enjolras O, Frieden IJ. Vascular malformations: Part II: associated syndromes. *Journal of the American Academy of Dermatology*. 2007;56(4):541-64.
- Finn MC, Glowacki J, Mulliken JB. Congenital vascular lesions: clinical application of a new classification. *Journal of pediatric surgery*. 1983;18(6):894-900.
- Mulliken J, Glowacki J. Hemangiomas and vascular malformations in infants and children a classification based on endothelial characteristics. *Plast Reconstr Surg* 1982; 69: 412-420. Natural history of cavernous haemangiomas.
- Enjolras O, Mulliken JB. Vascular tumors and vascular malformations (new issues). *Advances in dermatology*. 1997;13:375-423.
- Kumar A, Mittal M, Srivastava D, Jaetli V, Chaudhary S. Arteriovenous malformation of face. *Contemporary clinical dentistry*. 2017;8(3):482.
- Kohout MP, Hansen M, Pribaz JJ, Mulliken JB. Arteriovenous malformations of the head and neck: natural history and management. *Plastic and reconstructive surgery*. 1998;102(3):643-54.
- Brugge KGt, Berenstein A. Surgical neuroangiography: clinical and interventional aspects in children. 2006.
- Persky MS, Yoo HJ, Berenstein A. Management of vascular malformations of the mandible and maxilla. *The Laryngoscope*. 2003;113(11):1885-92.
- Niimi Y, Song JK, Berenstein A. Current endovascular management of maxillofacial vascular malformations. *Neuroimaging Clinics of North America*. 2007;17(2):223-37.
- Dmytriw A, Ter Brugge K, Krings T, Agid R. Endovascular treatment of head and neck arteriovenous malformations. *Neuroradiology*. 2014;56(3):227-36.
- Perkins JA, Manning SC, Tempero RM, Cunningham MJ, Edmonds Jr JL, Hoffer FA, et al. Lymphatic malformations: review of current treatment. *Otolaryngology—Head and Neck Surgery*. 2010;142(6):795-803. e1.
- Yun W-S, Kim Y-W, Lee K-B, Kim D-I, Park K-B, Kim K-H, et al. Predictors of response to percutaneous ethanol sclerotherapy (PES) in patients with venous malformations: analysis of patient self-assessment and imaging. *Journal of vascular surgery*. 2009;50(3):581-9. e1.
- Lee K-B, Kim D-I, Oh S-K, Do Y-S, Kim K-H, Kim Y-W. Incidence of soft tissue injury and neuropathy after embolo/sclerotherapy for congenital vascular malformation. *Journal of vascular surgery*. 2008;48(5):1286-91.
- Donnelly LF, Adams DM, Bisset III GS. Vascular malformations and hemangiomas: a practical approach in a multidisciplinary clinic. *American Journal of Roentgenology*. 2000;174(3):597-608.
- Fowell C, Linares CV, Jones R, Nishikawa H, Monaghan A. Venous malformations of the head and neck: current concepts in management.

- British Journal of Oral and Maxillofacial Surgery. 2017;55(1):3-9.
16. Fowell C, Jones R, Nishikawa H, Monaghan A. Arteriovenous malformations of the head and neck: current concepts in management. *British Journal of Oral and Maxillofacial Surgery*. 2016;54(5):482-7.
 17. Brassel F, Meila D. Evolution of embolic agents in interventional neuroradiology. *Clinical neuroradiology*. 2015;25(2):333-9.
 18. Thiex R, Wu I, Mulliken J, Greene A, Rahbar R, Orbach D. Safety and clinical efficacy of Onyx for embolization of extracranial head and neck vascular anomalies. *American Journal of Neuroradiology*. 2011;32(6):1082-6.
 19. Lv X. Comparison of N-butyl Cyanoacrylate and Onyx for the Embolization of Intracranial Arteriovenous Malformations—Analysis of Fluoroscopy and Procedure Times. *Operative Neurosurgery*. 2017;13(6): E37-E8.
 20. Paramasivam S, Niimi Y, Fifi J, Berenstein A. Onyx embolization using dual-lumen balloon catheter: initial experience and technical note. *Journal of Neuroradiology*. 2013;40(4):294-302.
 21. Gemmete JJ, Ansari SA, McHugh J, Gandhi D. Embolization of vascular tumors of the head and neck. *Neuroimaging clinics of North America*. 2009;19(2):181-98.
 22. Meila D, Grieb D, Greling B, Melber K, Jacobs C, Hechtner M, et al. Endovascular treatment of head and neck arteriovenous malformations: long-term angiographic and quality of life results. *Journal of neurointerventional surgery*. 2016: neurintsurg-2016-012570.
 23. Karim AB, Lindsey S, Bovino B, Berenstein A. Oral surgical procedures performed safely in patients with head and neck arteriovenous malformations: a retrospective case series of 12 patients. *Journal of Oral and Maxillofacial Surgery*. 2016;74(2):255. e1-. e8.

8/13/2018