

The Role of Color Doppler Ultrasound in Evaluation of Deep Veins Thrombosis of Lower Extremities

Moawia Gameraddin^{1,2*}, Suzan Abdelmaboud², Sultan Alshoabi¹, Fathelrahman Alagab¹, Mohamed Yousif³, Tahani Gibreel,²

¹Department of Diagnostic Radiologic Technology, Faculty of Medical Applied Sciences, Taibah University, Almadinah Almunawwarah, Saudi Arabia. Fax:00966 8475790 P.O: 30001 KSA. E-mail: m.bushra@yahoo.com
(corresponding Author)

²Faculty of Radiological Sciences and Medical Imaging, Alzaiem Alazhari University, P.O.Box 1432. Khartoum Bahri, 13311-Sudan.

³College of Medical Radiologic Science, Sudan University of Science and Technology.P.O.Box 1908, Khartoum, e-mail: mohnajwan@gmail.com .Sudan

Abstract: Deep vein thrombosis is one of the main serious vascular diseases which may lead to death and serious complication if left undiagnosed and untreated. Color Doppler is one of the accurate and safe imaging modality which plays a great role in diagnosis and management. Objective: to evaluate Sudanese patients with suspected deep venous thrombosis of the lower extremities using color Doppler ultrasonography. Materials and methods: the study population composed of 150 patients (different ages and gender) with suspected deep venous thrombosis at the lower extremities. They had been investigated with color Doppler using high frequency linear transducer. The protocol begins with the patient in supine position from upper thigh till foot with longitudinal and transverse scanning to examine the veins from the common iliac veins down to calf veins. Extent of thrombus was determined by locating the proximal end of thrombus and documenting it with longitudinal and transverse scans. Results: patients with symptoms and signs of DVT at lower limbs had been referred to ultrasound department to be examined with Color Doppler imaging. The results being as follows; DVT involved males higher than females (59.33 % vs. 40.67%). The age group of 35-39 years old is the most affected group (25.33%). Patients who have had an occupation were more affected ones than patients without an occupation (61.33 vs. 38.67%). Surgery is the most common risk factors (34%) & trauma is the second (20.67%). Swelling and pain were the most common symptoms of DVT (96% & 94%) respectively. The left popliteal vein was the most commonly involved vessel with DVT (30%) and left common femoral vein is the second affected vein (18%). Extension of DVT was observed in 20% of the cases. Conclusion: Color Doppler ultrasonography is very sensitive, accurate and safe to assess deep venous thrombosis of the lower limbs. It could determine location, extension and size of thrombi.

[Moawia G, Suzan A, Sultan A, Fathelrehman A, Tahani G, Mohamed, Y. **The Role of Color Doppler Ultrasound in Evaluation of Deep Veins Thrombosis of Lower Extremities.** *J Am Sci* 2015;11(2):124-128]. (ISSN: 1545-1003). <http://www.jofamericanscience.org>. 16

Key words: Color, Doppler, Evaluation, Deep, Venous, Thrombosis.

1. Introduction

Deep vein thrombosis (DVT) is a blood clots forming in the deep veins often of the leg, pelvic or abdomen but can also occur in the arm veins. It is a serious healthcare problem. A among patients with (DVT), one third of them are presented with pulmonary embolism (PE). The long-term effects of (DVT), the so called post-thrombotic syndrome (PTS), affects about 500,000 patients with skin ulcers and millions more with discoloration and other skin changes in the legs. The annual number of DVT events in the European Union (EU) is estimated at over 684,000; (Geerts WH, Bergqvist D, Pineo GF et al. 2008) in the United States (US), the rate of non-fatal symptomatic DVT events is estimated to be more than 376,000 per year (Cohen AT, Agnelli G, Anderson FA, et al, 2007). Because of its great risk, prevention of DVT from ever forming is very important. In order to prevent (DVT) and (PE) some

knowledge of who is at risk is needed (Peter Gloviczki, 2009). Venous thromboembolic disease is common in the ICU patients and has been shown to lead to significant morbidity and mortality when undiagnosed (Kraaijenhagen RA, Piovella F, Bernardi E, et al, 2002) (Bernardi E, Camporese G, Buller HR, et al, 2008) (Stevens SM, Woller SC, Graves KK, et al, 2012). The DVT can pass to the lung and lead to pulmonary embolism (PE) which is a serious complication. e.g., depth, isolation, moisture and productivity (Gaston, 2000). Over the past two decades venous ultrasonography (US) has become the standard primary imaging technique for the initial evaluation of patients for whom there is clinical suspicion of deep venous thrombosis (DVT) of the lower extremity veins. It has replaced the venogram and other diagnostic studies such as impedance plethysmography, various radionuclide studies, and conventional CT because of its noninvasive nature,

the ease with which it can be performed in skilled hands, and its proven efficacy. Compression US first was described as a means of diagnosing DVT in 1986 by Raghavendra and colleague and was introduced into clinical practice in 1987 by Cronan and colleagues from the United States and Appleman and colleagues from the Netherland (Devin Dean et al, 2005). So, Doppler ultrasound now became an important imaging modality since it is safe and accurate to evaluate blood flow within the body and its use is steadily expanding. Peripheral vascular Doppler investigation of the carotid arteries and the deep veins of the legs are well established procedures (Abigail T, Timothy H, 2005).

Duplex scanning (Doppler and B mode) is considered to be the method of choice for the imaging of (DVT), with venography reserved for technically incomplete or difficult duplex examinations. Duplex scanning can be used for serial investigations to monitor the progression and outcome of thrombosis. In addition, duplex scanning can be useful for assessing the long-term damage to veins and valve function as a result of chronic post-thrombotic syndrome. This can lead to the development of lower limb venous hypertension and possible leg ulceration (www.bing.com/search?q=Diagnosis, 2014). However, there have been very few articles on the DVT in the lower extremities of patients in Sudan. The objectives of this study is to assess the DVT of the lower extremities using the color Doppler (CD), to measure the incidence of DVT and to describe the risks factors. In Khartoum State there were few data concerning sonographic evaluation of DVT of the lower extremities.

2. Material and Methods

There were 150 patients were clinically suspected to be involved of DVT at lower extremities, complaining of such symptoms but were not fully diagnosed, they had been selected for the study. The study population composed of 89 male and 61 female. They had been referred for ultrasound to confirm the diagnosis. The study was conducted in Military Hospital Omdurman, and Soba University Hospital from the period of January 2014 to July 2014. Patients who had already been diagnosed with DVT and under treatment had been excluded from the study. **2.1. The imaging procedure:**

Thrombi cannot reliably detected on B-mode image because they are often appear as hypoechoic as flowing blood. Therefore, all patients had been scanned with color Doppler ultrasound machine using high frequency linear transducer. The protocol begins with the patient in supine position from upper thigh till foot with longitudinal and transverse

scanning to examine the common iliac, external iliac, femoral, saphenous, popliteal and posterior and anterior tibial veins. Extent of thrombus was determined by locating the proximal end of thrombus and documenting it with longitudinal and transverse scans (Antoch G., Pieper M., Dietz A, et al, 2010).

2.2. The color Doppler imaging protocol:

2.2.1. Iliac vein:

The patient lie supine, with low frequency convex probe the external iliac vein is identified at the groin and is followed up by the transducer lateral to the rectus muscle. And the pressure applied by the transducer to better visualization of this region. It then divided into internal and an external iliac vein in the iliac fossa the confluence is not always identified.

2.2.2. Femoral segment:

The examination begins at groin region using high frequency 5MHz linear transducer. The patient is supine with hip slightly externally rotated. Visualize common femoral vein with longitudinal plane and differentiate between the vein and artery by the color Doppler. The Saphenous Femoral junction (SFJ) was evaluated by spectral analysis and to check for spontaneous, phasic flow, normal valsava response and augmentation with calf compression. Proceed distally along the femoral vein to junction of superficial and deep femoral vein. And then return to the common femoral vein (CFV) level and begin transverse examination with color Doppler.

2.2.3. Popliteal vein:

Patient lies prone with feet elevated by using a billow. The knee flexed slightly 10-15 degree to avoid collapse of the vein. Begin with longitudinal view of the superficial femoral vein the distal part of adductor canal continue distally till it bifurcates into peroneal and tibial veins at the inferior end of the popliteal fossa. Then they were imaged using transverse plane sections.

2.2.4. Calf vein

Patient supine or sitting with affected leg hanging over the side of the bed. The paired posterior tibial veins are identified posteriorly to the medial malleolus at the ankle superficially and on the either side of the posterior tibial artery. The three groups of paired calf veins are evaluated by using compression ultrasonography and augmentation with manual compression and color flow imaging of lower calf is useful to localize and evaluate the veins for flow.

3. Results:

All patients were investigated with color Doppler sonography and diagnosis of lower extremities DVT had been confirmed. The study population composed of males who represented 59.33% and females (40.67%) as shown in Figure 1.

Distribution of age was shown in Table (1). 8% were less than 29 years, 20.67% were 30-34 years, 25.33% were 35-39 years, 8.67% were 40-44 years, 12.67% were 45-49 years, while 24.66% their age equal to 50 or above.

Table (2) showed comparison of age group with gender. Regarding the age group <29 years (9 cases were males and 3 cases were females), the age group 30-34 years (18 of cases were males and 13 of cases were females), the age group 35-39 years (19 of cases were males and 19 of cases were females), the age group 40-44 years (9 of cases were males and 4 of cases were females), the age group 45-49 years (13 of cases were males and 6 of cases were females) and the age group ≥ 50 (21 of cases were males and 16 were females).

Most of the study population (61.33%) had an occupation, whereas (38.67%) had no jobs as demonstrated in Table (3).

Risk factor of DVT of patients under study was shown in Table (4) which revealed that 34% with history of surgery, 20.67% are trauma patients, 14.67% had known malignant disease, 12% were obese, 6% give a history of oral contraceptive usage, while 12.67% had other risk factors which include 3.2% with immobilization; 3.2% were pregnancy; 3.2% infected with HIV; 3.2% with PID; 1.33% varicaserier; '1, 0.67%' pelvic infection).

Table (5) showed frequency distribution according to symptoms of DVT. There were 96.00% presented with swelling, 94.67% came with pain, 54% had S.O.B, 20.67% with dizziness, 20% with fever, 4.67% had anxiety, 4% with vague symptoms; whereas 5.33% had others which include (2.67% cough; 2% asymptomatic; 0.67% vomiting).

Signs of DVT of investigated patients was illustrated in Table (6). There were 76% with redness, 76% had edema, 14% with tachycardia, 10% had positive Homan's sign, 9.33% had positive Moses, sign and 7.33% with tachypnea.

Table (7) showed frequency distribution according to location of thrombus. 30% of thrombi were located at left popliteal vein, 18% were found at left CVF, 15.33% at right popliteal, 14.67% were at right CVF, 10% were located at left femoral vein and 12% were located at other veins which include (2.67% Lt. calf vein; 2% Rt. femoral; 2% Rt. calf vein; 1.33% anterior tibial; 1.33% GVS + Lt. CFV; 1.33% Lt. posterior tibial vein; 1.33% Lt. popliteal vein & posterior tibial vein).

Table (8) showed different location of thrombi among males and females. Left popliteal vein (30 of cases were males and 15 of cases were females), left common femoral vein (13 of cases were males and 14 were females), right popliteal vein (13 of cases were males and 10 were females), right common femoral

vein (12 of cases were males and 10 of cases were females), left femoral vein (8 of cases were males and 7 were females) and other location include (anterior and posterior tibial veins and peroneal vein) (13 of cases were males and 5 were females).

The majority of patients under study (80%) had no degree of extension as shown in figure2.

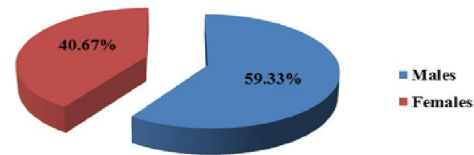


Figure (1) shows gender distribution of the study population

Table(1):Frequency distribution according Age

(years)	Frequency	Percent%
<29	12	8.00%
30-34	31	20.67%
35-39	38	25.33%
40-44	13	8.67%
45-49	19	12.67%
≥ 50	37	24.66%
Total	150	100%

Table (2): comparison of age group with gender

Age groups	Male	Female
<29	9	3
30-34	18	13
35-39	19	19
40-44	9	4
45-49	13	6
≥ 50	21	16

Table (3): Frequency distribution of DVT according to occupation

Occupation	Frequency	percent%
Have occupation	92	61.33%
No occupation	58	38.67%

Table (4): Frequency distribution of subjects according to risk factors of DVT

Risk factors	Frequency	percent%
Surgery	51	34.00%
Trauma	31	20.67%
Malignancies	22	14.67%
Obesity	18	12.00%
Oral contraceptive	9	6.00%
Others	19	12.67%
Total	150	100%

Table (5): Frequency distribution of study population according to symptoms of DVT.

Symptoms	Frequency	percent%
Swelling	144	96.00%
Pain	142	94.67%
S.O.B	81	54.00%
Dizziness	31	20.67%
Fever	30	20.00%
Anxiety	7	4.67%
Vague	6	4.00%
Others	8	5.33%

Table (6): Frequency distribution of subjects according to signs of DVT

Signs	Frequency	percent%
Redness	114	76.00%
Edema	105	70.00%
Tachycardia	21	14.00%
+ve Homans' sign	15	10.00%
+ve Moses' sign	14	9.33%
Tachypnea	11	7.33%

Table (7): Frequency distribution according to location of thrombus

Location	Frequency	percent%
Lt. popliteal vein	45	30.00%
Lt. CFV	27	18.00%
Rt. popliteal vein	23	15.33%
Rt. CFV	22	14.67%
Lt. femoral	15	10.00%
Others	18	12.00%
Total	150	100%

4. Discussion:

Color duplex sonography is a new technical development that provides a combination of gray scale and dynamic-color flow vascular images. In recent years, noninvasive sonographic technique (real time ultrasonography, duplex ultrasound (DU) and color coded duplex sonography) have increased in importance in the diagnosis of suspected lower extremity deep venous thrombosis.

In this study, it was observed that there was increased incidence of DVT among male patients more than females (59.33% vs. 40.67 %).

The prevalence of DVT among males and females was studied by Nordstrom et al, (2009) who reported that the incidence was found to be equal for both sexes, i.e. 1.6 per 1000 inhabitants and year. Risk factors were found to be in accordance with earlier studies. The increased incidence of DVT among Sudanese male's subjects may be attributed to the fact that; Sudanese male subjects are more prone to have trauma, infection and surgery than female subjects. On the other hand, Sudanese women were mostly housewives, less likely to have predisposing

causes of DVT other than pregnancy, oral contraceptive pills and pelvic pathology.

The present study showed that the peak incidence of DVT lies at the age groups between 3rd to 6th decades of life, at this age of human activity, there would be increased risk of trauma. This was agreeing with a study conducted by Nordstrom et al, (2009) who found that the median age for men was 66 years, compared to 72 years for women. This indicates that the peak incidence of DVT in males and females was seen during 5th -7th decade of life.

The study showed that the major risk factor is the prolonged immobilization which result from prolonged bed rest due to surgery (34%) or trauma (20.67%), this finding was similar to the findings of Lewis & his colleagues in their study (Lewis et al., 1994).

Our study revealed that most patients with DVT were initially developing symptoms of pain and swelling in the calf of one leg, representing (94.67%) and (96%) respectively.

The study confirmed that there was no cases of pulmonary embolism were recorded and this may be due to awareness of patients of the seriousness of the disease. In literature, Complications of DVT include potentially life-threatening pulmonary embolism (PE), (Heit JA, Cohen AT, Anderson FA, 2005) in addition to post-thrombotic syndrome (PTS) (Blann AD, Lip GYH, 2006)

The study showed that the major sign of DVT is redness (76%) followed by lower limb edema (76%), these results agree with the study conducted by Suzan, (1998) who reviewed the risk factors and reported that the use of oral contraceptive augments 4 folds the risk for DVT? Other risk factors include obesity, varicose veins, infection, inflammatory bowel diseases, nephrotic syndrome, polycythemia, paroxysmal nocturnal hemoglobinemia and Bahcet Disease. In other study, Symptoms such as leg pain, tenderness, edema or swelling are typically associated with DVT, but the condition may only be definitively diagnosed if validated objective diagnostic tests, such as compression ultrasonography, venography or magnetic resonance imaging (MRI) are performed (Heit JA, Cohen AT, Anderson FA, 2005).

Our study revealed that; the left popliteal vein is more commonly involved by DVT (45 of cases 30%) compared to the right popliteal vein (15.33%). This finding agree with a study conducted by Blaivas et al., (2000) who found that venous thrombosis are more common in left extremity. This is mostly related to the anatomical configuration of the left lower limb veins compared to the right lower limb.

Regarding the proximal extension of DVT, this study revealed that the majority of patients had no

any degree of proximal extension of thrombus (80%) and only 30 cases (20%) showed some degree of proximal extension. This can be explained by the fact that most patients of our study had an acute DVT and came earlier to hospital. The main location of proximal extension of thrombus is into CFV (66.67%) followed by extension into IVC (7cases, 23.33%), and in 3 cases (10%) the extension was found involving both the CFV and IVC.

Finally, as had been mentioned previously, all the study population had been investigated with color duplex sonography, thrombus was detected, and this indicates that Doppler ultrasound is very sensitive. Blaivas et al (2000) concluded that color duplex sonography has a sensitivity and specificity of 100% and 91% respectively in lower limb deep vein thrombosis.

5. Conclusion:

Color Doppler ultrasonography is the first line investigation to diagnose and assess DVT of the lower extremities. Doppler ultrasonography is essential in evaluation of suspected acute DVT and may be helpful in evaluation of suspected DVT in patients with previous or chronic DVT.

Corresponding Author:

Dr. Moawia Bushra Gameraddin
Department of Diagnostic Radiology
Faculty of Applied Medical Sciences, Taibah University
Al madinah, Saudi Arabia, tell: 00966534821130
E-mail: m.bushra@yahoo.com

References

1. Geerts WH, Bergqvist D, Pineo GF et al. (2008) Prevention of venous thromboembolism: American College of Chest Physicians evidence-based clinical practice guidelines (8th Edition). *Chest*; 133:381S–453S.
2. Cohen AT, Agnelli G, Anderson FA, et al. (2007) Venous thromboembolism (VTE) in Europe. The number of VTE events and associated morbidity and mortality. *Thromb Haemost*; 98:756–764.
3. Peter Glaviczki. The layman's hand book of venous disorder (2009) Guidelines of the American venous forum.3rd edition. Hodder Arnold; London: P10-18.
4. Kraaijenhagen RA, Piovela F, Bernardi E, et al. (2002) Simplification of the diagnostic management of suspected deep vein thrombosis. *Arch Intern Med*; 162: 907–11.
5. Bernardi E, Camporese G, Buller HR, et al. (2008) Serial 2-point ultrasonography plus D-dimer vs whole-leg color-coded Doppler ultrasonography for diagnosing suspected symptomatic deep vein thrombosis. a randomized controlled trial. *JAMA*; 300: 1–7.
6. Stevens SM, Woller SC, Graves KK, et al.(2012) Withholding anticoagulation following a single negative whole-leg ultrasound in patients at high pretest probability for deep vein thrombosis. *Clin Appl Thromb Hemost*; doi: 10.1177/1076029612445919.
7. Devin Dean. *Abdominal Ultrasound, module 4* (2005). The burwin Institute of Diagnostic Medical Ultrasound; Lunenburg, Canada: 14-25
8. Abigail thrush. Timothy Hartshorne. (2005) *peripheral vascular ultrasound: how why and when*.2nd edition. Elsevier; china ;172-175.
9. <http://www.bing.com/search?q=Diagnosis+for+Venous+Doppler&first=11&FORM=PERE> Accessed on June 5, 2014.
10. Antoch G., Pieper M., Dietz A, et al. (2010) *Teaching Manual of Color Doppler Duplex Sonography*. Germany Matthias Hofer; Thieme, 3rd edition. pp:83-84.
11. Nordstrom M, Linblad B., BergQvist, Kjellstrom T (2009). Aprospective study of the incidence of deep venous thrombosis within a defined urban population. 232(2): 155. Abstract.
12. Lewis BD, James EM, Welch TJ. et al (1994). Diagnosis of acute deep venous thrombosis of the lower extremities: Prospective evaluation of color Doppler flowing imaging versus venography, *Radiology*. 1994; 192(3): 651. Abstract.
13. Heit JA, Cohen AT, Anderson FA. (2005) on behalf of the VTE Impact Assessment Group. Estimated annual number of incident and recurrent, non-fatal and fatal venous thromboembolism (VTE) events in the US. *Blood (ASH Annual Meeting Abstracts)*; 106. Abstract 910.
14. Blann AD, Lip GYH. (2006).Venous thromboembolism. *BMJ*; 332:215–219.
15. Suzan R. (1989).The clinical diagnosis of DVT integrating incidence, risk factors and symptoms and signs. *Arch intern Med*.; 158(21):2319-2321.
16. Blaivas M., Michael J., Robert A. et al. (2000) Emergency lower- extremity Doppler. *Academic emergency Medicine*; 7(2): 121-125.