

Treatment with folic acid ameliorated the histological and immunohistochemical alterations caused by propylthiouracil –induced hypothyroid rat aorta

Wafaa Ibrahim¹; Maha Abo Gazia²; Afaf El-Atrash³; Ahmed Massoud³; Ehab Tousson^{3*}; and Heba Abou-Harga³

¹Department of Medical Biochemistry, Faculty of Medicine, Tanta University, Egypt

²Department of Histology, Faculty of Medicine, Al-Fayoum University, Egypt

³Department of Zoology, Faculty of Science, Tanta University, Egypt

Abstract: Thyroid status is an important determinant of cardiovascular function. We studied the changes in the aorta of hypothyroid rat at the post-pubertal stage, in addition to the ameliorating role of folic acid. Fifty male albino rats were equally divided into five groups; the first and second groups were the control and folic acid groups, respectively while the third group was the hypothyroid group in which rats received 6-n-propyl thiouracil (PTU) in drinking water for 6 weeks to induce hypothyroidism. The fourth and fifth groups were co – and post hypothyroid rats treated with folic acid for four weeks. Aorta in hypothyroid rats revealed normal histological structure except the layer of tunica media where compressed with elongated nuclei and less in thickens than that of the control groups. The eNOS label index was significantly decreased in hypothyroid rats and their levels were significantly increased in co- and post treated hypothyroid rats when compared with hypothyroid rats. The current study indicated that, folic acid as a treatment was better if it is administered as an adjuvant after returning to the euthyroid state. Treatment of hypothyroidism with folic acid improved the histopathological alternation and depresses the intensity of eNOS immunoreactive cells demonstrating the recovery of some injury.

[Wafaa Ibrahim; Maha Abo Gazia; Afaf El-Atrash; Ahmed Massoud; Ehab Tousson; and Heba Abou-Harga] **Ameliorative effect of folic acid on propylthiouracil-induced histological and immunohistochemical alterations in aorta of albino rats.** Journal of American Science 2012; 8(2):633-638].(ISSN: 1545-1003). <http://www.americanscience.org>. 88

Keywords: Hypothyroidism; PTU; aorta; eNOS; Immunohistochemistry

1. Introduction

In mammals, thyroid hormones have marked effects on the growth, development, and metabolic function of virtually all organs and tissues (Ahmed *et al.*, 2008; Toshihiro, 2010; Tousson *et al.*, 2011a, b). Thyroid status is also an important determinant of cardiovascular function (Luboshitzky and Herer, 2004; Toruner *et al.*, 2008). Hypothyroidism means that the thyroid gland can't make enough thyroid hormone to keep the body running normally (Adrees *et al.*, 2009). Thyroid hormone lowers systemic vascular resistance, increases blood volume, and has inotropic and chronotropic effects on cardiac function (Stănescu *et al.*, 2007; Neves *et al.*, 2008).

Thyroid hormones exert important effects on the cardiovascular system, including effects on cardiac systolic and diastolic function, peripheral vascular resistance, and arrhythmogenesis. It is well established that hypothyroidism induces a hypodynamic cardiovascular state (Fazio *et al.*, 2004). Hypothyroid patients have low output circulation state, decreased stroke volume, decreased vascular volume, and increased systemic vascular resistance (Jiskra *et al.*, 2007; Owen *et al.*, 2007). Previous studies showed that coronary artery atherosclerosis is twice as common in patients with hypothyroidism as in sex- and age-matched controls, and the atherosclerotic process is believed to be diminished in hyperthyroidism (Majors *et al.*, 1997; Guo *et al.*, 2009).

Folic acid is essential to numerous body functions ranging from nucleotide biosynthesis to the remethylation of homocysteine (Matte *et al.*, 2007; Bazzano, 2009). Children and adults both require folic acid in order to produce healthy red blood cells and prevent anemia. Folic acid can be used to help treat Alzheimer's disease, depression, anemia, and certain types of cancer (Zhu *et al.*, 2007). There is little information about the relation between hypothyroidism and the changes in aorta structure. So, the present study represents a contribution to declare the effect of low thyroid hormone status on the histopathological and eNOS immunoreactivity (eNOS-ir) changes in the aorta of hypothyroid rat at the post-pubertal stage, in addition to the ameliorating role of folic acid.

2. Material and Methods

The experiments were performed on fifty male albino rats (*Rattus norvegicus*) weighing 120±10g and of 6-7 week's age. They were obtained from our laboratory farms, Zoology Department, Faculty of Science, Tanta University, Egypt. The rats were kept in the laboratory for one week before the experimental work and maintained on a standard rodent diet (20% casein, 15% corn oil, 55% corn starch, 5% salt mixture and 5% vitaminized starch; Egyptian Company of Oils and Soap Kafr-Elzayat Egypt) and water available *ad libitum*. The temperature in the animal room was maintained at 23±2°C with a relative humidity of 55±5%. Light

was on a 12:12 hr light -dark cycle. The experimental protocol was approved by Local Ethics Committee and Animals Research.

The rats were randomly and equally divided into five groups (10 animals each). Group I: (G₁) Control group in which animals did not received any treatment. Group II: (G₂) Folic acid group in which animals received daily folic acid (El Nasr Pharmaceutical Chemicals Co.; at 0.011 $\mu\text{mol/g}$ of body weight) for four weeks from 2nd week to 6th week (**Matte et al., 2007**). Group III: (G₃) Hypothyroid rats group in which rats received daily 0.05% 6-n-propyl-2-thiouracil (PTU) in drinking water for 6 weeks (**Salvati et al., 1994**). Group IV: (G₄) Co-treated group in which animals daily received 0.05% PTU in drinking water and folic acid simultaneously according to **Matte et al. (2007)**. The dose period of PTU was six weeks as in hypothyroid rats group. However, folic acid was administered orally for 4 weeks starting with the 2nd to the 6th week after evidence that hypothyroidism had been established at the end of the second week. Group V: (G₅) Post treated group in which animals received daily 0.05% PTU in drinking water for 6 weeks as in hypothyroid rats group. Additionally, folic acid was administered for another 4 weeks (starting with the 7th week to the 10th week) while PTU was withdrawn after the sixth week to return to the euthyroid state.

At the end of the experimental period, rats were euthanized with intraperitoneal injection with sodium pentobarbital and subjected to a complete necropsy. Blood samples were individually collected from the inferior vena cava of each rat and serum was separated from non heparinized blood by centrifugation at 3000 rpm for 15 minutes. The collected serum used to determine both T₃ and TSH by using commercial test supplied by the Diagnostic systems Laboratories (DSL), Taxes, USA. and commercial Kit supplied by Coat-A- Count TSH IRMA, Los Angeles, USA.

The thorax was opened with surgical incision on the sternum and the perfusion was done from left ventricle and right atrium. A rinsing solution was perfused before the fixation solution (10% formalin). To make rinsing solution, 9.0g NaCl, 25g Polyvinyl Pyrrolidone, 0.25g Heparin, and 5.0g Procain-HCL were dissolved in one liter of water by thorough stirring. The pH was adjusted to 7.35 with 1 N NaOH and twice filtered through Millipore filters of 3.0 μm or less pore size. The perfusion of both solutions was performed by using a scalp vein attached to a 50cc syringe. Small pieces (1mm) of aorta were immediately removed taking care to handle specimens gently to minimize trauma to fixative solution. The fixed aorta were dehydrated through a graded series of ethanol and embedded in paraffin according to standard procedures. Paraffin sections (5 μm thick) were mounted on gelatin chromalum-coated glass slides and stored at room temperature until used for Haematoxylin and eosin

stains as a routine method after **Bancroft and Stevens (1990)**.

The distribution of eNOS in aorta section from different groups were examined in deparaffinized sections using an Avidin-Biotin-Peroxidase (ABC) immunohistochemical method (Elite-ABC, Vector Laboratories, CA, USA) against eNOS (dilution 1:400, DAKO Japan Co, Ltd, Tokyo, Japan) were employed. Briefly, sections were deparaffinized, rehydrated, washed in phosphate buffered saline (PBS) (3 x 5 min) and peroxidase activity was quenched using 0.3% H₂O₂ in methanol for 30 min. Subsequently, samples were washed in PBS and incubated with blocking solution at room temperature for 10 min. After rinsing with PBS, sections were incubated with biotinylated mouse anti- eNOS primary antibody in moist chamber for 30-60 min and then rinsed with PBS. Samples were incubated with Streptavidin Peroxidase at room temperature for 10 min and washed with PBS. The antibody-peroxidase complex was developed using DAB chromogen at 18-24°C for 2-5 min. Finally, the sections were washed with PBS, counterstained with methyl blue for 1 min, washed with tap water then dehydrated through ascending grades of alcohol, delipidated in xylene, and cover-slipped with Mount-Quick (Daido Sangyo, Tokyo). All stained slides were viewed by using Olympus microscope and images were captured by a digital camera (Cannon 620). Image analysis was adjusted using PAX-it image analysis software.

Statistical Analysis: Data were expressed as mean values \pm SE and statistical analysis was performed using one-way analysis of variance (ANOVA) to assess significant differences among treatment groups. The criterion for statistical significance was set at $p < 0.05$. All statistical analyses were performed using SPSS statistical version 16 software package (SPSS® Inc., USA).

3. Results:

In order to ensure the hypothyroid state we regularly determined the serum T₃ and TSH through the dose period. Table (1) showed that the serum T₃ levels in hypothyroid rats were significantly decreased compared with the control group. T₃ levels in treated hypothyroid rats with folic acid were significantly increased compared with the hypothyroid groups. Table (1) showed that the serum TSH levels were significantly increased in hypothyroid rats when compared with the control group. TSH levels in treated hypothyroid rats with folic acid were significantly decreased compared with the hypothyroid groups

Light microscopy of the aorta in control rat and folic acid group showed normal aortic wall structure (Figs.1-4). The aorta is the largest artery in the body, rising from the heart's major pumping chamber, the left ventricle. Oxygen-rich blood enters the aorta with each contraction of the left ventricle and travels throughout the body through the smaller arteries

branching from it. The walls of the aorta are made up of three different layers of tissue: a thin inner layer (intima); a thick, elastic middle layer (media); and a thin outer layer (adventitia). Tunica intima consisted of endothelial layer, subendothelial connective tissue and internal elastic lamina. Tunica media consisted of smooth muscle arranged in concentric layers. Thickens of tunica media in control and folic acid groups were $53.2\mu\text{m} \pm 0.55$ and $48.7\mu\text{m} \pm 0.45$ respectively. Tunica adventitia consisted of loose connective tissue surrounded by subepicardial adipose tissue. Aorta in hypothyroid rats revealed normal structure except the tunica media where compressed with elongated nuclei and about $27.4 \mu\text{m} \pm 0.68$ in thickens (Figs. 5, 6). Treating hypothyroid rats with folic acid showed compressed tunica media that is about $38.8 \mu\text{m} \pm 0.49$ in thickens while the thickens were $52.6 \mu\text{m} \pm 0.51$ in the aortic sections in post treatment hypothyroid rat with folic acid (Figs. 7-10).

The detection and distribution of eNOS immunoreactivity (eNOS-ir) in aorta in the different groups under study were revealed in figures 11-18. Only intima layer in aorta showed positive reaction for eNOS-ir (grade 4) in both control and folic acid groups (Figs. 11-13) while the media and adventitia layers were showed negative reaction for eNOS-ir. The intensity of eNOS -ir were decreased in the intima layer in aorta of hypothyroid rat group (Figs. 14, 15) when compared with control group. The intensity of eNOS -ir was gradually increased in the intima layer in aorta of co-treated (grade 1) and post treated (grade 2) hypothyroid rat with folic acid (Figs. 16-18) when compared with hypothyroid rat group. Table (2) showed the correlation between eNOS and other parameters under study.

4. Discussion

This study showed the structural status of the aorta during the hypothyroidism in post-pubertal rats. In contrast to most studies in this field, this study induced the hypothyroid condition during puberty and not immediately after birth. In order to achieve this target we made a deficient state of thyroid hormones by a reversible goitrogen that

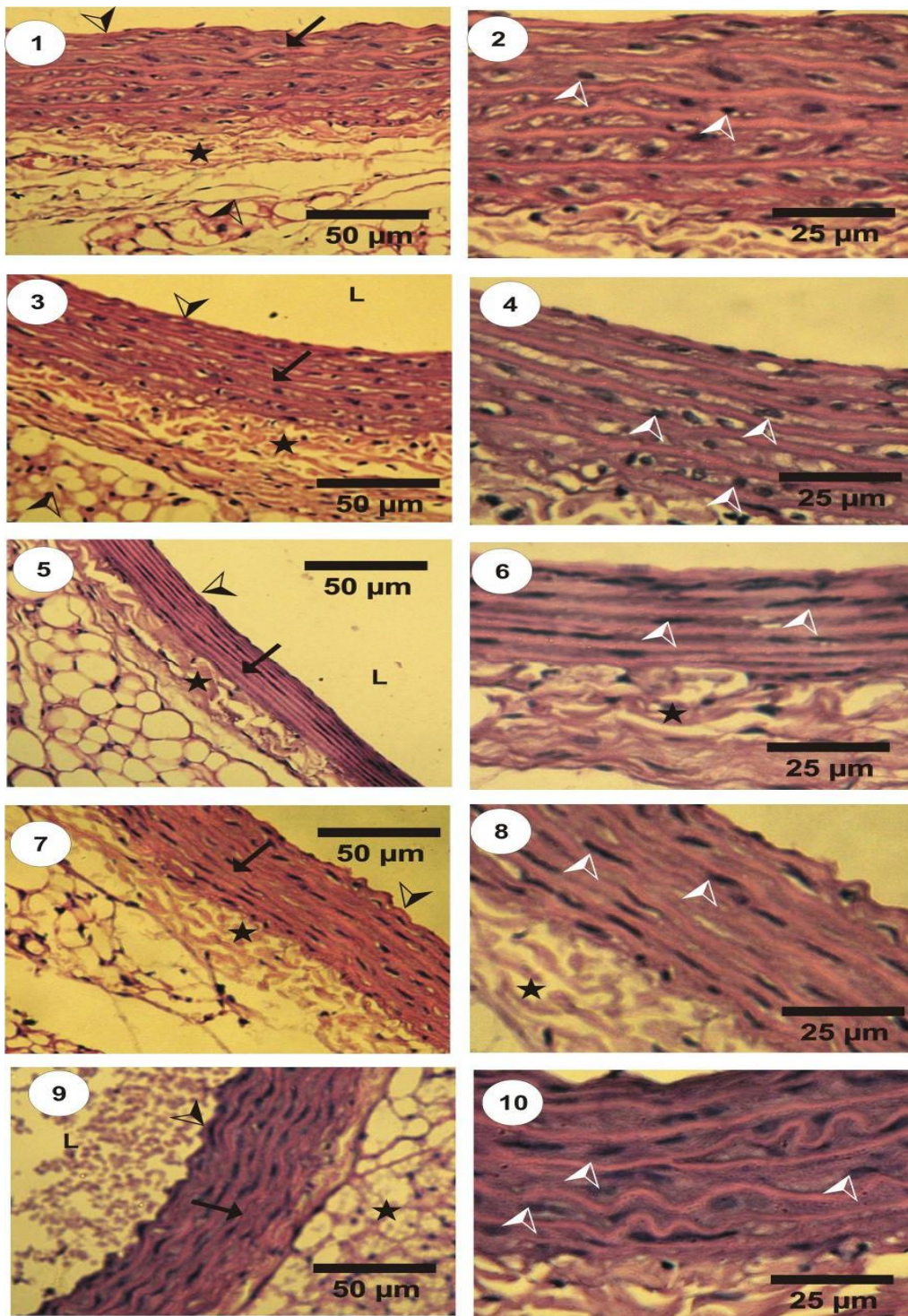
known to decrease the conversion of peripheral Thyroxine (T_4) to T_3 and thereby reduce serum T_3 concentration and it was administered to the rats in the drinking water within a period of six weeks (**Gilbert and Paczkowski, 2003**). In order to ensure the hypothyroid state we regularly determined the serum T_3 and TSH through the dose period where serum T_3 concentration is depressed and serum TSH concentration is significantly elevated in rats receiving PTU-induced hypothyroidism. This increase in TSH can be explained by decreased production of T_3 from the thyroid gland that minimizes TSH feedback inhibition resulting in an increase in its secretion by the anterior pituitary gland; this result coincides with studies of **Shibutani et al. (2009)**. In the present study, the effect of PTU on T_3 and TSH seems to be reversed in adult rats when the treatment was withdrawn after 4 weeks as the levels of the T_3 and TSH tend to be nearing normal levels.

Thyroid hormones exert important effects on the cardiovascular system, including effects on cardiac systolic and diastolic function, peripheral vascular resistance, and arrhythmogenesis. Thyroid hormones have marked effects on the growth, development, and metabolic function of virtually all organs and tissues (**Jiskra et al., 2007; Toshihiro, 2010**). The present histopathological results showed that, the aorta in hypothyroid rats revealed normal histological structure except the layer of tunica media where compressed with elongated nuclei and less in thickens than that of the control groups. Also, treating hypothyroid rats with folic acid during PTU receiving showed less increased in tunica media thickens while the thickens were more increased in post treatment hypothyroid rat with folic acid. Our results agreed with **Neves et al. (2008)** who reported that the thyroid hormones play an important role in the regulation of blood pressure. Atrial arrhythmias, limitations in exercise tolerance and congestive heart failure are reported to occur as a result of hyperthyroidism.

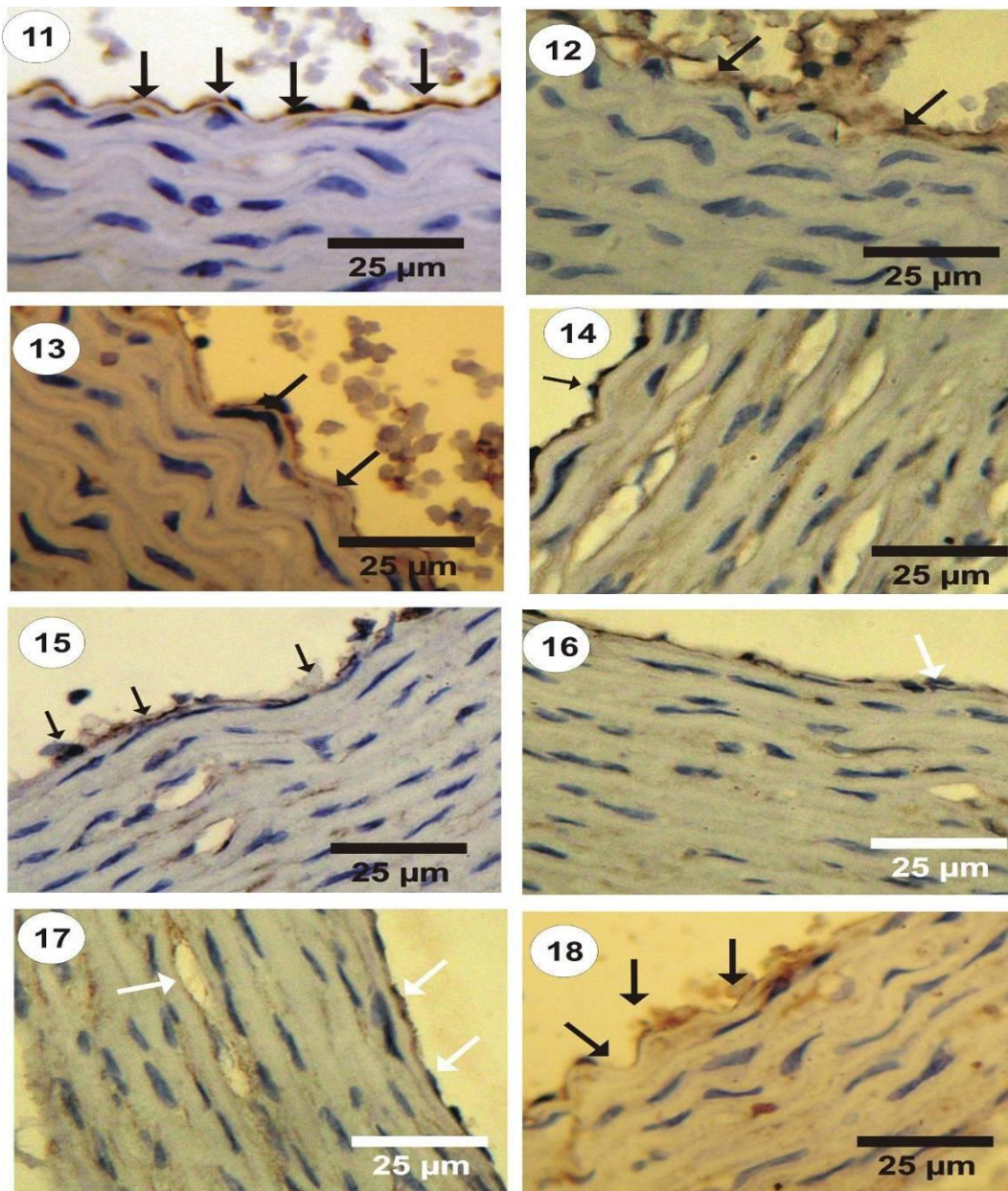
Table 1: Changes in the concentration of T_3 (ng/dl) and TSH ($\mu\text{IU/ml}$) levels in the plasma of different groups under study.

	G1	G2	G3	G4	G5
T_3	147 ± 22.37^a	148 ± 23.52^a	57.7 ± 6.89^b	40 ± 6.89^b	142.7 ± 22.11^a
TSH	0.02 ± 0.03^a	0.15 ± 0.124^a	3.90 ± 0.513^b	5.37 ± 0.462^c	0.06 ± 0.026^a

Data are expressed as mean \pm SE of five observations. ^{a, b, c and d}. Means in the same raw with different superscript are significantly different ($P \leq 0.05$). where G₁, Control group; G₂, Folic acid group; G₃, Hypothyroid rats group; G₄, Co-treatment group; G₅, Post treatment group.



Figures 1-10: Photomicrographs of the rat aorta stained by HE. The walls of the aorta are made up of three different layers of tissue: tunica intima (black arrowheads); tunica media (arrows) and tunica adventitia (stars). **1:** Normal structure in aorta in control group. **2:** A thick and elastic middle layer (tunica media) in aorta (arrows) in control group. **3&4:** normal aortic wall structure in folic acid group. **5&6:** Severe compressed tunica media with elongated nuclei in the aorta in hypothyroid rats. **7&8:** Mild compressed tunica media with elongated nuclei (arrow heads) in the aorta in co-treating hypothyroid rats with folic acid. **9&10:** A few compressed tunica media with normal nuclei in the aorta in post treatment hypothyroid rat with folic acid. L, lumen;



Figures 11-18: Photomicrographs of the rat aorta showed the detection and distribution of eNOS immunoreactivity (eNOS-ir) in the different groups under study. **11-13:** Intima layer (arrows) in aorta showed positive reaction for eNOS-ir (grade 4) in both control and folic acid groups. **14&15:** Decreased (grade 0) in the intensity of eNOS-ir in the intima layer in the aorta of hypothyroid rat group. **16&17:** Few increased in the intensity of eNOS-ir in the intima layer in aorta of co-treated (grade 1) hypothyroid rat with folic acid. **18:** Mild increased in the intensity of eNOS -ir in the intima layer in aorta of post treated (grade 2) hypothyroid rat with folic acid.

Folic acid can ameliorate vascular disease through varied mechanisms. Folic acid exerts an important role over homocysteine catabolism, by methyl group donation in remethylation pathway to methionine (Brosnan *et al.*, 2004).

Our immunohistochemical results supported the biochemical and histopathological results. In the present study, the intensity of eNOS-ir was decreased in the intima layer in aorta of

hypothyroid rat group when compared with control group. Also, the intensity of eNOS-ir was gradually increased in the intima layer in aorta of co-treated (grade 1) and post treated (grade 2) hypothyroid rat with folic acid when compared with hypothyroid rat group. Also, the present results revealed that, folic acid treatment was better if it is administered as an adjuvant after returning to the euthyroid state by withdrawing PTU from

the drinking water. If confirmed in human beings, our results could propose that the supplementation of folic acid can be used as an adjuvant therapy in hypothyroidism disorders.

Corresponding author

Ehab Tousson³

Department of Zoology, Faculty of Science, Tanta University, Egypt

toussonehab@yahoo.com

References

- Adrees M, Gibney J, El-Saeity N, Boran G. (2009). Effects of 18 months of L-T4 replacement in women with subclinical hypothyroidism. *Clin Endocrinol (Oxf)*, 71: 298-303.
- Ahmed OM, El-Gareib AW, El-bakry AM, El-Tawab SA, Ahmed RG (2008). Thyroid hormones states and brain development interactions. *Intern J Develop Neuroscience*, 26: 147-209.
- Bancroft JD, Stevens A. (1990). Theory and Practice of Histological Technique. 3rd Ed. Churchill Livingstone. Edinburgh, London.
- Bazzano LA (2009). Folic acid supplementation and cardiovascular disease: the state of the art. *The American Journal of the Medical Sciences*, 338 (1): 48-9.
- Brosnan JT, Jacobs RL, Stead LM, Brosnan ME (2004). Methylation demand: a key determinant of homocysteine metabolism. *Acta Biochim*, 51: 405-413.
- Fazio S, Palmieri EA, Lombardi G, Biondi B. (2004). Effects of thyroid hormone on the cardiovascular system. *Recent Prog Horm Res*, 59: 31-50.
- Gilbert ME, Paczkowski C (2003) Propylthiouracil (PTU)-induced hypothyroidism in the developing rat impairs synaptic transmission and plasticity in the dentate gyrus of the adult hippocampus. *Dev Brain Res*, 145: 19-29.
- Guo H, Chi J, Xing Y, Wang P (2009). Influence of folic acid on plasma homocysteine levels & arterial endothelial function in patients with unstable angina. *Indian J Med Res*, 129 (3): 279-284.
- Jiskra J, Limanová Z, Antosová M (2007). Thyroid diseases, dyslipidemia and cardiovascular risk. *Czech Vnitr Lek*, 53: 382- 385
- Luboshitzky, R, Herer, P. (2004). Cardiovascular risk factors in middle-aged women with subclinical hypothyroidism. *Neuro Endocrinol Lett*, 25(4): 262-266.
- Majors A, Ehrhart LA, Pezacka EH (1997). Homocysteine as a risk factor for vascular disease. Enhanced collagen production and accumulation by smooth muscle cells. *Arterioscler Thromb Vasc Biol*, 17: 2074-2081.
- Matte C, Scherer EB, Stefanello FM, Barschak AG, Vargas CR, Netto CA, Wyse AT (2007). Concurrent folate treatment prevents Na⁺,K⁺-ATPase activity inhibition and memory impairments caused by chronic hyperhomocysteinemia during rat development. *Int J Dev Neurosci*, 25: 545-552
- Neves, C, Alves, M, Medina, JL, Delgado, JL. (2008). Thyroid diseases, dyslipidemia and cardiovascular pathology. *Rev Port Cardiol*, 27(10): 1211-1236.
- Owen PJ, Sabit R, Lazarus JH (2007). Thyroid disease and vascular function. *Thyroid*, 17(6): 519-524.
- Salvati S, Attorri L, Campeggi LM (1994). Effect of propylthiouracil induced hypothyroidism on cerebral cortex of young and aged rats: lipid composition of synaptosomes, muscarinic receptor sites, and acetylcholinesterase activity. *Neurochem Res*, 19:1181-1186.
- Shibutani M, Woo GH, Fujimoto H, Saegusa Y, Takahashi M, Inoue K, Hirose M, Nishikawa A (2009). Assessment of developmental effects of hypothyroidism in rats from in utero and lactation exposure to anti-thyroid agents. *Reprod Toxicol*, 28: 297-307.
- Stănescu C, Branidou K, Ranetti EA (2007). Heart failure and dilated cardiomyopathy associated with severe longstanding untreated hypothyroidism. *Rom J Intern Med*, 45(1): 77-83.
- Toruner F, Altinova AE, Karakoc A, Yetkin I, Ayvaz G, Cakir N, Arslan M (2008). Risk factors for cardiovascular disease in patients with subclinical hypothyroidism. *Adv Ther*, 25(5): 430-437.
- Toshihiro I (2010). Thyroid hormone and atherosclerosis. *Vascul Pharmacol*, 52:151-156.
- Tousson E, Ali EM, Ibrahim W, Mansour M.A. (2011a). Proliferating Cell Nuclear Antigen as a Molecular Biomarker for Spermatogenesis in PTU-Induced Hypothyroidism of Rats. *Reprod Sci*, 18(7): 679-686
- Tousson E, Ibrahim W, Arafá N, Akela M (2011b). Monoamine concentrations changes in the PTU induced hypothyroid rat brain and the ameliorating role of folic acid. *Hum Exp Toxicol*. Doi: 10.1177/0960327111405863.
- Zhu X, Smith MA, Honda K, Aliev G, Moreira PI, Nunomura, A, Casadesus G, Harris PL, Siedlak SL, Perry G (2007). Vascular oxidative stress in Alzheimer disease. *J Neurol Sci*, 257: 240-246.

2/12/2012