

Reconstructive Cervical Laminoplasty with the Preserved Fixed Spinous Processes Row as an Intervening Bone Graft; a Successful Novel Surgical Approach.

Abulazaym A.A.^{*1} and Meziad M.²

¹Neurosurgery Department, Faculty of Medicine, Cairo University, Cairo, Egypt

²Orthopedic Department, Faculty of Medicine, Ain Shams University, Cairo, Egypt

abaaaza51@yahoo.com*

Abstract: Study design: A prospective study to evaluate the outcome of a novel operation for cervical myelopathy secondary to cervical canal stenosis; the Reconstructive Cervical Laminoplasty with the preserved fixed spinous processes row as an intervening bone graft. **Objective:** To explore a more effective, less invasive and more physiological operative technique for cervical myelopathy of cervical spinal canal stenosis. **Background:** The popular two cervical laminoplasties for the nowadays becoming common in elderly people cervical myelopathy of cervical spinal canal stenosis, i.e. open door laminoplasty and double doors laminoplasty are plagued with many drawbacks such as around 50% diminution in the range of cervical movements, 25% occurrence of kyphotic deformity, laminar fusions, from 10% to 50% chronic axial neck pain and nuchal musculature atrophy. A more physiological modification of this very beneficial operation is badly needed. We presented our novel reconstructive cervical laminoplasty with the preserved fixed spinous processes row as an intervening bone graft to avoid such drawbacks. **Methods:** This prospective preliminary study included 14 patients who underwent the novel reconstructive cervical laminoplasty with the preserved fixed spinous processes row as an intervening bone graft operation for their cervical myelopathy. **Results:** The novel operation is proved to be easier, more physiological and succeeded to avoid to a great extent the aforementioned drawbacks of the two popular cervical laminoplasties; only about 30% diminution of cervical movements occurred, no kyphotic deformities, post-operative axial neck pain was moderate and occurred in only 21% of the patients and the post operative nuchal musculature atrophy was avoided. **Conclusion:** Cervical myelopathy secondary to cervical spinal canal stenosis can be managed adequately with our novel cervical reconstructive myelopathy with the preserved fixed spinous processes row as an intervening bone graft. This technique obtained satisfactory outcomes and avoided the drawbacks of the popular laminoplasty operations. It can be a standard procedure for the surgical treatment of this nowadays becoming common disease. [Abulazaym A.A. and Meziad M. **Reconstructive Cervical Laminoplasty with the Preserved Fixed Spinous Processes Row as an Intervening Bone Graft; a Successful Novel Surgical Approach.** Journal of American Science 2010;6(12):1175-1180]. (ISSN: 1545-1003). <http://www.americanscience.org>.

Keywords: Reconstructive Cervical Laminoplasty; Spinous; Processes Row; Intervening Bone Graft; Novel Surgical Approach

1. Introduction

Cervical laminoplasty is a posterior spinal operation where the position of the laminae is altered to augment the cervical spinal canal width and volume without intersegmental fusion. Laminoplasty is primarily used to treat cervical myelopathy caused by cervical spinal stenosis. Spinal multisegmental stenosis of the cervical vertebrae is common in old age secondary to moderate to severe cervical spondylosis with osteophytic bars. Laminoplasty was first described in 1968, and much of the literature regarding it comes from Asia, where cervical myelopathy from ossification of the posterior longitudinal ligament is common. In our area as well as universally, many surgeons choose and prefer laminoplasty over anterior fusion techniques when more than two levels require decompression. Laminoplasty can be used in other situations where the volume of the cervical spinal canal needs augmentation, but fusion is not desired.

2. Methodology:

Study design: A prospective (longitudinal) preliminary study on the novel cervical laminoplasty with preservation of the fixed posterior longitudinal band operation.

Inclusion criteria: Presence of cervical myelopathy with cervical spinal canal stenosis, documented tight cervical spinal canal and cervical spinal cord compression with absence of the subarchnoid space in the MRI, Pavlov ratio (canal depth / vertebral depth) = < 0.82 in the lateral view plain X ray.

Exclusion criteria: Cervical Kyphosis.

Anterior osteophytic bars thickness > 7mm

Advanced myelopathy with marked spastic paraplegia or scissoring of the lower limbs and marked atrophy and weakness and of the upper limbs (grades 0, I).

Elderly debilitated patients.

Initial evaluation: 14 patients were included in this preliminary study they were submitted to complete neurological history taking and thorough examination. Radiological assessment: cervical MRI and plain cervical antero-posterior lateral and dynamic views were done to all the patients.

Physiological studies: Electromyogram EMG of the upper limbs is done to all patients.

Operative maneuver:

Patient positioning: A general endotracheal anesthesia is used and the patient is given a preoperative dose of antibiotics and steroids. Positioning is accomplished by placing a pin-type head rest, and turning the patient prone. Chest rolls elevate the thoracic cage and decompress the abdomen, thereby lowering the venous pressure and diminishing the operative blood loss. The head and neck are positioned in a neutral position, and the head rest mechanism is locked. The shoulders are taped down to the table with 4 inch adhesive tape. We prefer and found beneficial to elevate the head by tilting the surgical table 35 degree. A standard midline approach is utilized, dissecting down to the fascia then via the cutting diathermy in the ligamentum nuckae. The secret of success in this step and the following one is to keep the diathermy cutting strictly midline and restricted to the thick fibrous tissue of the ligamentum nuckae to minimize blood loss and to approach the spinous processes row atraumatically and easily. A standard bilateral subperiosteal dissection is carried out including the levels immediately superior and inferior to the pathologic levels, with preservation of the midline posterior tension band consisted from the spinous processes row and the intervening interspinous ligaments via restricting the diathermy cutting dissection only bilateral to the spinous processes, i.e. neither cutting in the upper nor the lower borders of the spinous processes. Using a small drill or a thread wire saw we cut at the bases of the spinous processes leaving 6-mm projections from the laminae; the scissors are used alternatingly to cut at the bases of the interspinous ligaments. The separated spinous processes, with their ligamentous attachments, are retracted to one side. The spinous processes are making the bony components of the preserved midline posterior tension band that is left as a whole fixed upwards and downwards to the spinous processes immediately superior and inferior to the pathologic levels. The laminae (devoid from the

spinous processes) are thereafter cut in the midline with the same instrument. Two bony hinges are constructed bilaterally at the junction of the laminae to the facet complexes using a high-speed drill down to thinning partially and suitably the inner cortex, taking strict care not to injure the facets. Care must be taken so that the lamina is not thinned to the point that it fractures, or that it offers no spring like resistance to deformation. The proper resistance is checked and made so that with gentle finger pressure the laminoplasty segment is opened. A gentle capacious and sufficient release and separation of the dura surrounded by its thin vascular film from the undersurface of each lamina is done, with gradual and gentle rotation of the lamina to open the segment. Then the ligamentum flavum in the mid line is opened and excised for about half a centimeter, with utmost care to avoid laceration of the epidural thin vascular film or the epidural venous plexus. Sufficient time is awaited for the dura to re-expand and regain its healthy pulsations. Now after securing hemostasis, the (to the side) retracted tension band is regained to the mid line and the spinous processes portions are used as an intervening bone grafts via drilling 1-mm holes in the medial edges of the hemilaminae and the sides of the corresponding properly opposed spinous process at each level. The spinous processes are sutured carefully into place using nonabsorbable sutures. These sutured spinous processes portions are actually the left portions after they had been cut leaving 6 mm of their bases projecting from the laminae. This induces about 4-5 mm enlargement along the anterior posterior line of the canal which was found ideal. A proper closure of the hemilaminae segments with the intervening spinous processes' portions included within the posterior tension band after expanding the spinal canal should be secured. If radiculopathy is found on the preoperative electromyogram (EMG), we always perform selective foraminotomy for the affected roots. We also always intentionally perform reconstruction of the semispinalis cervicis and re-suture it back to the C2 spinous process in both sides to strengthen the posterior tension band as well as to cover and secure water-tightness of the spinous processes-to-the medial hemilaminar edges sutures. After proper hemostasis of the back muscles, we close in layers. A rigid cervical collar is used for three weeks.

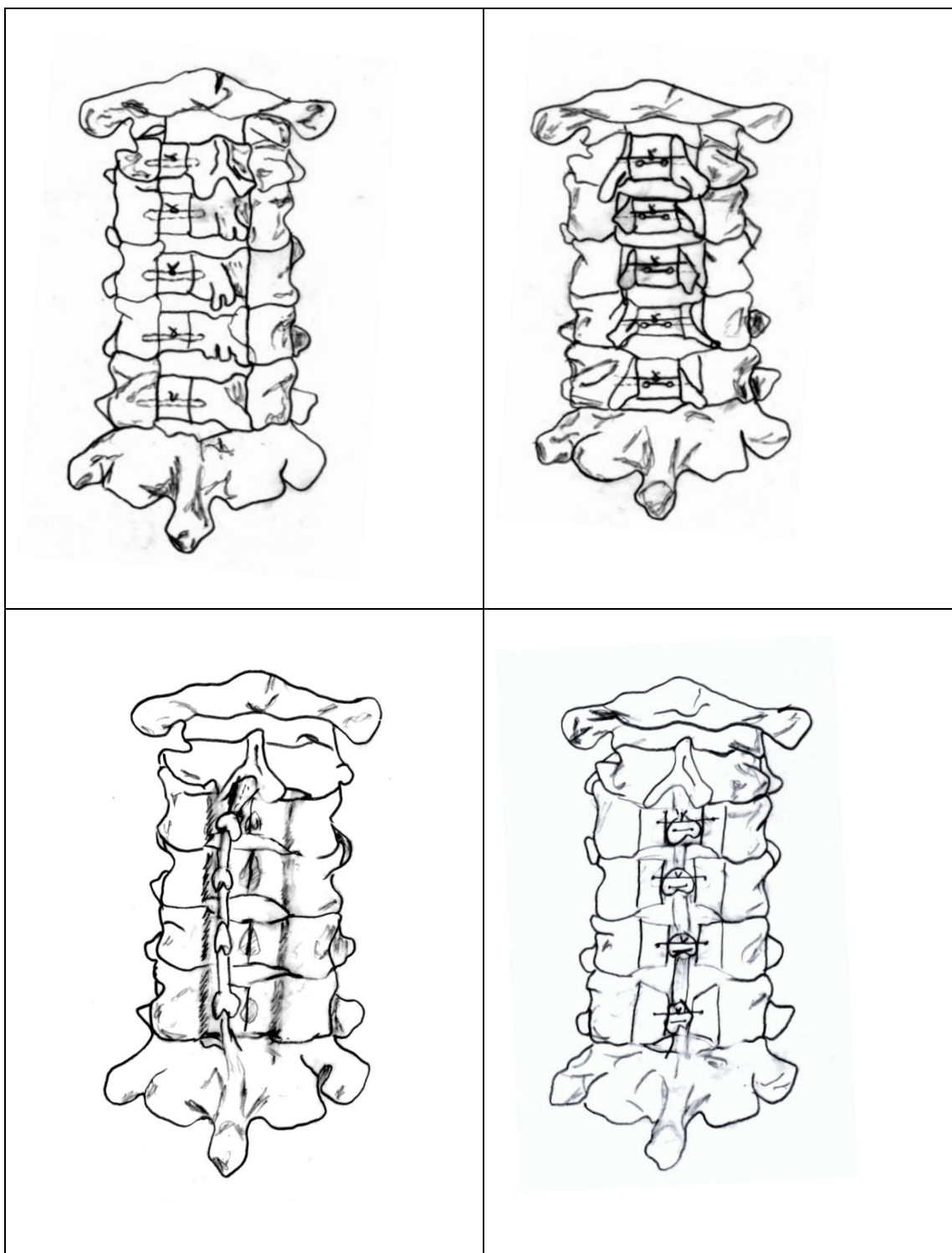


Fig. 1 Upper left: open-door laminoplasty. **Upper right:** double-door laminoplasty. **Lower left:** reconstructive laminoplasty with preservation of the fixed (to the superior and inferior spinous processes) midline longitudinal band; that is retracted to the side to permit the midline cuts in the laminae. **Lower right:** reconstructive laminoplasty with preservation of the posterior longitudinal band, after suturing of the spinous processes row in place.

3. Results:

Because most of the cervical laminoplasty operations are performed to treat myelopathy, the preoperative and post operative conditions are usually scored using the Japanese Orthopedic Association (JOA) scoring system for cervical myelopathy that gained universal acknowledgement and approval as much of the literature regarding laminoplasty comes from Asia where OPLL is prevailing. However some items in that score is strange to other communities (handling chopsticks), thus we used the same score with minimal modification that will not make any difference to suit our community. In this score:

The recovery rate percentage = $100 \times (\text{post operative score} - \text{preoperative score}) / (17 - \text{preoperative score})$.

Excellent recovery rate :>75%, Good:50-75%, Fair:25-50% and Poor recovery:<25%.

Ages of the patients ranged from 38 years up to 71 years. Average age was 49 years. 71% were males, the rest were females 39%.

Duration of the disease averaged 8 years (from 3 to 14 years).

To assess the success of our novel operation of laminoplasty we assessed the 14 patients as a group. Collectively, we found that there is a 72% recovery rate in JOA scoring system in our 14 patients as the following table 1.

Table 1: The collective recovery rate of our 14 patients.

	Pre-operative	Post-operative	Recovery rate
Motor dysfunction of the upper extremity 0=unable to feed oneself, 1=able to eat with spoon, 2= able to the full use of the teeth sticks with slight difficulty, 3=none	21	26	
Motor dysfunction of the lower extremity 0=unable to walk, 1=walking on flat floor with walking aid, 2= up stairs with hand rail, 3=None	24.5	29	
Sensory deficit of the upper extremity 0=severe sensory loss or pain, 1=mild sensory loss,2=none	12	16	
Sensory deficit of the lower extremity 0=severe sensory loss or pain, 1=mild sensory loss,2=none	11	16	
Trunk 0=severe sensory loss or pain, 1=mild sensory loss,2=none	10.5	17	
Sphincteric dysfunction 0=unable to void, 1=marked difficulty in micturition, 2=difficulty in micturition, 3=none			
	28	31	
Total	107	125	72%

However, four factors were found related to the outcome in an ascending relevance: older age, lower JOA scores, lower Pavlov ratio (width of the canal divided by the width of the vertebral C6 body in the lateral plain X ray), and the presence of an abnormal spinal canal signal in the preoperative MRI. They were found significantly related to poorer outcome. In this preliminary study we correlated the three patients mostly affected with the previous 4 factors in relation to the rest of the patients. We found that respectively each of them correlated to 16%, 20%, 26%, and 33% diminution in the overall good result.

4. Discussion:

Two types of laminoplasty gained popularity; the open door and the double door laminoplasty. All literature on laminoplasty is class 3 data, therefore, at present; laminoplasty is listed as a treatment option for cervical spondylotic myelopathy as well as ossified posterior longitudinal ligament (OPLL) in Japan and East Asia. It is heavily documented in the literature that laminoplasty is effective in treating cervical myelopathy caused by stenosis. Theoretically, laminoplasty benefits compared to anterior fusion include preservation of cervical motion and prevention of the adjacent motion segments degeneration. Its benefits compared to the decompression laminectomy include prevention of post laminectomy kyphosis, avoiding the development

of post laminectomy membrane formation and the recurrence of stenosis as well as avoidance of the development of retrolisthesis and instability. However, unfortunately, these benefits are not always realized as there are three drawbacks that plagued this beneficial maneuver in its popular two types. It was shown by previous researchers that the range of movement diminishes approximately 50% after laminoplasty, kyphotic deformity occurs in around 25% of the patients, and intralaminar membrane formation as well as laminar fusions has been recorded frequently. Additionally there is from 10% to 60% incidence of chronic axial neck pain compared to 19% after anterior fusion.

We present our easy and straightforward novel surgical maneuver that neither necessitates any extra manipulations for bringing bone grafts from elsewhere nor is technically demanding; in addition to its benefits in avoiding to a great extent the aforementioned complications. We found that preservation of the posterior tension band that is left fixed to the spinous processes immediately superior and inferior to the pathologic motion segments prevents the tendency to kyphous deformity. This band is strengthened via the resuture of the semispinalis cervicis back to the C2 spinous process. It should be mentioned that reconstruction of this muscle alone as was done before by some researchers without the preservation of the midline structures that constitute the posterior tension band will never suffice to prevent the kyphotic tendency as the muscle tissue is a stretchable tissue.

This preservation of the normal lordotic curve was found also very beneficial to prevent the chronic axial neck pain that was repeatedly recorded by many researchers to occur in up to 60% of post-laminoplasty patients. We think that this pain arises to a great extent from the posterior uncovertebral joints either because of their injury during surgery or due to post operative abnormal stretching of their capsules secondary to the post operative kyphotic tendency. We succeeded to prevent both factors, thus the post laminoplasty axial pain was reduced to minimum as only 21% of the patients complained of it.

We also succeeded to avoid the interrelated triad of post-operative diminution of the range of movement only about 30% in our maneuver compared to 50% in the two popular maneuvers, laminar fusions and perilaminar membrane formation via minimizing the surgical tissue injury and strict hemostasis. From the start we keep strictly our sharp mid line cutting within the fibrous tissues of the ligamentum nuchae, we preserve the midline structures that are crucial in the biodynamichs of the cervical vertebrae as it prevents the occurrence of postoperative kyphosis which continuously stretches and stimulates the

laminar periosteum to form new bone, also we keep the posterior joints untouched.

The latter three factors are also fundamental in preventing the post laminoplasty nuchal musculature atrophy and size reduction that was repeatedly recorded. The nuchal muscles may lose up to 25% of their preoperative size in some patients of the classical two types of laminoplasty. Avoiding this complication in our novel operation is largely due to the preservation of the midline tension band that prevents kyphosis which stretches the nuchal muscles and invite shearing tissue injury in them also may provide nutrient vasculature to the muscles in the post-operative period as well as keeping the posterior joints untouched preserve the nutrient vasculature and nerves of these muscles.

Strict hemostasis, post operative drain for 36 hours and post operative alpha chemotrypsin one amp/12 hours were also done and found very beneficial.

Limitations:

Our preliminary results are very encouraging. The novel operative maneuver is logic and straightforward. It is considered a conservative modification of the already popular and the established successful two types of cervical laminoplasty. In addition to preserving the proved very crucial posterior longitudinal tension band that is kept fixed superiorly and inferiorly; an employment of its bony element that is also kept fixed in it i.e. the spinous processes row as an intervening bone graft is easy and novel. Thus the time of the operation is greatly shortened, which is considered a welcomed element in this elderly age group. However, the limited number of our patients is considered a limitation that necessitates further studies on a greater scale.

5. Conclusion:

We presented our novel operation of reconstructive cervical laminoplasty that exploited the preserved fixed spinous processes row as an intervening bone graft. To our knowledge it is a pioneering and also a logic operation that conserves the crucially relevant posterior midline tension band fixed superiorly and inferiorly. We managed to avoid much of the drawbacks and complications of the popular two types of cervical laminoplasty, and thus our easy operative maneuver proved to be very beneficial.

Correspondence author

Abulazaym A.A.

Neurosurgery Department, Faculty of Medicine, Cairo University, Cairo, Egypt.

abaaaza51@yahoo.com

6. References:

1. Chung SS, lee CS, chung KH: factors affecting the surgical results of expansive laminoplasty for cervical spondylotic myelopathy. *Int Orthop* 26:334, 2002.
2. Edwards CC, Heller JG, Murakami H: Corpectomy versus laminoplasty for multilevel cervical myelopathy. *Spine* 27:1168-1175, 2002.
3. Fujimura Y, Nishi Y: Atrophy of the nuchal muscle and change in cervical curvature after expensive open-door laminoplasty. *Arch Orthop Trauma Surg* 115:203-205,1996.
4. Hirabayashi K: Expansive open-door laminoplasty for cervical spondylotic myelopathy. *Shujutsu* 32:1159-1163, 1978.
5. Hoshi K, Kurokawa T, Nakamura K, et al: Expansive cervical laminoplasties- Observations on comparative changes n spinous process lengths following longitudinal lamina divisions using autogenous bone or hydroxyapatite spacers. *Spinal Cord* 34:725-728, 1996.
6. Iseda T, Goya T, Nakano S, et al: Serial changes in signal intensities of the adjacent discs on T2-weighted sagittal images after surgical treatment of cervical spondylosis: Anterior interbody fusion versus expansive laminoplasty. *Acta Neurochir (Wien)* 143:710, 2001.
7. Kimura S, Homma T, Uchiyama S, et al: Posterior migration of cervical spinal cord between split lamina as a complication of laminoplasty. *Spine* 20:1284-1288, 1995.
8. Lee TT, Manazo GR, Green BA: Modified open door cervical expansive laminoplasty for spondylotic myelopathy: Operative technique, outcome, and predictors for gait improvement. *J Neurosurg* 86:64-68, 1997.
9. Nagata K, Ohashi T, Abe J, et al: Cervical myelopathy in elderly patients: Clinical results and MRI findings before and after decompression surgery. *Spinal cord* 34:220-226, 1996.
10. Nakano N, Nakano T: Clinical results following enlargement of the cervical spinal canal by means of laminoplasty. *Jpn Orthop Assoc* 62:1139-1147, 1988.
11. Sasai K, Satio T, Akagi S, et al: preventing C5 palsy after laminoplasty. *Spine* 28:1972-1977 2003.
12. Satomi K, Nishu Y, Kohno T, Hirabayashi K: Long-term follow-up studies of open-door expansive laminoplasty for cervical stenotic myelopathy. *Spine* 19(5):507-510, 1994.
13. Takayasu M, Takagi T, Nishizawa T, et al: Bilateral open-door cervical expansive laminoplasty with hydroxyapatite spacers and titanium screws. *J Neurosurg (spine 1)* 96:22_28, 2002.

11/5/2010